

An In Vivo Study of the Effect of Distal Femoral Resection on Passive Knee Extension

Conrad K. Smith, MS,* Justin A. Chen, BS,* Stephen M. Howell, MD,† and Maury L. Hull, PhD*†

Abstract: A previous study showed that 1 mm of distal femoral resection restored knee extension 4.5°. We determined the relationship with a more accurate measurement technique. Twenty-six subjects treated with total knee arthroplasty were studied. Digital photographs of the extended knee with and without 1.5 and 3.0 mm thick augments placed between the femoral component and distal femur were analyzed, and knee extension was measured. One millimeter of distal femoral resection restored 1.8° of extension that is less correction than the previous study reported. Because an attempt to correct a 10° extension deficit by resecting the distal femur could require 5 mm or more of bone removal that moves the joint line too proximal, we recommend exploring other techniques before resecting the femur. **Keywords:** arthroplasty, extension, knee, flexion contracture, custom-fit.

© 2010 Elsevier Inc. All rights reserved.

To obtain passive knee extension during total knee arthroplasty, an extension gap that is large enough for the combined thickness of the femoral and tibial components needs to be created [1]. In the operating room, the surgeon is often confronted with a flexion contracture when fitting the components and needs to have a rationale for deciding how much bone to remove from the distal femur and when to excise posterior osteophytes and release a tight posterior capsular contracture.

The effect of resecting too little distal femur on passive knee extension has been simulated in vivo by moving the femoral component distally by inserting femoral augments of varying thickness between the distal femoral cut and the back of the femoral trial component. The augments move the joint line distally losing passive extension; hence, the removal of the augment simulates a resection of the distal femur enabling the determination of the effect of moving the joint line proximal on passive extension. This in vivo study suggested that 2 mm of distal femoral resection restores 9° of extension [1], which is a larger correction than we have observed in our clinical experience.

One explanation for the difference between our clinical experience and the previous in vivo study might be the

inherent error in measuring the flexion angle of the knee with a handheld goniometer and “rounding the measurement to the nearest 5°” [1]. The accumulation of errors from positioning the limb, positioning the goniometer, and rounding the angle to the nearest 5° might result in a substantial measurement error causing an overestimation of the restoration of knee extension.

Accordingly, we developed a more accurate method for measuring the flexion angle of the knee, which relies on adhesive skin markers, digital photography of the leg, and the use of customized off-the-shelf image analysis software to compute the flexion angle. The present study determined the interobserver reliability (ie, bias) of measuring the flexion angle from the digital photograph and the repeatability of positioning the knee in passive extension. Because we found that the interobserver reliability and the repeatability of positioning the knee were high, we used this method to determine the relationship between distal resection of the femur (ie, distal translation of the femoral component) and passive knee extension.

Materials and Methods

All patients from July to October 2008 who had elected to proceed with a primary total knee arthroplasty for osteoarthritis were offered participation in this study. Twenty-six subjects with 27 knees were enrolled in the study and signed a consent form approved by an institutional review board.

The following techniques were used to place the skin markers to record knee angles and to perform the arthroplasty. After draping the leg, 3 rectangular skin markers (Scratch Pads, model no. E2401, Valley Lab,

From the *Biomedical Engineering Program, University of California, Davis, California; and †Department of Mechanical Engineering, University of California, Davis, California.

Submitted January 29, 2009; accepted May 24, 2009.

No benefits or funds were received in support of this study.

Reprint requests: Stephen M. Howell, MD, 8100 Timberlake Way, Suite F, Sacramento, CA 95823.

© 2010 Elsevier Inc. All rights reserved.

0883-5403/2507-0022\$36.00/0

doi:10.1016/j.arth.2009.05.030

Boulder, Colo) were applied to the lateral side of the leg on the proximal thigh, joint line, and distal tibia. To prevent movement of the skin markers, a sterile transparent, adhesive drape (Ioban2, model no. 6651EZ, 3M, St Paul, Minn) was wrapped around the leg encasing the markers to the skin (Fig. 1). Total knee arthroplasty, with preservation of the posterior cruciate ligament, was performed with use of a previously described custom-fit technique [2,3]. In this technique, any medial and or lateral tightness during passive flexion/extension or during varus/valgus laxity was treated by removal of medial or lateral osteophytes until the knee was balanced throughout the motion arc and the knee reached full passive extension with the trial components (Vanguard, Biomet, Inc, Warsaw, Ind) in place. There were no releases of the medial collateral ligament, lateral collateral ligament, or lateral retinacular ligaments [2,3].

After achieving full passive knee extension with the trial components in place, the following techniques were used to simulate the effect of resecting the femur too distally and to record the flexion angle of the knee. With the trial components in place, the heel was placed on a Mayo stand, the height was adjusted until the leg was parallel to the floor, and the leg was rotated until the foot was perpendicular to the floor. A digital camera (Model

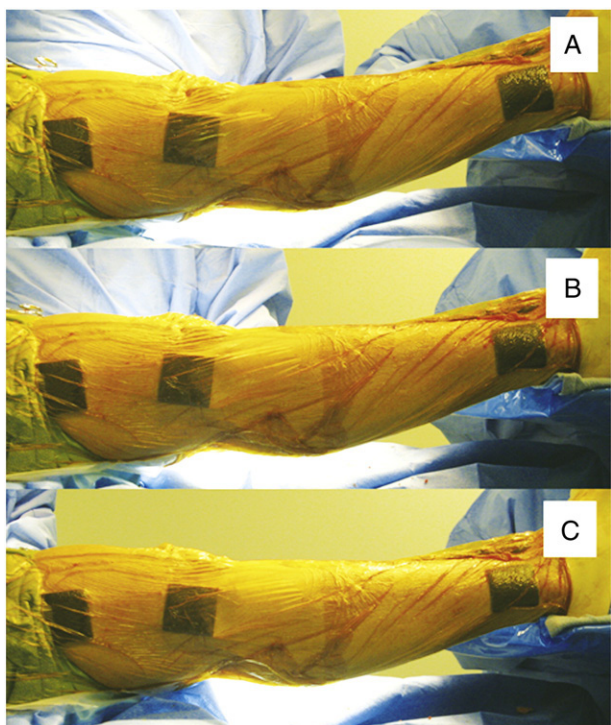


Fig. 1. Composite photograph showing the effect of incrementally moving the joint line distal on passive extension in a typical patient (A, no augment; B, 1.5 mm thick augment; and C, 3.0 mm thick augment). An encircling adhesive drape encased the 3 rectangular skin markers, which were digitally photographed and subsequently were used to calculate the flexion angle of the knee with use of image analysis software.




Fig. 2. Photograph of 1.5 and 3.0 mm thick custom-made aluminum femoral augments (A). The cylindrical protuberances were inserted into the lug holes on the distal cut of the femur (B and C).

A710 IS, Cannon, Lake Success, NY) mounted on a tripod, with a resolution of 7.1 pixels per millimeter, was adjusted in height until the camera was at the same height as the leg to minimize parallax error. The 3 skin markers were photographed, which recorded the flexion angle of the knee for subsequent measurement (Fig. 1).

The joint line was incrementally moved 1.5 and 3.0 mm distal with use of 2 distal femoral augments manufactured from aluminum (Fig. 2). The thickness of 1.5 mm was chosen because it corresponds to the thickness of the kerf of a 1.37 mm thick saw blade (0.054 inches), which is the smallest practical increment of bone resection that can be performed intraoperatively. The 3.0 mm thickness was chosen based on a pilot study because it was the thickest augment we could consistently insert. The 1.5 mm thick distal femoral augment was inserted into the lug holes in the distal femur and the trial femoral component was reinserted. The heel was returned to the original position on the Mayo stand, and the skin markers were photographed. The process was repeated with the 3.0 mm distal femoral augment. The order of inserting the augments was not randomized because of a concern that the tissues might be overstretched from testing the thicker augment before the thinner augment.

The flexion angle of the knee was measured from each digital photograph with use of the following computer-based technique. Each digital photograph was converted to grayscale and imported into image analysis software (Scion Image, Scion Corporation, Frederick, Md). An observer traced the outline of each rectangular skin marker and the image analysis software computed the x and y positions of the centroid (Fig. 3). The x and y positions of the centroid of each marker were imported into another software package (Matlab, version 6.0, The Mathworks Inc, Natick, Mass). Custom routines were

written in Matlab that calculated the angle formed by the 2 lines connecting the 3 centroids, which was the measurement of the flexion angle of the knee.

The interexaminer reliability of the measurement of the flexion angle was dependent on how reliable the examiner traced the outline of each skin marker. Therefore, 2 examiners independently traced the outline of the 3 skin markers in each test condition (ie, no augment and 1.5 and 3.0 mm augment) in each knee, and the Pearson's correlation coefficient was used to quantify the interexaminer reliability (ie, bias) of the measurement of the flexion angle from the digital photograph of the knee.

The repeatability of positioning the limb on the measurement of the flexion angle of the knee was determined in 3 randomly selected subjects with use of the following technique. First, the knee with the trial components without an augment was positioned in passive knee extension, and the 3 skin markers were photographed. Then the trial tibial component was removed and reinserted, the heel was repositioned on the Mayo stand, and the limb was photographed a second time. The procedure was repeated a third time. The SD of the pooled variance of the 3 measurements from the 3 subjects quantified the repeatability of positioning the limb in passive extension.

The passive extension of the knee without an augment was different between subjects, which meant we could not compare the effect of distal femoral resection of restoration of passive knee extension between subjects without referencing each flexion

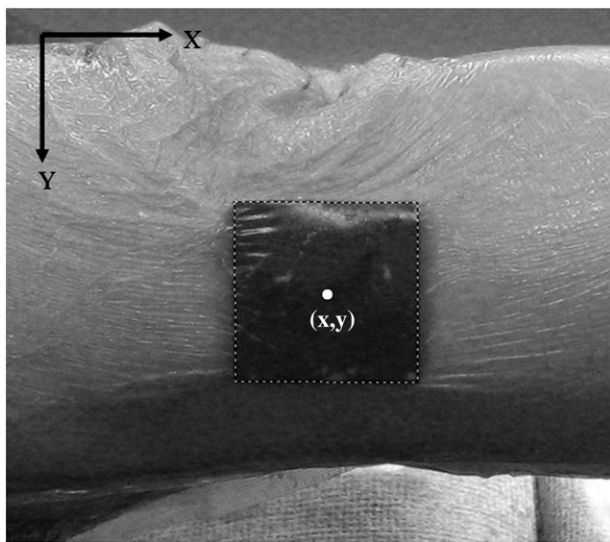


Fig. 3. Photograph showing the grayscale digital image of the tracing of the outline of the rectangular skin marker by an examiner. Software computed the x and y positions of the centroid of the rectangle. Another software program computed the flexion angle of the knee, which was the angle formed by the 2 lines connecting the centroids of the 3 skin markers.

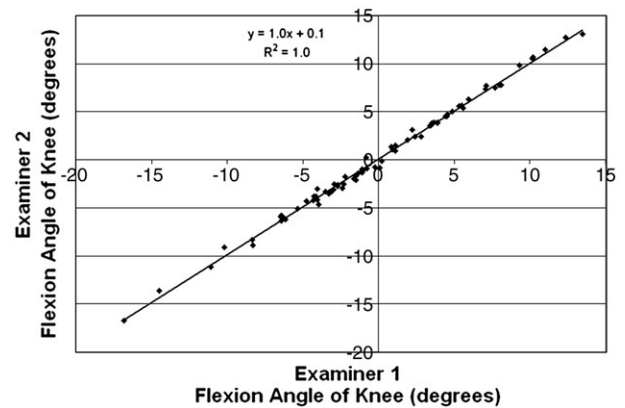


Fig. 4. Scatter plot showing the interexaminer reliability of the measurement of the flexion angle made by 2 examiners. The bias of the measurement of the flexion angle was negligible as demonstrated with an $R^2 = 1.0$.

angle measurement to a standard. We created a standard by referencing all 3 flexion angle measurements (ie, no augment and 1.5 and 3.0 mm augment) for each subject by assigning "0° of extension" to the flexion angle of the knee without an augment. Descriptive statistics (ie, mean and SD) were computed for the flexion angle of the knee with and without the augments. To determine the strength of the relationship between the amount of distal femoral resection and the restoration of passive knee extension, a simple linear regression was computed. The 95% prediction interval was computed as this interval will include 95% of any future use of the relationship.

Results

Two subjects were excluded from the study during the surgical procedure because the knee was too tight with the 3.0 mm distal femoral augment to permit the insertion of the trial tibial component. Therefore, the study comprised 25 knees in 24 subjects—13 women and 11 men (average, 68 years; range, 35-86 years; average body mass index, 28.6). Preoperatively, the average Knee Society score was 40 ± 14 (range, 4-60; 100 is best), the function score was 48 ± 16 (range, 0-80; 100 is best), and the Oxford score was 20 ± 9 (range, 0-32; 48 is best). The average flexion contracture was $6^\circ \pm 7^\circ$ (range, 0° - 25°), the flexion was $116^\circ \pm 13^\circ$ (range, 90° - 140°), and the angular alignment was $2^\circ \pm 8^\circ$ valgus (range, 10° varus to 15° valgus).

The interexaminer repeatability was 1.0 (Fig. 4). The repeatability of positioning the limb was 0.6°.

The 1.5 mm distal femoral augment caused an average loss of extension of $3.0^\circ \pm 1.4^\circ$. The 3.0 mm distal femoral augment caused an average loss of extension of $5.1^\circ \pm 1.8^\circ$. The relationship between the thickness of the distal femoral augment and passive knee extension was linear ($r^2 = 0.71$; $P < .0001$), with 1 mm of distal femoral resection restoring 1.8° of extension (Fig. 5).

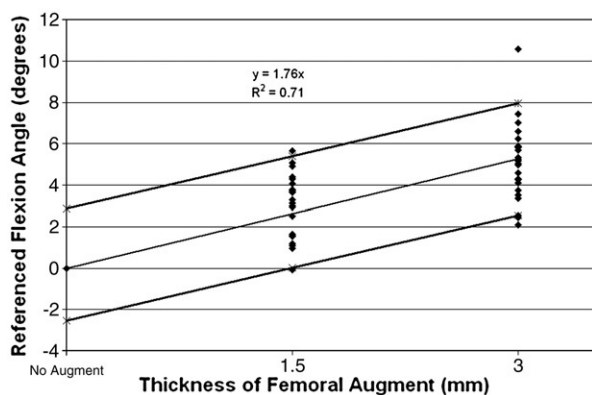


Fig. 5. Scatter plot showing the linear relationship between thickness of the distal femoral augment and the referenced flexion angle of the knee. The relationship is 1.8° of extension regained per millimeter of distal femur resected ($R^2 = 0.71$). The 95% prediction interval had a wide range from 0.0° to 5.4° for the 1.5 mm augment and 2.5° to 8.0° for the 3.0 mm augment. The cause of this variability is presumably variability in the stiffness or inherent laxity in the knee. For each subject, the flexion angle measurements for the 3 test conditions (ie, no augment and 1.5 and 3.0 mm augment) were referenced to the flexion angle of the knee without an augment, which was assigned 0° of extension.

Discussion

The present study determined the accuracy of a new method for measuring the flexion angle of the knee and then used this measurement method to determine the relationship between distal resection of the femur and passive knee extension. The method for measuring knee flexion was highly reliable because there was no interobserver variability in the software computation of the flexion angle from the digital photograph of the skin

markers, and only a small 0.6° error from repositioning the limb. These 2 criteria justify the use of this method for measuring the flexion angle of the knee in the present study. Accordingly, we observed that removal of 1 mm of bone restores an average of 1.8° of extension. This restoration of extension is 2 1/2 times less than the results from another study [1].

One reason that the restoration of extension was less than the other study might be due to differences in the reliability of the measurement technique. The 0.6° measurement error from repositioning the limb in the present study was less than the error from measuring knee flexion with a handheld goniometer that was used in the other study [1]. The accumulation of errors from positioning the limb, positioning the goniometer, and rounding the angle to the nearest 5° might result in a substantial measurement error causing an overestimation of the restoration of knee extension. The 5° error associated with the use of a handheld goniometer has been previously described [4-6]. Therefore, the detection of a smaller restoration of passive knee extension from removing bone from the distal femur in the present study is a justifiable finding because of the use of a highly accurate method for measuring the flexion angle of the knee.

A second reason the results may differ is that the surgical technique used to prepare the knee for the trial components was different between the 2 studies. In the previous study, conventional instruments were used, which often requires the release of collateral ligaments to restore motion to the knee. In the present study, the custom-fit technique was used, which might have resulted in a "tighter" knee because collateral ligaments are not released to regain motion or "balance the knee"

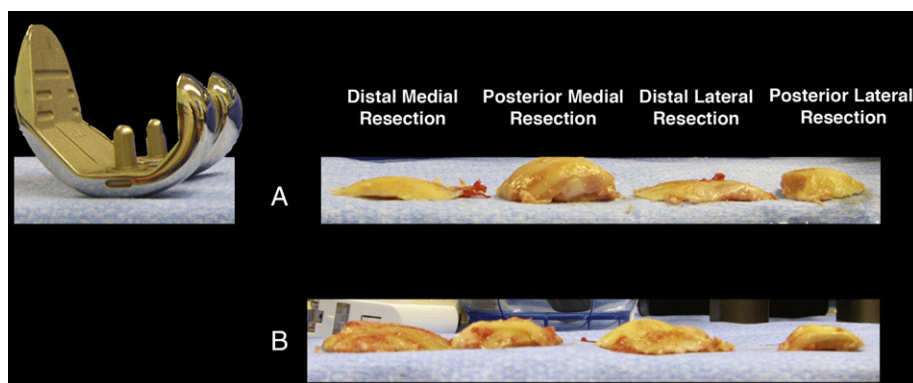


Fig. 6. Photograph comparing the thickness of the femoral component to the thickness of the distal medial, posterior medial, distal lateral, and posterior lateral resected segments of bone in 2 different subjects. Case A shows that the thickness of the distal medial and lateral resection segments are thinner than the femoral component even after adjusting for both the arthritic cartilage and bone wear and the bone loss from the kerf of the saw cut. This mismatch between the adjusted thickness of the distal resection and the femoral component indicates that removal of additional bone from the distal femur may be necessary to restore extension if removal of posterior osteophytes, stripping the posterior capsule off the femur, and manually manipulating the knee in extension are ineffective. Case B shows that the thickness of the 4 resected segments and femoral component are similar. The best method for managing a flexion contracture in this situation is to remove posterior osteophytes, strip the posterior capsule, manually manipulate the knee in extension, and avoid resecting bone from the distal femur.

[3]. Although we are unable to state at this time whether the surgical technique was the cause of this difference, it could have been a contributing factor.

One factor that probably was not the cause for the difference in the relationship between the amount of bone resection and restoration of passive knee extension was the type of component. Although the components in the 2 studies were made by different manufacturers, both retained the posterior cruciate ligament and, as a general principle, geometrically matched the articulating surface of the femur.

The maximum thickness of the distal femoral augment of 3.0 mm that was used in the present study was substantially thinner than the maximum thickness of the distal femoral augment of 8.0 mm in the study by Bengs et al [1]. In the present study, 2 subjects were excluded intraoperatively because the knees were too tight to insert the tibial component with the 3.0 mm distal femoral component, and we are reasonably confident that few of the remaining knees would have accommodated a distal femoral augment thicker than 3.0 mm. The cause of the difference in the thickness of the distal femoral augment accommodated by the knees in these 2 studies is unknown but might be related to the different treatment of the collateral ligaments between the 2 surgical techniques rather than differences in the geometry of the components.

The finding in the present study has clinical implications for the surgeon confronted with an intraoperative flexion contracture when conducting trials with the components during total knee arthroplasty. A reasonable first step is to inspect and then adjust the thickness of the distal and posterior resections of bone by adding to each resection the thickness of cartilage and bone lost from arthritic wear and the 1.5 mm thickness of bone lost from the kerf from using the saw (Fig. 6). If the adjusted thickness of the distal and posterior resections match each other and if they also match the thickness of the femoral component (ie, within 1-2 mm), then removing posterior osteophytes, stripping the posterior capsule from the femur with a curved osteotome, and manually manipulating the knee into extension should restore full passive extension in most knees. However, if after these steps a flexion contracture persists, especially if the adjusted thickness of the distal medial and lateral resections is thinner than the femoral component, then removal of 2.0 mm of bone from the distal femur should result in a 2° to 5° correction, with the resulting amount of correction depending on the stiffness of the knee. The resection of an additional 2.0 mm of bone can be repeated if a flexion contracture still persists but should only be performed after confirming that all the posterior osteophytes are removed, the posterior capsule is released, and the knee has been manually manipulated in extension because of the risk of moving the joint line too proximal and compromising flexion.

The determination of the zero point of knee extension at the time of total knee arthroplasty is inherently unreliable because the surgeon makes this decision subjectively. In the case where the contralateral knee is abnormal, full extension can be defined when the arthroplasty knee does not flex or “buckle” during longitudinal compression of the tibia into the femur. In the case where the contralateral knee is normal, full extension can be defined when the extension in the arthroplasty knee matches the contralateral knee, which may result in physiologic hyperextension. Because of the difficulty in determining the zero point of knee extension at the time of total knee arthroplasty, we are unable to determine whether the variability of the zero point of knee extension in the present study affected the loss of flexion from distal femoral augmentation.

Although some surgeons favor a few degrees of residual flexion because of the risk of hyperextension instability, hyperextension instability is unlikely with the custom-fit technique used in the present study because the components are positioned 3-dimensionally with the intent of restoring the 3 kinematic axes of the knee [7,8]. In the custom-fit technique, stability is maintained throughout the entire arc of motion because the axis in the femoral component about which the tibia flexes and extends is coaligned with the same axis in the femur, thereby, avoiding the release and maintaining the correct length of the collateral ligaments [8]. Coaligining these 2 axes is the fundamental step for aligning the axis in the femur about which the patella flexes and extends and the longitudinal axis in the tibia about which the tibia internally and externally rotates on the femur. Hyperextension instability has yet to be observed when the custom-fit technique is used with a cruciate-retaining component [2,9,10]. However, hyperextension might not be desirable in a cruciate-substituting knee, not because of instability but because of wear from the post impinging on the femoral component when the knee hyperextends.

In conclusion, using the more accurate method for measuring knee extension, we determined that 1 mm of distal bone removal restores 1.8° of knee extension. Because the restoration of extension was much less than a previous study and because resection of an additional 5 mm of bone could move the joint line too proximal, we recommend first removing posterior osteophytes, stripping the posterior capsule from the femur, and manually manipulating the knee into extension before resecting the femur.

Acknowledgments

The authors thank the operating room staff at Methodist Hospital for their participation.

References

1. Bengs BC, Scott RD. The effect of distal femoral resection on passive knee extension in posterior cruciate ligament-

- retaining total knee arthroplasty. *J Arthroplasty* 2006;21:161.
2. Howell SM, Kuznik K, Hull ML, et al. Results of an initial experience with custom-fit positioning total knee arthroplasty in a series of 48 patients. *Orthopedics* 2008;31:857.
 3. Spencer BA, Mont MA, McGrath MS, et al. Initial experience with custom-fit total knee replacement: intraoperative events and long-leg coronal alignment. *Int Orthop* 2008;33:1571.
 4. Jagodzinski M, Kleemann V, Angele P, et al. Experimental and clinical assessment of the accuracy of knee extension measurement techniques. *Knee Surg Sports Traumatol Arthrosc* 2000;8:329.
 5. Boone DC, Azen SP, Lin CM, et al. Reliability of goniometric measurements. *Phys Ther* 1978;58:1355.
 6. Lenssen AF, van Dam EM, Crijns YH, et al. Reproducibility of goniometric measurement of the knee in the in-hospital phase following total knee arthroplasty. *BMC Musculoskelet Disord* 2007;8:83.
 7. Coughlin KM, Incavo SJ, Churchill DL, et al. Tibial axis and patellar position relative to the femoral epicondylar axis during squatting. *J Arthroplasty* 2003;18:1048.
 8. Eckhoff DG, Bach JM, Spitzer VM, et al. Three-dimensional mechanics, kinematics, and morphology of the knee viewed in virtual reality. *J Bone Joint Surg Am* 2005;87(Suppl 2):71.
 9. Howell SM, Hodapp EE, Kuznick K, et al. In vivo adduction and reverse axial rotation (external) of the tibial component can be minimized during standing and kneeling. *Orthopedics* 2009 [in press].
 10. Spencer BA, Mont MA, McGrath MS, et al. Initial experience with custom-fit total knee replacement: intraoperative events and long-leg coronal alignment. *Int Orthop* 2008.