

# Kinematic Alignment in Total Knee Arthroplasty

## Definition, History, Principle, Surgical Technique, and Results of an Alignment Option for TKA



**Stephen M Howell, MD**<sup>1,2</sup>✉

**Joshua D Roth, BS**<sup>1</sup>

**Maury L Hull, PhD**<sup>1,2,3</sup>

<sup>1</sup> Biomedical Engineering Graduate Group, University of California, Davis  
Davis, California USA

<sup>2</sup> Department of Mechanical Engineering, University of California, Davis  
Davis, California USA

<sup>3</sup> Department of Biomedical Engineering, University of California, Davis  
Davis, California USA

✉ [sebhowell@mac.com](mailto:sebhowell@mac.com)

**How to cite this article:** Howell S M, Roth J D, Hull M L. Kinematic Alignment in Total Knee Arthroplasty. Definition, History, Principle, Surgical Technique, and Results of an Alignment Option for TKA. *Arthropaedia* 2014;1:44-53.

### Overview

This article describes the definition, history, and principle of kinematically-aligned total knee arthroplasty (TKA). The technique and intraoperative checks for kinematic alignment of the femoral and tibial components with generic instruments are presented. A simple step-wise algorithm for balancing the ligaments in kinematically-aligned TKA is shown. Finally, the results of four studies that evaluated patient satisfaction and function, alignment, risk of component failure, and contact kinematics after kinematically-aligned TKA are discussed. The goal of this introduction to kinematically-aligned TKA is to encourage surgeons to consider this alignment option when performing TKA.

## What is Kinematic Alignment in TKA?

An accepted principle in total knee arthroplasty (TKA) is to restore normal kinematics [1-5]. The interaction between the ligaments, menisci, and articular surfaces of the femur, tibia, and patella

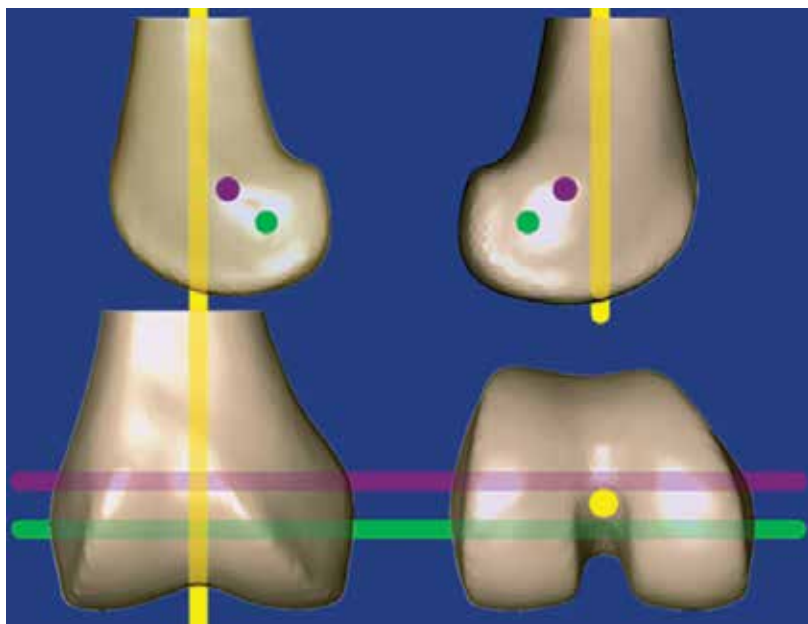


Figure 1. The illustration shows four views of the distal femur and the three kinematic axes of the knee. The green line indicates the transverse axis in the femur about which the tibia flexes and extends. The magenta line indicates the transverse axis in the femur about which the patella flexes and extends. The yellow line indicates the longitudinal axis in the tibia about which the tibia internally-externally rotates on the femur. Each axis is parallel or perpendicular to the natural joint line between the femur and tibia throughout the motion arc [3,7,8].

uneven load-sharing between compartments [1,2,6]. In contrast, in kinematically-aligned TKA the surgeon cuts the distal femur and proximal tibia to restore the natural angle and level of the joint lines thereby minimising these undesirable consequences

determine the kinematics of the normal knee and are described by three kinematic axes (Fig. 1) [1-3,6].

There are two alignment options in TKA. In mechanically-aligned TKA the surgeon cuts the distal femur and proximal tibia perpendicular to the femoral and tibial mechanical axes. These cuts change the angle and level of the natural joint line that Insall [9] wrote is a compromise (Fig. 2). A change in the natural angle and level of the joint line causes abnormal tightening or slackening of the collateral, retinacular, and posterior cruciate ligaments and abnormal kinematics. The undesirable consequences of abnormal kinematics are instability, motion loss, accelerated component wear, and component loosening from uneven load-sharing between compartments [1,2,6].

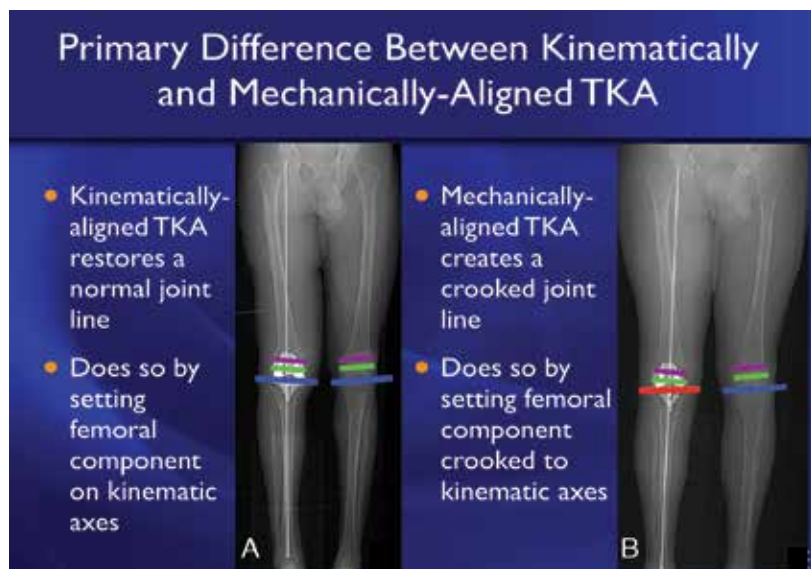


Figure 2. Illustration shows that kinematically-aligned TKA (A) restores the natural joint line (blue line) and aligns the components parallel to the kinematic axes (green and magenta lines), and that mechanically-aligned TKA (B) changes the natural joint line (red line) and aligns the components oblique to the kinematic axes. Both alignment options establish a neutral mechanical axis (white line).

## History of Kinematically-Aligned TKA

Kinematically-aligned TKA is predicted on the pioneering work of Hungerford, Kenna, and Krackow [4,5] who designed the porous-coated anatomic (PCA) total knee system with the specific objective of reconstituting normal knee kinematics through minimal articular surface replacement. They devised an instrumentation system that complemented the implant by allowing the ligaments to function under normal tension throughout the full range of motion, which

minimised stresses on fixation and motion interfaces. Their system was approved by the Food and Drug Administration (FDA) and available for use in 1984 [4,5].

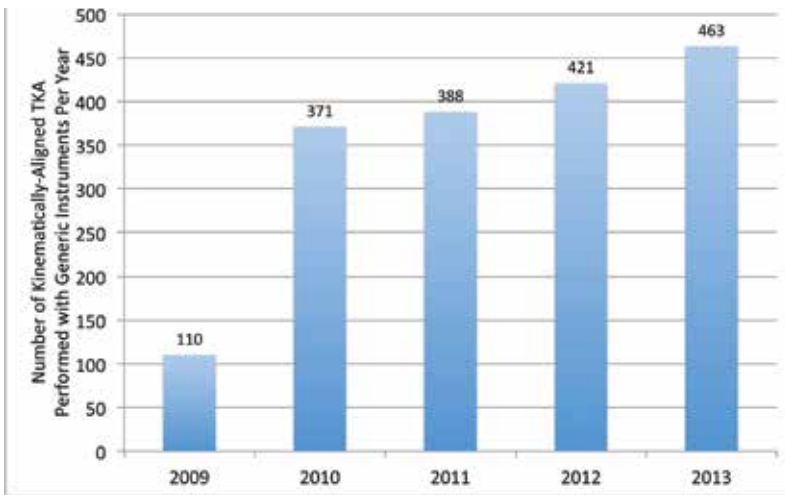


Figure 3. Column graph shows the steady growth in the number of kinematically-aligned TKAs performed each year with generic instruments, which is attributed to high patient-reported satisfaction and function.

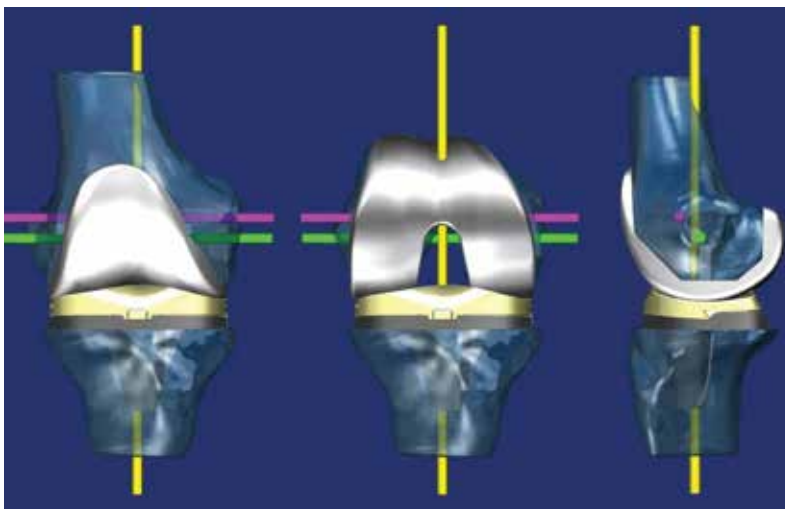


Figure 4. Illustration shows three views of the femoral and tibial components aligned parallel or perpendicular to the kinematic axes, which restores the natural joint lines. The use of kinematic alignment and removal of osteophytes minimises the release of the collateral, retinacular, and posterior cruciate ligaments to balance and align the TKA [6,11-13].

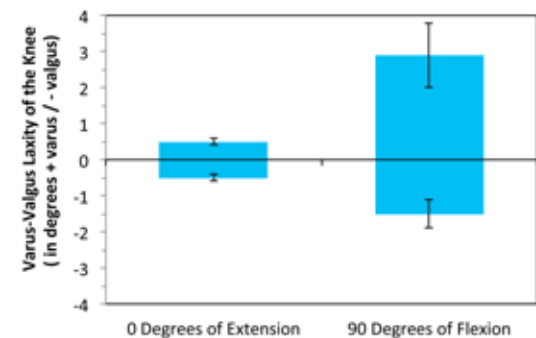


Figure 5. Column graph shows the symmetric and negligible varus-valgus laxity of  $\pm 0.5$  mm indicating a rectangular shaped gap at  $0^\circ$  of extension, and the asymmetric varus-valgus laxity of  $-1.5$  and  $+3.0$  mm indicating a trapezoidal gap at  $90^\circ$  of flexion (error bars  $\pm$  standard deviation) [14].

Kinematically-aligned TKA was first performed in January 2006 with patient-specific guides, and over 20,000 were performed in the United States between 2006 and 2009. In 2008, the potential for ‘malalignment’ with this system was reported by Klatt and Hozack based on navigated measurements of alignment in four patients without clinical follow-up [10]. In September 2009, the FDA did not approve the use of patient-specific guides to perform kinematically-aligned TKA. Since September 2009, we have performed 1753 kinematically-aligned TKAs with use of generic instruments similar in design and identical in function to the system designed by Hungerford et al (Fig. 3) [4,5].

### Principle of Kinematically-Aligned TKA is to Restore the Three Kinematic Axes of the Normal Knee

In kinematically-aligned TKA, the surgeon strives to position the femoral and tibial components to resurface the knee and restore the natural joint lines in the arthritic knee (Fig. 4).

The goal of kinematically-aligned TKA is to restore the natural difference in symmetry and varus-valgus laxity between  $0^\circ$  of extension and  $90^\circ$  of flexion of the normal knee (Fig. 5). Gap-balancing is an unnatural alignment option

because matching the varus-valgus laxity at  $90^\circ$  of flexion to the varus-valgus laxity at  $0^\circ$  of extension over-tightens the knee at  $90^\circ$  of flexion, which may cause stiffness, limit flexion, abnormal kinematics, and accelerate polyethylene wear.

### Technique for Kinematically-Aligning the Femoral and Tibial Components

The technique for kinematically aligning the femoral component is based on understanding the predictable patterns of cartilage wear and lack of bone wear in the osteoarthritic knee with varus or valgus deformity (Fig. 6) [15].

Intraoperative inspection of the distal femur

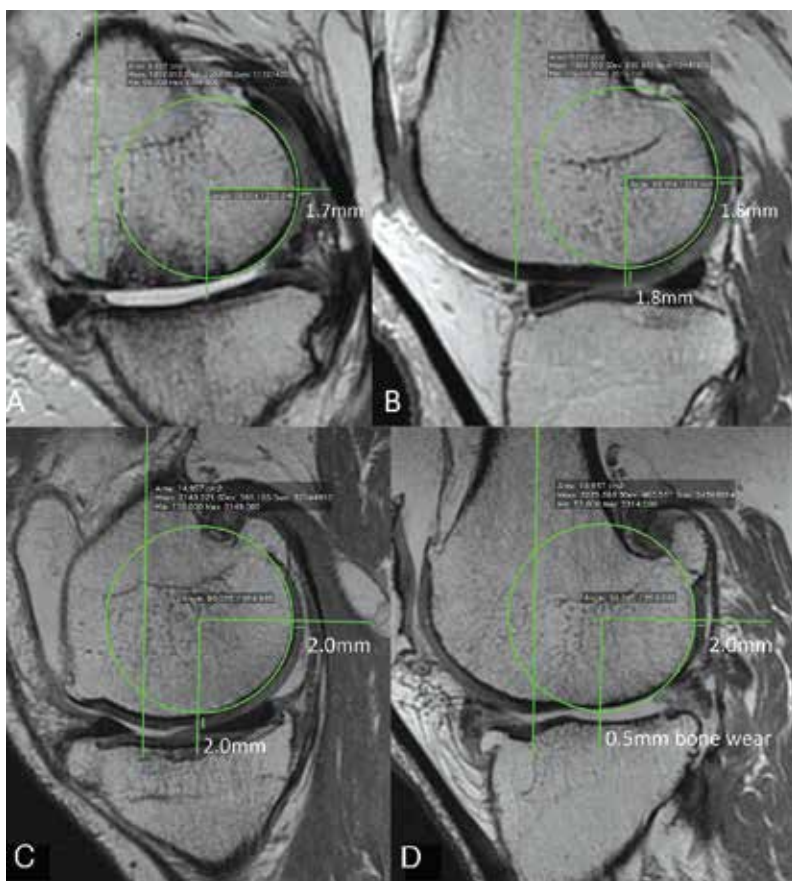


Figure 6. Magnetic resonance images show the typical medial hemijoint (A) and lateral hemijoint (B) in the varus osteoarthritic knee, and the typical medial hemijoint (C) and lateral hemijoint (D) of the valgus osteoarthritic knee. In the varus osteoarthritic knee, cartilage wear is confined to the distal medial condyle. In the valgus osteoarthritic knee, cartilage wear is confined to the distal lateral condyle. Cartilage wear to bone averages 1.9 mm [15].

determines the worn and unworn region of each condyle, which helps choose the distal intramedullary referencing guide that corrects the cartilage wear (Fig. 7).

Intraoperative inspection of the posterior femur is difficult with the tibia unresected (Fig. 8). Fortunately, the wear of the posterior cartilage is significantly less than the distal cartilage in the varus and valgus osteoarthritic knee [15].

The technique for kinematically-aligning the varus-valgus and posterior slope of the tibial component is performed with a generic extramedullary tibial guide (Fig. 9).

The technique for kinematically-aligning the internal-external rotation of the tibial component is the setting of the anteroposterior axis of the tibial trial component parallel to the major axis of the nearly elliptical boundary of the lateral tibial condyle (Fig. 10) [13,18].

### Intraoperative Check for Kinematic Alignment of the Femoral and Tibial Components

The intraoperative check for kinematic alignment of the femoral component is matching the thickness of the distal and posterior femoral resections to their respective regions on the condyle of the femoral component after correcting for cartilage wear and kerf (Fig. 11) [13].

There are two intraoperative checks for kinematic alignment of the tibial component. The first intraoperative check is restoration of the natural alignment of the limb and elimination of varus-valgus laxity with the knee in 0° of extension. In the knee with a severe fixed valgus deformity, the arcuate complex and popliteus tendon are released and a 2° varus recut cut guide is used to fine-tune the proximal tibia cut [13]. The two releases and the recut of the tibia move the ankle 12 to 14 mm medial thereby correcting the valgus deformity.

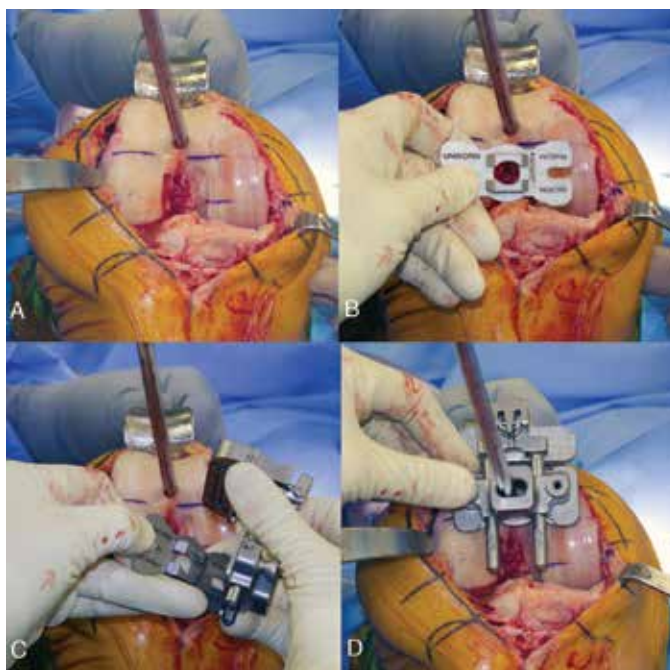


Figure 7. Photographs of a right varus osteoarthritic knee show the cartilage wear on the distal medial femoral condyle (A), and the use of the distal intramedullary referencing guide to set varus-valgus and flexion-extension rotation and proximal-distal translation of the femoral component (B to D). The distal referencing guide is chosen so the 'worn' side (which correct 2 mm of cartilage wear) contacts the worn distal condyle, and the 'unworn' side contacts the unworn distal femoral condyle.

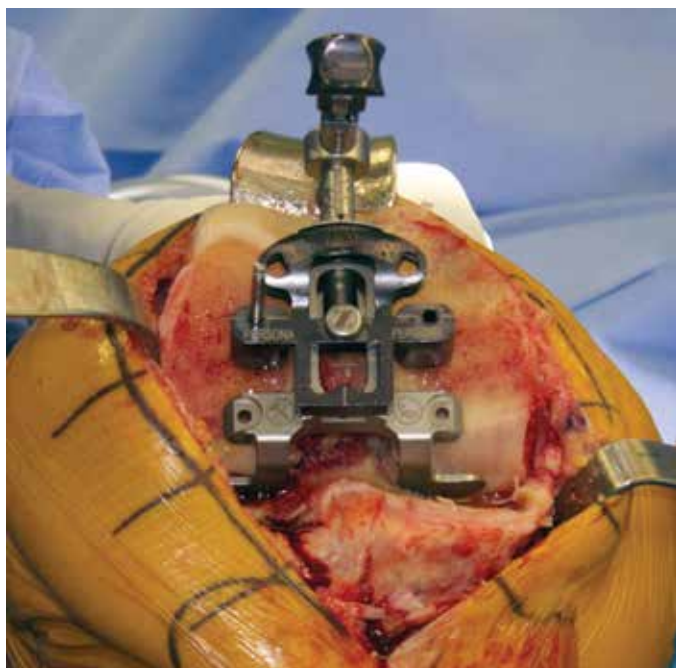


Figure 8. Photograph shows the use of the posterior referencing guide to set internal-external rotation and anterior-posterior translation of the femoral component. The neutral posterior referencing guide is chosen because the typical posterior cartilage wear in the varus and valgus osteoarthritic knee is <1 mm, which is clinically unimportant to correct.

The second intraoperative check is restoration of the offset of the anterior tibia on the distal medial femoral condyle after implantation of the trial components to that of the osteoarthritic knee at the time of exposure (Fig. 12). Increasing or decreasing the anterior-posterior slope of the tibial cut in 1° increments decreases or increases the offset in 1-2 mm increments, respectively [16,17].

### Simple Algorithm for Balancing the Kinetically-Aligned TKA

The kinetically-aligned TKA is balanced by following steps of a simple algorithm (Fig. 13).

### Results of Four Published Studies Evaluating Kinetically-Aligned TKA

Patient satisfaction, function, flexion and coronal alignment following kinetically-aligned TKA were compared to mechanically-

aligned TKA in a Level 1, double blind, prospective randomised controlled trial by Dossett et al [11]. Kinetically-aligned TKA was performed with use of patient-specific guides and mechanically-aligned TKA with conventional instruments. Kinetically-aligned TKA provided significantly better patient satisfaction, function, flexion, and set the joint line more anatomically than mechanically-aligned TKA. Both techniques had similar limb and knee alignments [11].

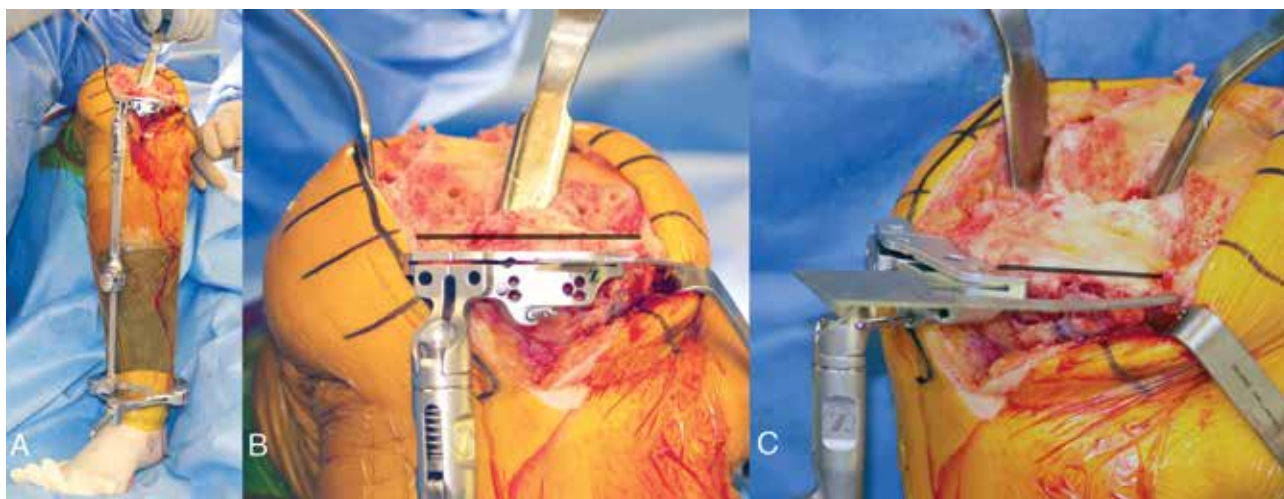


Figure 9. Photographs of a right knee show the extramedullary tibial guide adjusted in anatomic varus (A). The cut plane of the proximal tibia is adjusted to 1) reproduce the normal varus-valgus slope of the tibial articular surface (black line) after correcting for wear (B), 2) slightly reduce the normal posterior slope (black line) (C), and 3) remove a conservative thickness of bone to accept the thinnest tibial liner. Slightly reducing the normal posterior slope and removing a conservative thickness of bone help preserve the insertion of the PCL.

An analysis of 101 consecutive patients determined (1) the frequency that kinetically-aligned TKA, performed with use of generic instruments by Howell et al [13], set the coronal alignment of the limb, joint line, knee, and tibial component and the axial alignment of the tibial component in-range or an outlier, and (2) whether patients with an alignment categorised as an outlier had worse function than patients with an alignment categorised as in-range at 6 months postoperatively (13). High patient satisfaction and function, indicated by an average Oxford Knee Score of 42 (48 best), were restored regardless of whether a patient had an alignment categorised

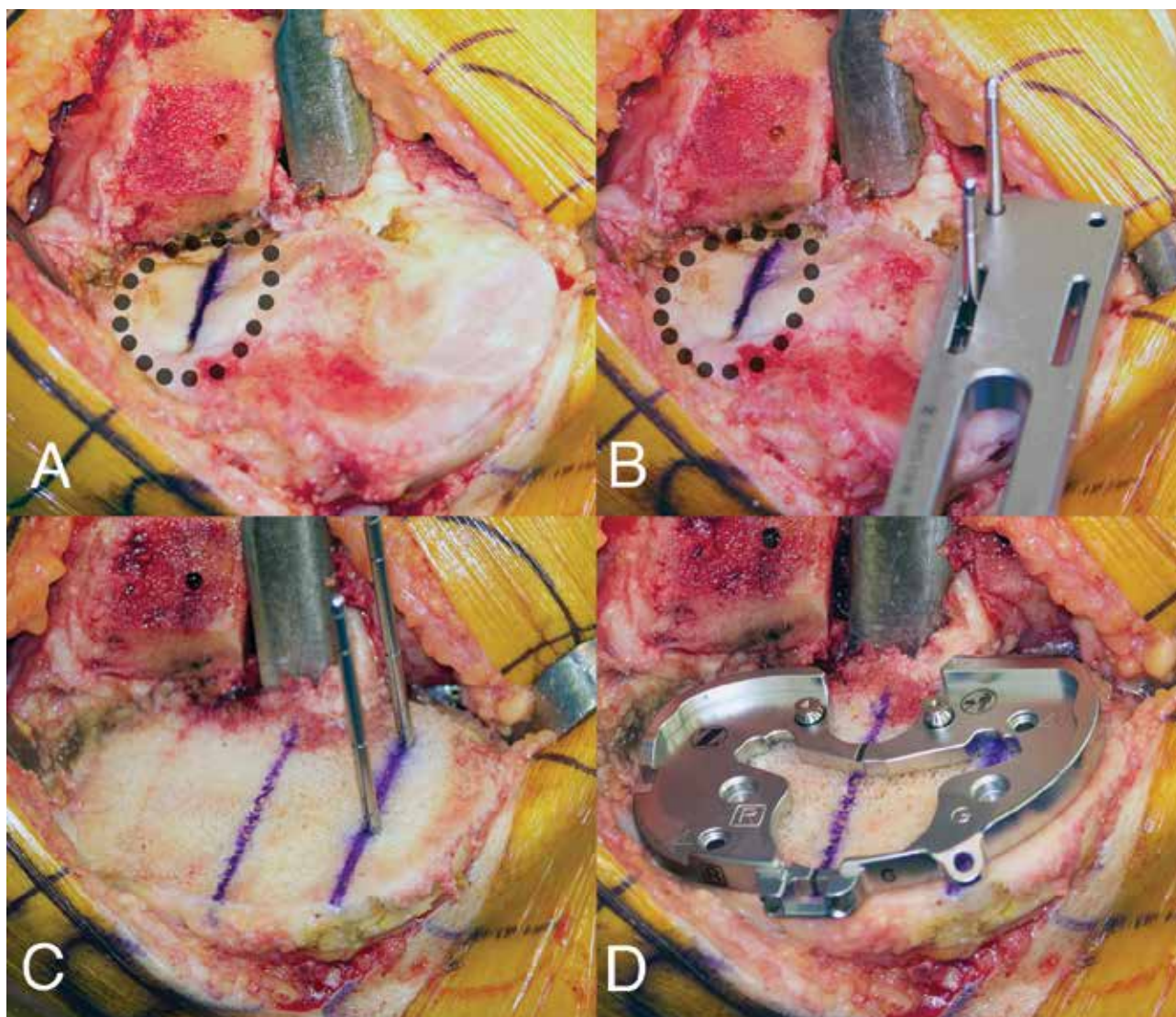


Figure 10. Photographs of a right knee show the steps for aligning the rotation of the tibial component on the tibia. A series of black dots outline the boundary of the nearly elliptical-shaped lateral tibial condyle and a line (blue) is drawn on the major axis of the ellipse (A). Two pins are drilled through the articular surface of the medial tibial condyle parallel to the major axis with a guide (B). On the cut surface of the tibial plateau, two lines are drawn parallel to the two drill holes into which pins have been placed to clarify their location (C). The anteroposterior axis of the trial tibial component is aligned parallel to these lines (D).

as in-range or an outlier. The authors concluded that they prefer the use of generic instruments to perform kinematically aligned TKA because five of six alignments were accurate and because high function was restored regardless of whether a patient had an alignment categorised as an outlier or in-range [13].

Kinematically-aligned TKA restores the natural pre-arthritis joint lines of the knee, which means the tibial component is aligned in natural varus. Restoring natural varus creates concern that the tibial component might result in early catastrophic failure and poor function [10]. An analysis of 198 patients (214 knees) treated with kinematically-aligned TKA performed with use of patient-specific guides by Howell et al [12] determined at 3 years whether the incidence of catastrophic failure and function were different when the tibial component, alignment of the knee, and alignment of the limb are categorised as in-range or an outlier. Kinematically-aligned TKA caused no catastrophic failure and restored high patient satisfaction and function as indicated by an average Oxford Knee Score of 43 regardless of whether an alignment was categorized in-range or an outlier. Because 75% of patients had their tibial component categorised as a varus outlier, and because these patients had a zero incidence of catastrophic failure and high function, the concern that kinematically-aligned TKA places the components at a high risk for catastrophic failure and

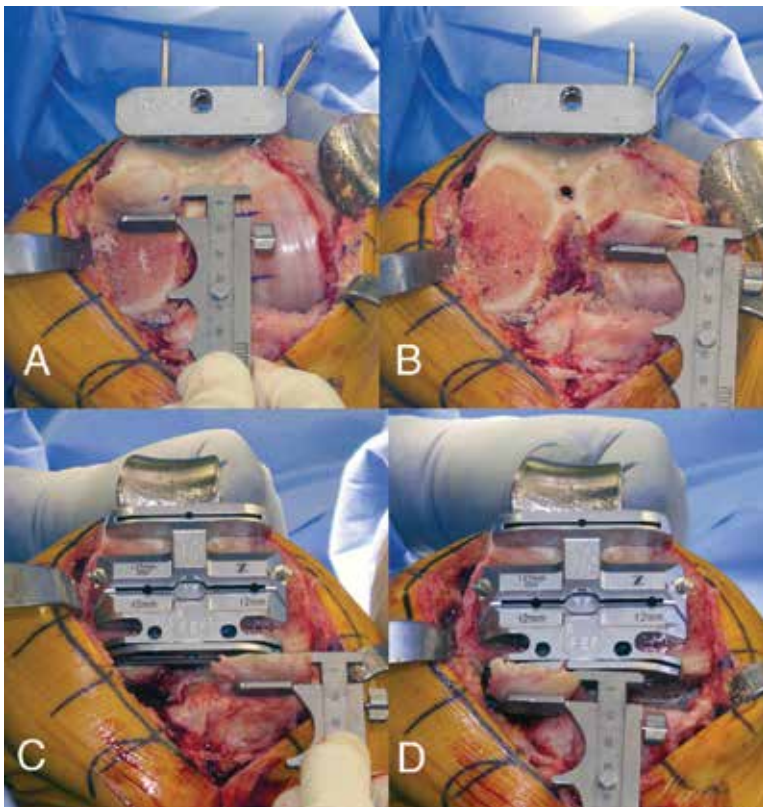


Figure 11. Photographs of a right knee show the caliper measurement of the distal lateral (A), distal medial (B), posterior medial (C), and posterior lateral (D) femoral resections. The femoral component is kinematically-aligned when the thickness of each resection is within  $\pm 0.5$  mm of the corresponding distal and posterior region of the condyle of the femoral component after correcting for cartilage wear and kerf [13].

compromises function is unfounded [12]. These two observations should be of interest to surgeons committed to cutting the tibia perpendicular to the mechanical axis of the tibia.

Tibiofemoral contact kinematics have a direct influence on patient function and long-term implant survival [19]. Three undesirable patterns of contact kinematics include, (1) edge loading of the tibial liner [20], (2) external rotation of the tibial component on the femoral component with knee flexion [21], and (3) adduction of the tibial component on the femoral component [22]. An analysis of 66 patients treated by three surgeons with kinematically-aligned TKA performed with use of patient-specific guides by Howell et al [6] determined whether the overall prevalence of undesirable contact kinematics during standing, mid-kneeling near 90° of flexion, and full kneeling with kinematically aligned TKA are minimal and not different between groups of patients treated

by different surgeons [6]. The kinematically-aligned TKA minimised the undesirable contact kinematics of edge loading of the tibial liner and external rotation and adduction of the tibial component on the femoral component during standing and kneeling, which suggests an optimistic prognosis for durable long-term function [6].

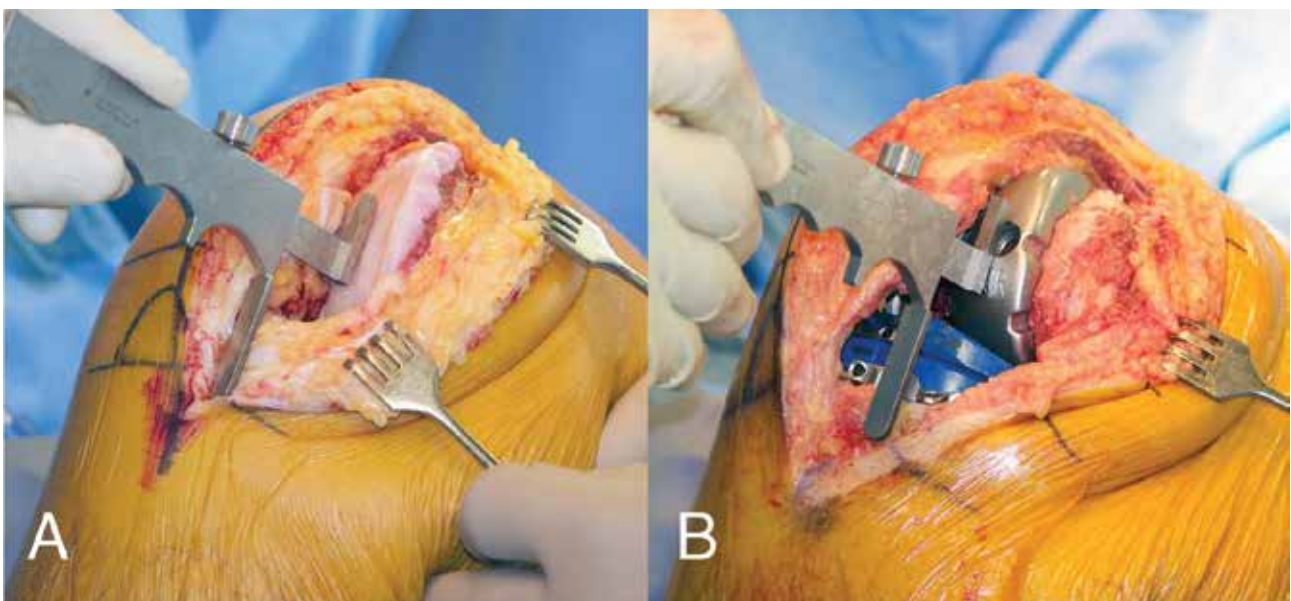


Figure 12. Photographs of a right knee show the caliper measurement of the offset of the anterior tibia on the distal medial femoral condyle of the osteoarthritic (A) and reconstructed knee with trial components (B) in 90° of flexion. Cartilage wear on the distal medial femoral condyle is subtracted from the measurement determines the normal offset. A recut guide fine-tunes the tibial slope until the offset of the reconstructed knee matches the osteoarthritic knee at the time of surgical exposure.

Balancing the Kinematically Aligned TKA has a Defined Pathway and Endpoint					
Tight in Extension & Flexion	Tight in Extension Stable in Flexion	Tight in Flexion Stable in Extension	If in Extension, Tight Medial & Loose Lateral	If in Extension, Tight Lateral & Loose Medial	Fixed Valgus
Remove more tibia	Remove posterior osteophytes Strip posterior capsule Decrease posterior tibial slope	Increase posterior tibial slope until tibial offset from femur is restored to normal at 90° flexion	Remove medial osteophytes Recut tibia in 2° more varus Thicker liner	Remove lateral osteophytes Recut tibia in 2° more valgus Thicker liner	Release arcuate complex and popliteus tendon Recut tibia in 2° more varus

Figure 13. The top row of the algorithm lists six imbalances, and the steps to correct them. The bottom row defines the steps for each imbalance, which includes removal of osteophytes, release of the posterior capsule, release of the arcuate complex and popliteus tendon in the knee with a fixed valgus deformity, and adjustment of the plane of the tibial cut. Rarely is a release of the collateral ligaments, retinacular ligaments, or posterior cruciate ligament required.

### Limitations

We have been unable to determine whether there is a varus or valgus deformity that should not be corrected with kinematic alignment. We have successfully treated around 2800 consecutive patients with kinematic alignment from 2006 to 2014 with no exclusions. However, it must be shared that the range and severity of deformity of our large population of patients treated in California within the United States may differ from those treated in other parts of the world. We suggest the interested surgeon initially limit kinematic alignment to patients with mild and moderate deformities. With the confidence gained from experience the surgeon can then decide whether to treat more severely deformed limbs. Kinematic alignment has not been extensively performed world-wide, which suggests there may be varus or valgus deformities that kinematic alignment cannot correct.

### Summary

When performing kinematically-aligned TKA with generic instruments, the surgeon strives to align the femoral and tibial components parallel or perpendicular to the kinematic axes, which restores the natural joint lines. Restoring the natural joint lines aligns the limb and stabilises the knee without releasing the collateral ligaments, retinacular ligaments, and posterior cruciate ligament. Kinematically-aligned TKA results in better patient satisfaction and function (Oxford Knee Score), and better flexion than mechanically-aligned TKA, because mechanically-aligned TKA changes the angle and level of the joint line from normal. At 3 years, kinematically-



aligned TKA caused no catastrophic failure and restored high function regardless of whether the tibial component was categorised as a varus outlier or in-range [12]. Kinematically-aligned TKA frequently sets the coronal alignment of the limb, joint line, knee, and tibial component, the rotational alignment of the tibial component, and the anterior-posterior offset of the femur relative to the tibia in-range, which makes kinematically-aligned TKA a worthy option for TKA. Finally, kinematically-aligned TKA minimised abnormal contact kinematics, which suggests the prognosis for long-term implant survival is optimistic.

## References

1. Eckhoff DG, Bach JM, Spitzer VM, Reinig KD, Bagur MM, Baldini TH, Flannery NM. Three-dimensional mechanics, kinematics, and morphology of the knee viewed in virtual reality. *J Bone Joint Surg Am* 2005;87 Suppl 2:71-80.
2. Gu Y, Roth JD, Howell SM, Hull ML. How Frequently Do Four Methods for Mechanically-Aligning A Total Knee Arthroplasty Cause Collateral Ligament Imbalance and Change Alignment from Normal in Caucasians? *J Bone Joint Surg Am* . In Press 2014.
3. Hollister AM, Jatana S, Singh AK, Sullivan WW, Lupichuk AG. The Axes of Rotation of the Knee. *Clin Orthop Relat Res* 1993;290:259-68.
4. Hungerford DS, Krackow, Kenneth A., Kenna, Robert V. Instrumentation for Total Knee Arthroplasty. *Total Knee Arthroplasty: A Comprehensive Approach*. Baltimore: Williams & Wilkins; 1984:35-70.
5. Hungerford DS, Kenna RV, Krackow KA. The porous-coated anatomic total knee. *Orthop Clin North Am* 1982;13:103-22.
6. Howell SM, Hodapp EE, Vernace JV, Hull ML, Meade TD. Are undesirable contact kinematics minimized after kinematically aligned total knee arthroplasty? An intersurgeon analysis of consecutive patients. *Knee Surg Sports Traumatol Arthrosc* 2013;21:2281-87.
7. Eckhoff DG, Bach JM, Spitzer VM, Reinig KD, Bagur MM, Baldini TH, Rubinstein D, Humphries S. Three-Dimensional Morphology and Kinematics of the Distal Part of the Femur Viewed in Virtual Reality Part II. *J Bone Joint Surg Am* 2003;85(Suppl 4):97-104.
8. Iranpour F, Merican AM, Baena FR, Cobb JP, Amis AA. Patellofemoral joint kinematics: the circular path of the patella around the trochlear axis. *J Orthop Res* 2010;28:589-94.
9. Insall JN. Presidential address to the knee society: choices and compromises in total knee arthroplasty. *Clin Orthop Relat Res* 1988;226:43-48.
10. Klatt BA, Goyal N, Austin MS, Hozack WJ. Custom-fit total knee arthroplasty (OtisKnee) results in malalignment. *J Arthroplasty* 2008;23:26-29.
11. Dossett HG, Swartz GJ, Estrada NA, LeFevre GW, Kwasman BG. Kinematically versus mechanically aligned total knee arthroplasty. *Orthopedics* 2012;35:e160-169.
12. Howell SM, Howell SJ, Kuznik KT, Cohen J, Hull ML. Does A Kinematically Aligned Total Knee Arthroplasty Restore Function Without Failure Regardless of Alignment Category? *Clin Orthop Relat Res* 2012;471:1000-07.
13. Howell SM, Papadopoulos S, Kuznik KT, Hull ML. Accurate alignment and high function after kinematically aligned TKA performed with generic instruments. *Knee Surg Sports Traumatol Arthrosc* 2013;21:2271-80.
14. Roth JD, Hull ML, Howell SM. Varus-Valgus Laxity of the Normal Knee at 0° and 90° Flexion: Implications in Gap-Balancing TKA. Paper presented at: Annual Meeting of the Orthopaedic Research Society 2014; New Orleans, LA.
15. Nam D, Lin KM, Howell SM, Hull ML. Is the pattern of cartilage and bone wear predictable in the osteo-arthritic knee with a varus or valgus deformity? *Knee Surg Sports Traumatol Arthrosc*. In Press 2014.
16. Christen B, Heesterbeek P, Wymenga A, Wehrli U. Posterior cruciate ligament balancing in total knee replacement: the quantitative relationship between tightness of the flexion gap and tibial translation. *J Bone Joint Surg Br* 2007;89:1046-50.
17. de Jong RJ, Heesterbeek PJ, Wymenga AB. A new measurement technique for the tibiofemoral contact

- point in normal knees and knees with TKR. *Knee Surg Sports Traumatol Arthrosc* 2010;18:388-93.
18. Nedopil AJ, Howell SM, Rudert M, Roth J, Hull ML. How Frequent Is Rotational Mismatch Within  $0\pm 10$  in Kinematically Aligned Total Knee Arthroplasty? *Orthopedics* 2013;36:e1515-e1520.
  19. Wasielewski RC, Galante JO, Leighty RM, Natarajan RN, Rosenberg AG. Wear patterns on retrieved polyethylene tibial inserts and their relationship to technical considerations during total knee arthroplasty. *Clin Orthop Relat Res* 1994;299:31-43.
  20. Hamai S, Miura H, Higaki H, Matsuda S, Shimoto T, Sasaki K, Yoshizumi M, Okazaki K, Tsukamoto N, Iwamoto Y. Kinematic analysis of kneeling in cruciate-retaining and posterior-stabilized total knee arthroplasties. *J Orthop Res* 2008;26:435-42.
  21. Dennis D, Komistek R, Mahfouz M, Walker S, Tucker A. A multicenter analysis of axial femorotibial rotation after total knee arthroplasty. *Clin Orthop Relat Res* 2004;428:180-89.
  22. Wasielewski RC, Galat DD, Komistek RD. Correlation of compartment pressure data from an intraoperative sensing device with postoperative fluoroscopic kinematic results in TKA patients. *J Biomech* 2005;38:333-39.