

A rationale for predicting graft impingement by the anterior cruciate intercondylar roof

A magnetic resonance imaging study

STEPHEN M. HOWELL,*† MAJ, MC, USAFR, JAMES A. CLARK,‡ MD,
AND TIMOTHY E. FARLEY,* MAJ, MC, USAF

*From the *David Grant Medical Center, Travis Air Force Base, California, and ‡Enloe Hospital, Chico, California*

ABSTRACT

This study was designed to analyze how anterior tibial tunnel placement can result in graft impingement by the intercondylar roof. The relationship of the ACL to the intercondylar roof was studied using magnetic resonance scans. An attempt was made to predict the amount of bone that may need to be removed from the intercondylar roof to prevent impingement on a 10 mm thick ACL graft.

Magnetic resonance scans of 19 normal ACLs were analyzed. The amount of bone removal required to correct roof impingement was determined for a graft placed either eccentrically or centrally within the ACL insertion, and within the bulk of the normal ACL fibers. An eccentric tibial tunnel placement required approximately 5 to 6 mm and a central placement required 2 to 3 mm of bone removal from the intercondylar roof to prevent impingement. Placing the graft within the bulk of the ACL fibers, just 3 mm posterior to the center of the ACL insertion, required little bone resection to prevent impingement.

To prevent ACL graft impingement, roofplasties need to be performed in both acute and chronic ACL reconstructions if the presently accepted locations for positioning the tibial tunnel are used. A more anteriorly placed tibial tunnel requires more bone removal to prevent roof impingement than a more posteriorly positioned tibial tunnel.

The assessment and treatment of intercondylar notch impingement of an ACL graft is a complex problem. Bony

impingement can occur from encroachment of the graft by the lateral condyle when the notch is stenosed or when the tibial tunnel is positioned too far laterally? This form of impingement occurs in the coronal plane and results when the dimensions of the graft extend beyond the boundaries provided by the width of the notch.⁸ Bone can be removed from the medial wall of the lateral femoral condyle to correct this form of impingement. Bone removal from this location can be more specifically termed a "wallplasty," instead of using the generalized term "notchplasty."

Guidelines for performing a wallplasty have been established for the chronic ACL deficient knee.^{8,9,22} The indications for bone removal in the acutely injured knee have not yet been defined. Odensten and Gillquist^{8,9} recommend widening the aperture of the intercondylar notch in the coronal plane to at least 21 mm. Intraoperative visual inspection of the proximity of the graft to the lateral femoral condyle can also be used to determine when a lateral wallplasty is needed and whether it has been completely performed.⁸

Graft impingement can also be related to variations in the placement of the tibial tunnel in the sagittal plane.^{3,14,25} Impingement in the sagittal plane occurs when the intercondylar roof impacts on the ACL graft before the knee reaches terminal extension.²⁵ Anatomical and roentgenographic studies have confirmed that the normal ACL abuts the intercondylar roof with the knee in full extension.^{20,21,25} There is normally a broad, anterior flare to the ACL at its tibial insertion that extends anterior to the slope of the intercondylar roof.²⁰ A tubular graft centered anteriorly within this anterior flare of the ACL insertion can impact against the intercondylar roof before the knee reaches terminal extension.⁶ This form of impingement in the sagittal plane is "roof impingement" and is anatomically distinct from the impingement in the coronal

† Address correspondence and reprint requests to: Stephen M. Howell, MD, 7601 Timberlake Way, Suite 103, Sacramento, CA 95823.

plane produced by the medial wall of the lateral femoral condyle.¹⁴

The indications for performing a "roofplasty" in the acute and chronic ACL deficient knee have not been agreed upon.^{1,10,15,19} This may be due, in part to the lack of a consensus on the optimal location for placing the tibial tunnel. Clancy et al.⁵ state that an eccentric placement (5 mm anterior and medial to the center of the ACL insertion) is preferable. In contrast, Odensten and Gillquist⁹ recommend placing the tibial tunnel in the center of the ACL insertion. Further variation in tunnel placement occurs because precise placement of the tibial tunnel is difficult to achieve.⁹ The lack of a consensus on a recommended tibial tunnel location, and imprecision in tunnel placement, indicate that there is likely to be significant variation in tibial tunnel placement between surgeons and within successive reconstructions performed by the same surgeon. Placement variation of the tibial tunnel in the sagittal plane will produce different degrees of roof impingement.

Detection of roof impingement can be difficult as it occurs only when the knee approaches the last few degrees of terminal extension. The trochlea of the femur closes on the tibial plateau as the knee extends and obstructs the view of the relationship of the intercondylar roof to the graft.¹⁴

Knee surgeons continue to report complications of ACL reconstructions such as pain, limited knee extension, synovitis, graft abrasion, and late graft rupture, which can be attributed in some degree to graft impingement.^{6,18,24} Additional studies are needed to analyze the different factors that contribute to graft impingement.

This study was designed to determine how different sagittal positions of the tibial tunnel may affect the severity of intercondylar roof impingement. Magnetic resonance (MR) scanning was used to provide detailed, *in vivo* visualization of the ACL including its origin, its intraarticular relationship to the intercondylar notch, and the sagittal limits of its tibial insertion.^{2,4,7,16,17,23,26} The objectives of this study were to estimate the amount of bone removal from the intercondylar roof required to prevent roof impingement if a graft is placed either 1) eccentrically or 2) centrally within the ACL insertion. Thirdly, and of equal interest, was the tibial location where a graft could be positioned to replace the bulk of the ACL fibers and yet still be free from impingement without bone removal. These three objectives were studied by analyzing the anatomical relationship of the ACL and intercondylar roof using MR scans of the normal knee.

MATERIALS AND METHODS

Sagittal MR scans from 42 consecutive patients with an intact ACL determined by history and physical examination were retrospectively reviewed. Twenty-three patients were excluded because the dimensions of the normal ACL were not completely displayed on one MR image. (These patients had the ACL projected on two or more slices.) The remaining 19 patients, with either normal knees or stable knees with

isolated meniscal lesions, comprised the study group. The knees with meniscal lesions displayed no evidence of arthritic changes on AP, lateral, and notch radiographs. There were 15 males and 4 females; the average age was 33 ± 11 years (range, 16 to 48 years).

Imaging was performed using a Philips 1.5 Tesla superconducting magnet with a dedicated surface receiver coil. Images were obtained using contiguous 2.5 mm thick sagittal sections (0.625 mm² pixels) centered about the ACL. The fully extended knee was externally rotated 10° to 15° in an attempt to optimally align the ACL in the sagittal plane (although this maneuver resulted in a true sagittal alignment in only 19 of 42 patients). Extension placed the ACL against the intercondylar roof. Image acquisition was performed with the standard spin-echo technique using a repetition time (TR) of 1200 msec and an echo time (TE) of 40 msec. Encoding and reconstruction was performed with the standard two-dimensional Fourier transformation technique, using 256 phase encoding steps and two excitations (10 minutes acquisition time).

The sagittal image that best displayed the normal ACL was magnified to 140% of actual size (magnification factor of 1.4). Measurements were performed on the single image that depicted the complete sagittal dimensions of the ACL from origin to insertion. Measurements were made of the film rather than directly from the monitor in order to determine the reproducibility of obtaining these measurements in a setting easily accessible by an orthopaedic surgeon.

Anatomical relationships between the tibial plateau, the ACL, and the intercondylar roof were obtained by using the following measurement technique to analyze the MR scans (Fig. 1A). The midsagittal depth of the tibial plateau was measured by drawing a line perpendicular to the long axis of the tibia centered at the level of the anterior edge of the ACL insertion. A perpendicular line was placed along the anterior tibial cortex to define the anterior limit of the tibial plateau. Another perpendicular line was drawn posteriorly against the tibial cortex that overlies the tubercle near the PCL insertion. The sagittal depth of the tibia was measured between these limits and converted to actual size using the magnification factor.

The relationship of the ACL to the tibial plateau and the intercondylar roof was studied by selecting several landmarks (Fig. 1B). The anterior-most portion of the ACL insertion was marked at the joint line (A). A line was drawn along the anterior edge of the ACL paralleling the relatively straight proximal one half of the ligament. A second line, parallel to the anterior line, was drawn overlying the posterior edge of the ACL. The region between these two lines defined the course of the bulk of the ACL ligament fibers. The width of the bulk of the ACL was measured between these two lines at the midpoint between the origin and insertion of the ACL (W) and converted to actual size using the magnification factor (x1.4). The intersection of the posterior line with the joint line marked the posterior limit of the ACL insertion (P).

The relationships of the central and eccentric placements

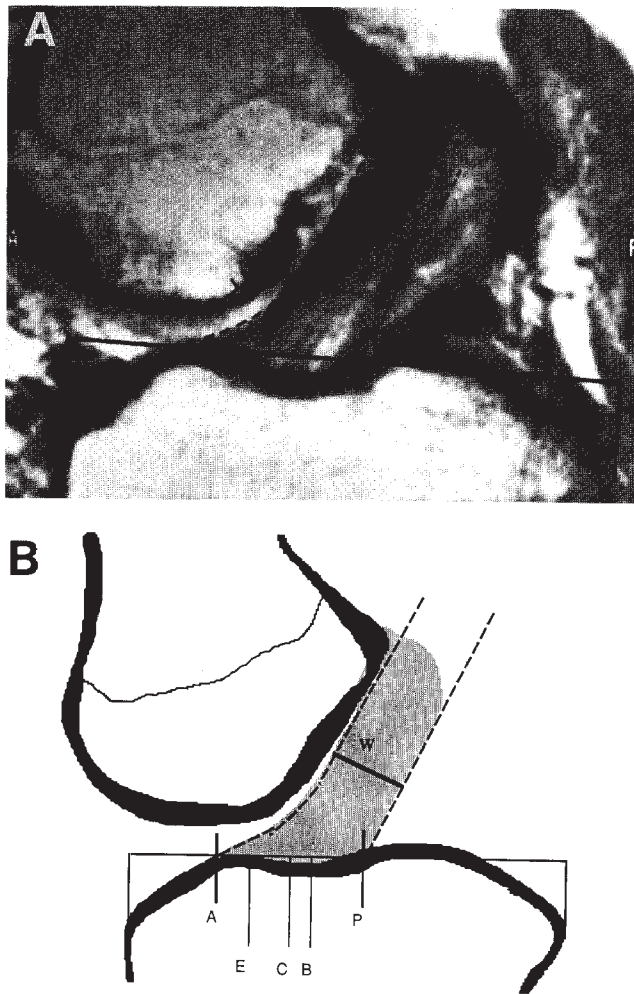


Figure 1. A, this sagittal MR scan of a normal knee depicts the entire sagittal dimensions of the ACL from origin to insertion. The insertion broadens anteriorly to nearly twice the width of the proximal two thirds of the ligament that contain the bulk of the ACL ligament fibers. In the extended knee, the ACL is oriented vertically to the articular surface of the tibial plateau. B, a line drawing of the MR scan provides the landmarks used for measuring the ACL: A, anterior limit of the ACL insertion; E, center of an eccentrically placed tibial tunnel; C, anatomical center of the insertion of the ACL; B, anatomical center of the bulk of the ACL; P, posterior limit of the ACL insertion; and W, width of the bulk of the ACL.

of the tibial tunnel were determined with respect to the sagittal depth of the tibia. The center of the ACL insertion (C) was marked at the joint line by bisecting the anterior and posterior limits of the ACL insertion. The eccentric location (E) was marked 7 mm anterior to the center of the ACL insertion (140% X 5 mm). The midpoint of the bulk of the ACL was marked at the joint line (B).

The distance from the anterior tibial cortex to the ACL insertion locations (A, P, C, E, and B) was measured along the joint line. To permit comparisons between different sized knees, each parameter was divided by the sagittal depth of the

tibia. The average depth of the ACL insertion was calculated from the mean sagittal depth of all of the tibial plateaus in the study. The angle formed by the center of the long axis of the bulk ACL and the joint line was measured for each knee.

The amount of intercondylar roof impingement was measured by using a clear template cut to represent a hypothetical 10 mm diameter graft. (The template was actually 14 mm wide to account for magnification.) The three impingement measurements were based on the center of the eccentric position (E), the center of the anatomical insertion of the ACL (C), and the center of the bulk of the ACL (B). The distal end of the template was centered over each of the three anatomical landmarks by rotating the template about its proximal edge, which was aligned over the normal ACL (Fig. 2). The maximum amount that the template extended anterior to the ACL was measured. This distance represented the thickness of bone that would need to be removed from the intercondylar roof to prevent impingement.

The parameters derived from the MR scans were independently determined by two of the authors (SMH and TEF). The interobserver variability for interpreting the MR scans was determined by comparing the 95% confidence interval of the three impingement measurements calculated by the two reviewers.

RESULTS

The ACL was oriented vertically with the knee in full extension. The intersection of the ACL with the tibial plateau averaged $63^\circ \pm 4.3^\circ$. The eccentric position was $29.3\% \pm 1.9\%$ (of the sagittal tibial depth) from the anterior tibial edge (Fig. 3). The center of the ACL insertion was $38\% \pm 2\%$ and the center for the bulk of the ACL was $43.7\% \pm 2.3\%$ from the anterior edge of the tibia.

The measurements of the anatomy of the ACL were normalized to the average midsagittal depth of the tibial plateau of 60 ± 4.3 mm. The anterior edge of the ACL inserted 13.8 mm from the anterior osteochondral junction, with the sagittal depth of the ACL insertion being 18.6 mm deep. The posterior edge of the ACL inserted directly anterior to the medial tibial eminence at a distance of 32.4 mm from the anterior tibial edge. The width of the proximal one half of the ACL averaged only 10 ± 0.2 mm, confirming that the anterior flare of the ACL widens the insertion to almost twice the width of the bulk of the ACL fibers. The flare of the ACL insertion was observed to lie against and adapt to the contour of the intercondylar roof with the knee extended (Fig. 1A),

The sagittal location of the eccentric placement for the tibial tunnel was 5 mm anterior to the center of the ACL, and 8.5 mm anterior to the center of the bulk of the ACL. The Student's t-test was used to compare the amount of intercondylar roof impingement for the eccentric location to the central tunnel placement ($t = 12.53$, $df = 36$, $P < 0.001$), the eccentric position to the bulk location for the tibial tunnel

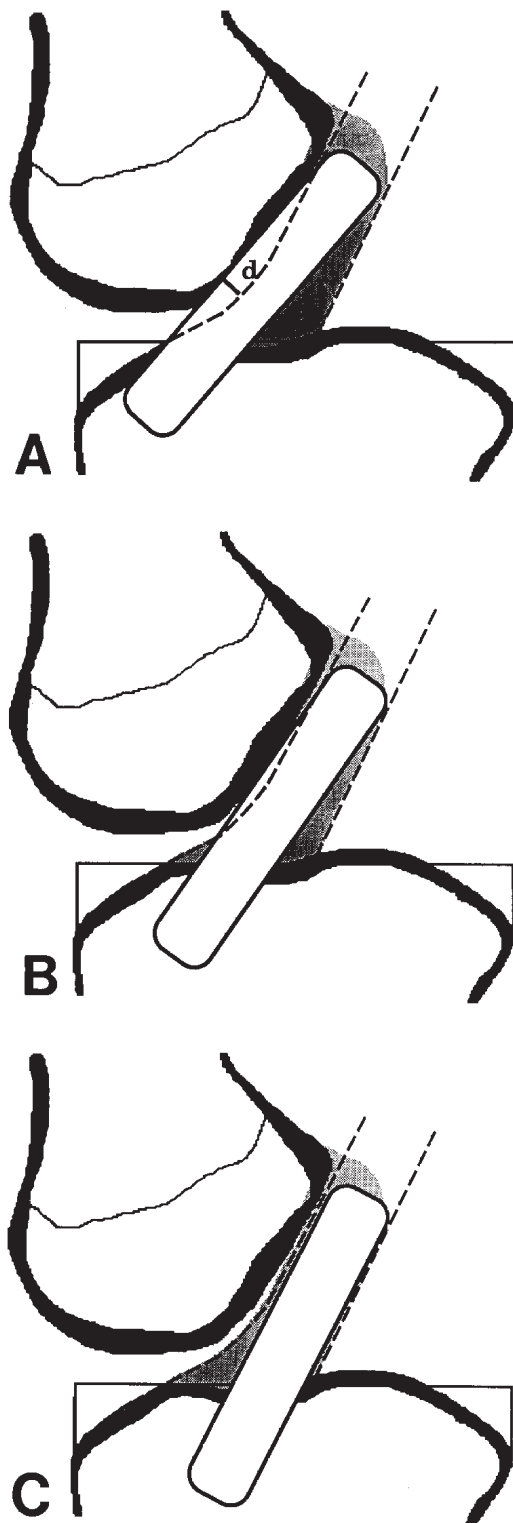


Figure 2. A, a 10 mm wide graft is centered over the eccentric tunnel location as recommended by Clancy et al⁵. Approximately 5 to 6 mm of bone (d) will need to be removed from the intercondylar roof in both acute and chronic reconstructions to prevent roof impingement of the graft as the knee reaches terminal extension. The graft will not lie eccentrically in the tunnel because the ACL graft courses vertically (64°) with the knee extended. B, approximately 2 to 3 mm of bone removal will be

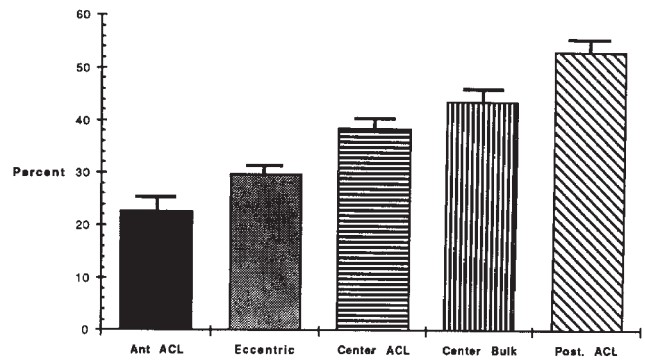


Figure 3. The sagittal locations of the measured ACL parameters are represented as percentages of the sagittal depth of the tibial plateau. The error bars represent 1 standard deviation.

($t = 22.55$, $df = 36$, $P < 0.001$), and the central position to the bulk location ($t = 7.24$, $df = 36$, $P < 0.001$). The degree of intercondylar roof impingement predicted for each of the three hypothetical tibial tunnel sites was significantly different. Positioning the center of the ACL graft eccentrically would require 4.8 ± 0.6 mm of bone removal from the intercondylar roof to prevent impingement. Positioning the center of the ACL graft within the midpoint of the ACL insertion would require 1.8 ± 0.8 mm of bone removal to prevent impingement. Very little bone removal (0.0 ± 0.7 mm) would be required if the tibial insertion site was centered within the bulk of the ACL fibers, a relatively posterior insertion site (Fig. 4).

The 95% confidence intervals for the independent analysis of the degree of intercondylar roof impingement for the hypothetical 10 mm graft centered at the three tibial tunnel locations were similar for both reviewers (Table 1). The measurements derived from the images were reproducible.

DISCUSSION

The measurements of ACL anatomy derived from these selected MR scans of normal knees agree with observations made in cadaver specimens.⁷ These studies have confirmed that the ligament is not uniform in diameter from origin to insertion. The tibial insertion is nearly two times deeper in the sagittal plane than the proximal one half (bulk) of the ACL.^{9,21} The ACL fans anteriorly in the sagittal plane, beginning its broadening 10 to 12 mm below the femoral origin as it courses distally to its tibial insertion.²¹ This fanning accommodates the undulating contour of the intercondylar roof, preventing acute angulation and impingement of the ligament

required in both acute and chronic reconstructions to prevent roof impingement when the graft is centered at the center of the ACL insertion. C, minimal bone resection will be needed when the tibial tunnel is located just 3 mm posterior to the center of the normal ACL insertion. Centering the graft so that it is aligned within the bulk of the ACL fibers will allow it to remain free from roof impingement without bone removal.

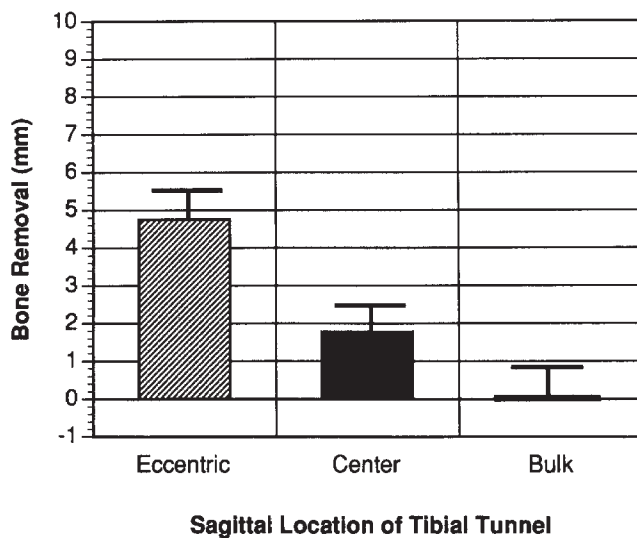


Figure 4. The mean amount of bone removal required to prevent impingement is displayed for the three sagittal locations of the tibial tunnel analyzed in this study. The error bars represent 1 standard deviation.

TABLE 1

Comparison of 95% confidence intervals of two authors^a

Reviewer	Eccentric tunnel placement (Clancy) ⁵ (mm)	Central tunnel placement (Odensten) ⁹ (mm)	Centered in bulk of ACL (mm)
TEF	4.4-5.2	1.5-2.3	-0.01-(0.5)
SMH	4.6-5.0	1.5-2.1	-0%(0.2)

^a Measurements of bone removal required from the intercondylar roof to prevent ACL graft impingement based on different tibial tunnel placements.

as the knee reaches terminal extension (Fig. 1A).

This broad anterior flare of the ACL insertion (18 mm deep in the sagittal plane) cannot be duplicated by a standard-sized, 10 mm in diameter tubular graft. Because of the differences in size and shape between the graft and the normal ACL, a compromise must be made in selecting the tibial location for the graft. This study predicts that 5 to 6 mm of bone would need to be removed from the intercondylar roof to prevent roof impingement for an eccentrically placed tibial tunnel (Fig. 2A). Positioning the graft within the center of the ACL insertion would require that 2 to 3 mm of the intercondylar roof be excised (Fig. 2B). These findings suggest that a roofplasty should be performed routinely in all acute and chronic ACL reconstructions. These recommendations are intended to provide an awareness of the potential for roof impingement and are to be used only as guidelines. Anatomical variability may demand more or less roof resection. For example, a knee with the potential to regain hyperextension will require more bone resection compared to a knee that extends only to neutral for the same sagittal position of the tibial tunnel.

Eccentric alignment of the graft within the tibial tunnel will not protect the graft from intercondylar roof impinge-

ment. The concept of eccentricity is based on the theory that the graft will tend to lie eccentrically (posteriorly) within the intraarticular opening of the tibial tunnel due to the oblique intraarticular course of the ACL with respect to the articular surface of the tibial plateau. It has been recommended that the tibial tunnel be made 5 mm anterior and medial to the center of the ACL insertion so that the posterolateral part of the circumference of the exit of the tunnel can be located at the anatomical center of the ACL insertion.⁵ This concept may have some validity in the flexed knee because at 90° of knee flexion the ACL is angled only 36° above the tibial joint surface.²¹ However, with the knee fully extended the ACL becomes more vertically oriented at an angle of 63° off the tibial plateau (Fig. 1). Due to this more vertical orientation, an ACL graft will lie centrally and not eccentrically in the tibial tunnel with the knee in full extension. Based on this anatomical analysis, impingement can be expected when the tibial tunnel is located in the eccentric position unless a roofplasty is performed routinely in both acute and chronic reconstructions.

Bone removal from the intercondylar roof can be minimized by orienting the tibial tunnel so that the graft is aligned within the bulk of the substance of the ACL (43.7% ± 2.3%). This location is 3 ± 2.3 mm posterior to the center of the ACL insertion based on an average-sized 60 mm tibial plateau. All of the graft fibers in this bulk position still lie entirely within the pathway of the normal ACL (Fig. 2C).

It must be determined if isometry can be achieved when an ACL graft is placed in the more posterior, bulk location on the tibial plateau. Biomechanical studies have found that the relationship between fiber elongation and knee flexion depends strongly on the fiber's femoral attachment but not on its tibial attachment location.¹¹ Isometry has been shown to be primarily controlled by tunnel placement on the cam-shaped femoral side.^{1,3,11-13} Because of the cam-shaped femoral condyle, isometric graft excursion requires that the femoral tunnel be located in a relatively small zone within the ACL origin.^{3,11,12} The femoral tunnel cannot be moved anterior or down the lateral wall of the intercondylar notch more than a few millimeters before the tunnel is outside the isometric zone.^{3,11-13,25}

In contrast to the relatively small isometric zone for the femoral tunnel, the region of the isometric zone on the flat tibia is relatively deep in the sagittal plane.^{3,11-13,25} The area of the femoral isometric zone remains exactly the same for a point selected at the extreme anterior or the extreme posterior edge of the ACL insertion. Only the orientation of the zone changes, with the zone being more vertical for the extreme posterior tibial attachment site.¹² The center of a graft aligned within the bulk of the ACL fibers is located 6 mm anterior to the extreme posterior edge of the ACL insertion, well within the isometric zone on the tibia. Therefore, biomechanical studies would predict that isometric graft placement can be achieved for a graft placed within the bulk of the ACL fibers.

Clinical experience supports the biomechanical predictions. We have placed the graft in the bulk position in over

60 knee reconstructions. Isometry was measured in each by attaching a tensiometer (Acufex Microsurgical, Norwood, MA) to a transarticular suture passed through 2.4 mm provisional pilot holes. Suture pistoning was measured as the knee was ranged from maximal hyperextension to 105° of flexion in the operating room. Excursions less than or equal to 2 mm were consistently achieved by placing the femoral guidepin 5 to 7 mm anterior to the over-the-roof position at either 11 o'clock (right knee) or 1 o'clock (left knee).¹⁴

Our clinical experience has indicated that, roof impingement is difficult if not impossible to directly visualize because the trochlea closes on the tibial articular surface as the knee reaches the terminal 10° to 15° of extension (Fig. 5). The relationship of the intercondylar roof to the graft is hidden and roof impingement goes unrecognized. Uncorrected roof impingement results in resistant flexion contractures.¹⁴ In our experience, judging the adequacy of a roofplasty is difficult and imprecise due to this hidden graft-roof relationship.

The selection of the MR scanning parameters in this study was based on the experience gained from performing over 300 scans of knees with reconstructed ACLs.¹⁴ The technique was developed in an attempt to minimize the technical difficulties associated with thin section imaging and metallic hardware artifacts. Although several authors^{7,16,17} have advocated the use of strong T2 weighting for the evaluation of native ACL disruption, several others have shown that tears in the ACL can be effectively demonstrated with either T1^{2,4} or proton density weighting.^{15,22} Because the signal-to-noise ratio of our images was already compromised by our strong

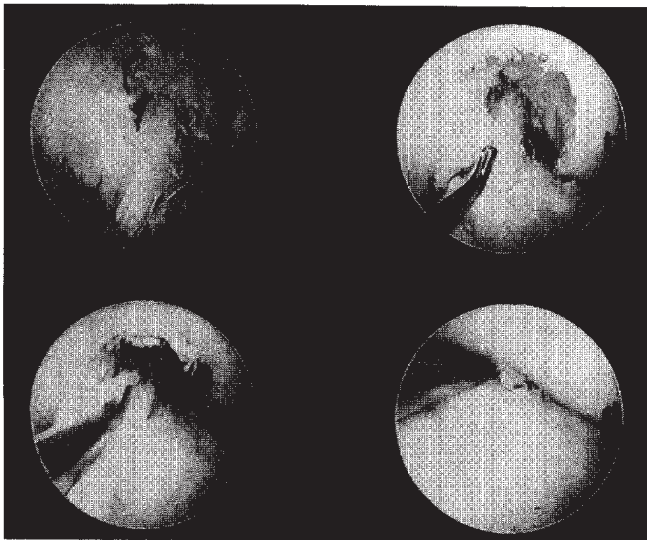


Figure 5. These arthroscopic images depict the ACL graft roof relationship as the knee is brought into extension. With the knee flexed to 90° (a), the intercondylar roof and graft are easily viewed. The graft-roof relationship is still well visualized at 45° of knee flexion (b). Contact between the graft and roof is difficult to view along the proximal half of the graft with the knee in 20° of flexion (c). At 5° of flexion, the graft cannot be visualized (d). This knee was then extended an additional 10° into 5° of hyperextension and the graft-roof relationship remained entirely out of view. Roof impingement can be difficult to detect.

desire to obtain high-resolution, thin section images (2.5 mm), we selected a relatively long repetition time (TR), to allow for more longitudinal recovery and hence more signal. Secondly, as the surgically placed metallic hardware artifacts, seen on MR images of reconstructed knees, are exacerbated by the TE prolongation of strong T2 weighting, we chose to reduce the TE to suppress this problematic phenomenon. The combination used in this study of a prolonged TR and a moderately reduced TE have yielded images that we believe are effective for maximizing the signal-to-noise ratio and suppressing metallic signal artifact. We attempted several other TR/TE selections early on in the research (including a long TR/TE, strong T2-weighted sequence), but found they all yielded inferior image quality.

In conclusion, this study emphasizes how variations in tibial tunnel placement control the potential for intercondylar roof impingement. Tibial tunnels placed anteriorly have more potential for roof impingement than posteriorly placed grafts. Prevention of roof impingement is dependent on recognizing that graft impingement is likely to occur and difficult to recognize. Guidelines have been presented that outline the indications and amount of bone removal required to avoid intercondylar roof impingement. Those surgeons preferring the eccentric tibial tunnel placement should perform a roofplasty in all acute and chronic reconstructions.

REFERENCES

1. Anderson AF, Lipscomb BA, Addlestone RB: Analysis of the intercondylar notch by computed tomography. *Am J Sports Med* 15: 547-552, 1987
2. Bellon EM, Keith MW, Coleman PE, et al: Magnetic resonance imaging of the knee. *Radiographics* 8: 95-117, 1988
3. Bradley J, Fitzpatrick O, Daniel D, et al: Orientation of the cruciate ligament in the sagittal plane. *J Bone Joint Surg* 70B: 94-99, 1988
4. Burk DL, Kanal E, Brunberg JA, et al: 1.5 T surface-coil magnetic resonance imaging of the knee. *AJR* 747: 293-300, 1986
5. Clancy W, Nelson D, Reider B, et al: Anterior cruciate ligament reconstruction using one-third patellar ligament, augmented by extra-articular tendon transfers. *J Bone Joint Surg* 64A: 352-359, 1982
6. Fullerton LR, Andrews JR: Mechanical block to extension following augmentation of the anterior cruciate ligament: A case report. *Am J Sports Med* 72: 166-168, 1984
7. Gallimore GW, Harms SE: Knee injuries: High-resolution MR imaging. *Radiology* 760: 457-461, 1986
8. Gillquist J, Odensten M: Arthroscopic reconstruction of the anterior cruciate ligament. *Arthroscopy* 4: 5-9, 1988
9. Good L, Odensten M, Gillquist J: Precision in reconstruction of the anterior cruciate ligament. *Acta Orthop Scand* 58: 658-661, 1987
10. Graf B, Uhr F: Complications of intra-articular anterior cruciate reconstruction. *Clin Sports Med* 7: 835-838, 1988
11. Hefty M, Grood E: Sensitivity of insertion locations on length patterns of anterior cruciate fibers. *J Biomech Eng* 108: 73-82, 1986
12. Hefty M, Grood E, Noyes F: Factors affecting the region of most isometric femoral attachments. Part II: The anterior cruciate ligament. *Am J Sports Med* 77: 208-216, 1989
13. Hoogland T, Hillen B: Intra-articular reconstruction of the anterior cruciate ligament. *Clin Orthop* 185: 197-202, 1984
14. Howell SM, Berns GS, Farley TE: Signal intensity measurements of unimpinged and impinged anterior cruciate ligament grafts. *Radiology*, in press, 1991
15. Lambert KL: Vascularized patellar tendon graft with rigid internal fixation for anterior cruciate ligament insufficiency. *Clin Orthop* 172: 85-89, 1983

16. Lee JK, Yao L, Phelos CT, et al: Anterior cruciate ligament tears: MR imaging compared with arthroscopy and clinical tests. *Radiology* 166: 861-864, 1988
17. Li DKB, Adams ME, McConkey JP: Magnetic resonance imaging of the ligaments and menisci of the knee. *Radiol Clin North Am* 124: 209-227, 1986
18. Lukianov AV, Richmond JC, Barrett GR, et al: A multicenter study on the results of anterior cruciate ligament reconstruction using a dacron ligament prosthesis in salvage cases. *Am J Sports Med* 17: 380-386, 1989
19. Mott WM: Semitendinosus anatomic reconstruction for cruciate ligament insufficiency. *Clin Orthop* 172: 90-92, 1983
20. Norwood LA Jr, Cross MJ: The intercondylar shelf and the anterior cruciate ligament. *Am J Sports Med* 5: 171-176, 1977
21. Odensten M, Gillquist J: Functional anatomy of the anterior cruciate ligament and a rationale for reconstruction. *J Bone Joint Surg* 67A: 257-262, 1985
22. Penner DA, Daniel DM, Wood P, et al: An in vitro study of anterior cruciate graft placement and isometry. *Am J Sports Med* 76: 238-243, 1988
23. Reicher MA, Hartzman S, Bassett LW, et al: Magnetic resonance of the knee. Part I: Traumatic disorders. *Radiology* 762: 547-551, 1987
24. Sachs RA, Daniel DM, Stone ML, et al: Patellofemoral problems after anterior cruciate ligament reconstruction. *Am J Sports Med* 17: 760-766, 1989
25. Sidles J, Larson R, Garbini J, et al: Ligament length relationships in the moving knee. *J Orthop Res* 6: 593-610, 1988
26. Staller DW: *Magnetic Resonance Imaging in Orthopedics and Rheumatology*. Philadelphia, JB Lippincott Co, 1989, pp 128-137