

The EZLoc: A Simple, Rigid Femoral Fixation Device for a Soft Tissue Anterior Cruciate Ligament Graft

Akio Matsumoto, M.D.,* and Stephen M. Howell, M.D.†

Summary: The EZLoc is a new femoral fixation device for soft tissue anterior cruciate ligament (ACL) reconstruction that combines superior fixation properties (1427 N strength, ∞ N/mm stiffness, and high resistance to slippage) with a simple surgical technique. The EZLoc is composed of a slotted body through which the ACL graft is looped and a deployable lever arm that rigidly fixes the graft on the anterolateral cortex of the femur. The EZLoc comes in a sterile package with a sharp-tip passing pin that is secured in the slotted body with a suture tied under tension. After the ACL graft is passed into the femoral tunnel, the suture is cut, the passing pin is removed, and the suture is tensioned, which deploys the lever arm and fixes the EZLoc on cortical bone. The EZLoc can be used with both the one- and 2-tunnel ACL reconstruction techniques, and is available in several length and diameter combinations that are for use in tunnels ranging from 20 to 60 mm in length and ACL grafts ranging from 5 to 10 mm in diameter. **Key Words:** EZLoc—Anterior cruciate ligament reconstruction—Femoral fixation device—Soft tissue graft—Superior fixation properties—Reliable surgical technique.

The EZLoc (Arthrotek, Inc., Warsaw, IN) is a femoral fixation device for soft tissue anterior cruciate ligament (ACL) reconstruction. The EZLoc provides superior fixation properties that allow aggressive rehabilitation combined with a simple, reliable surgical technique. Both the high-volume and occasional ACL surgeon and surgical team have found the EZLoc easy to use since being approved for use in late 2004.

Description of the EZLoc

The EZLoc is a small fixation device that is composed of a slotted body through which the ACL graft is looped and a deployable lever arm that rests on the anterolateral cortex of the femur. The lever arm provides rigid fixation that is better than a cross pin because the lever arm seats

on cortical bone on the anterolateral femur, which is 50 times stronger than cancellous bone² (Fig. 1).

The EZLoc is available in 3 sizes (5/6, 7/8, 9/10). The size of the EZLoc is selected to match the diameter of the femoral tunnel. The larger size, 7/8 and 9/10, EZLocs are used with 7/8 and 9/10 diameter tunnels, respectively. Each of the larger-sized EZLocs are available in 3 lengths: “standard,” which is used in tunnels 35 to 50 mm in length; “short,” which is used in tunnels shorter than 35 mm; and “long,” which is used in tunnels greater than 50 mm in length (Table 1). The smaller size, 5/6 EZLoc is available in one length and are used in the smaller-diameter and shorter-length posterolateral tunnel in a 2-tunnel reconstruction.

For ease of use, each EZLoc comes sterilely packaged. All 3 lengths of the 7/8 and 9/10 EZLoc are packaged with a 16-inch long, sharp-tip passing pin that is secured in the proximal end of the slotted body by a suture tied under tension (Fig. 2). The suture passes through the lever arm and the sharp tip of the passing pin. The passing pin keeps the lever arm from deploying and is used to pull the graft across the knee and orient the lever arm lateral. Once the ACL graft is pulled into the femoral tunnel, the

From the *Department of Orthopaedic Surgery, Kobe University Graduate School of Medicine, Kobe, Japan; and the †Department of Mechanical Engineering, University of California at Davis, Davis, CA.

Address correspondence and reprint requests to Stephen M. Howell, MD, Associate Professor, Department of Mechanical Engineering, University of CA at Davis, Davis, CA 95616, 8100 Timberlake Way, Suite F, Sacramento, CA 95823. E-mail: sebhowell@mac.com

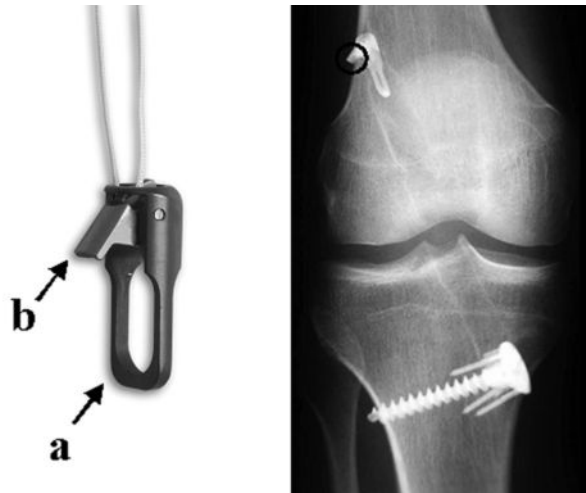


FIG. 1. The EZLoc is a small femoral fixation device that is composed of a body with a slot (A) and a gold-colored lever arm (B). The lever arm provides more rigid fixation than a cross pin or interference screw because it seats on the cortex of the femur (circle), is infinitely stiff, and does not slip under cyclic load. The body prevents anteroposterior and medial lateral micromotion during knee motion. The slot in the body can be used to fix one and 2 strand soft tissue anterior cruciate ligament grafts.

suture is cut, the passing pin is removed, the suture is tensioned, and the lever arm deploys.

The 5/6 EZLoc is used in the posterolateral tunnel of a 2-tunnel ACL reconstruction, whereas the 7/8 and 9/10 EZLocs are used in the anteromedial tunnel (Fig. 3). When the posterolateral femoral tunnel and tibial tunnel are not on the same axis, the passing pin is removed from the smaller size EZLocs and the suture is used to pass the graft. The passing pin is not needed to orient the lever arm with a graft in the posterolateral femoral tunnel because the lever arm sits “low profile” in any orientation because the axis of the tunnel is perpendicular to the femoral cortex.

Fixation Properties of the EZLoc

An important component to a successful ACL reconstruction with a soft tissue graft is the use of a femoral fixation device that has superior fixation properties and




FIG. 2. EZLoc comes sterilely packaged with a passing pin and suture. The dull end of a 16-inch long, sharp-tip passing pin is secured in the proximal end of the slotted body by a suture tied under tension. The passing pin is used to pull the anterior cruciate ligament (ACL) graft into place and to orient the lever arm lateral. In the special situation when the EZLoc is used in the posterolateral femoral tunnel in a 2-tunnel ACL reconstruction technique, and the posterolateral femoral tunnel is not in the same axis as the tibial tunnel, the passing pin is removed from the EZLoc and the suture is used to pull the graft.

enhances biologic healing of the tendon to the tunnel wall. The fixation properties of a soft tissue fixation device should provide high strength, high stiffness, resistance to slippage, and allows circumferential healing of the tendon to the tunnel wall.^{5,9,11,16,17} Because the healing rate of a soft tissue graft is slower than a bone plug graft in a tunnel, a soft tissue fixation devices should function better in vivo than the fixation device for a bone plug graft.¹⁸

TABLE 1. Method for Selecting the Length of the EZLoc Based on the Length of the Femoral Tunnel and Calculating the Length of the Anterior Cruciate Ligament Graft in the Femoral Tunnel

Length of the EZLoc	Length of Femoral Tunnel	Length of Graft in Femoral Tunnel
Short (7 mm)	35 mm or shorter	Femoral tunnel – 7 mm = graft in tunnel (less than 28 mm)
Standard (12 mm)	35–50 mm	Femoral tunnel – 12 mm = graft in tunnel (23–38 mm)
Long (22 mm)	50 mm or longer	Femoral tunnel – 22 mm = graft in tunnel (more than 28 mm)

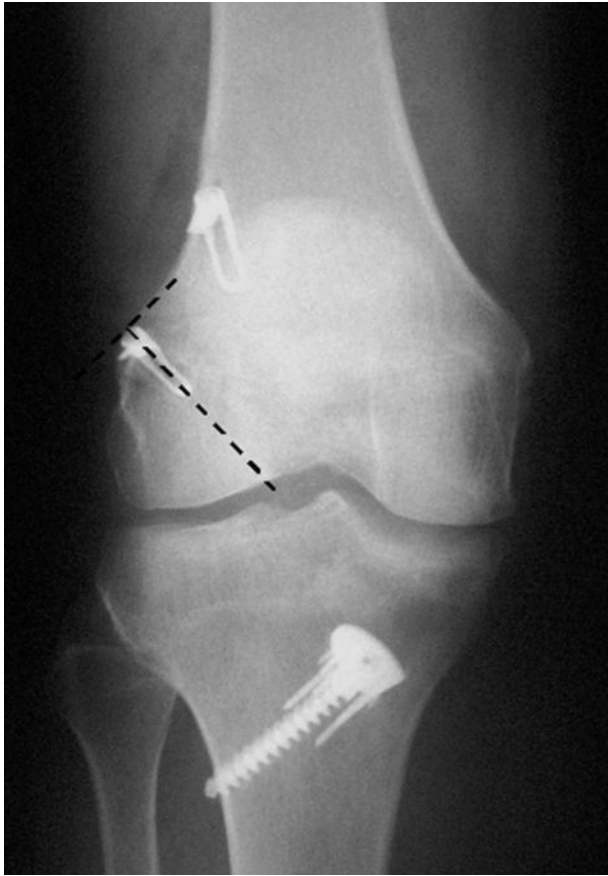

FIG. 3. This case demonstrates the use 2 EZLocs to fix the graft in the femur in the 2-tunnel technique. A size 5/6 EZLoc fixes a single loop of gracilis tendon in the posterolateral femoral tunnel. A size 7/8 "standard" length EZLoc fixes a single loop of semitendinosus tendon in the more vertical anteromedial femoral tunnel. The short lever arm of the 5/6 EZLoc sits "low profile" in any orientation because the axis of posterolateral femoral tunnel is perpendicular to the femoral cortex (dotted line).

We prefer the use of the EZLoc to fix a soft tissue graft in the femur because its fixation properties are second to none and the device allows circumferential healing. The strength of the EZLoc is 1427 N, which is stronger than the closed-loop endobutton (1086 N) and the cross pins (Bone Mulch Screw 1112N, Transfix 1303N, RigidFix 868N).^{3,10} The stiffness of the EZLoc on bone is infinite; although the stiffness of the EZLoc with a soft tissue graft has not been measured, it should be at least as stiff as a cross pin because the mechanism of looping the graft over a metal post is identical in both types of fixation methods. The use of the a high-stiffness fixation device like the EZLoc benefits the knee by lowering the initial tension that is applied to the graft to restore stability.^{4,9,11,17} Similar to stiffness, the slippage of the EZLoc with the soft tissue graft has not been measured; how-

ever, it should resist slippage at least as well as a cross pin because the mechanism of looping the graft over a metal post is identical in both types of fixation methods.¹⁴ The EZLoc promotes healing of the tendon to the tunnel wall better than an interference screw because the soft tissue graft fixed with the EZLoc heals circumferentially to the tunnel wall.¹⁶

Combining the EZLoc with the WasherLoc tibial fixation device (Arthrotek, Inc., <http://www.arthrotek.com>) and compaction of a bone dowel in the tibial tunnel creates a graft-fixation device construct with superior fixation properties that allows an early, aggressive, and brace-free rehabilitation.¹³ With this fixation technique and correct tunnel placement, the majority of patients regain sufficient function and confidence in their knee to return to preinjury activity level 4 months after reconstruction similar to femoral fixation with the Bone Mulch Screw (Arthrotek, Inc.).⁶

Reliable Surgical Technique With Minimal Steps

Important considerations in the selection of a femoral fixation device is that the device reliably deploys, requires minimal steps for insertion, and is easy to use for both the high-volume and occasional ACL surgeon and surgical team. The EZLoc has been designed to seat reliably on cortical bone, work well in soft bone, work well when there is a blowout of the posterior wall of the femoral tunnel, and to not hang up in the tunnel. The broad slotted body prevents the EZLoc from hanging up in the muscles overlying the lateral thigh. Softening of the cancellous bone in the femur from disuse, aging, smoking, and alcohol use does not affect the fixation properties of the EZLoc because it seats on cortical, not cancellous, bone. The EZLoc functions equally well with a femoral tunnel with a thin 1-mm back wall and with a femoral tunnel with a posterior wall blowout. A femoral tunnel with a thin 1-mm back wall is needed so that the tension in the graft matches that of the intact ACL.¹⁵ The use of a 1-inch femoral reamer rather than an acorn-tipped reamer creates a smoother tunnel so that the EZLoc does not hang up during passage across the knee.

The surgical steps for fixing a soft tissue ACL graft to the femur are simple and few. The diameter of the tibial and femoral tunnel is chosen from the smallest cylinder that freely passes over the ACL graft when it is looped through a sizing stick (described later). The length of the lateral wall of the femoral tunnel is measured with a depth gauge. The tip of the passing pin is inserted across the tibial and femoral tunnel and through the skin of the anterolateral thigh. The soft tissue graft is passed through the slot in the EZLoc and the length of the femoral tunnel is marked on the graft by measuring from the distal tip of

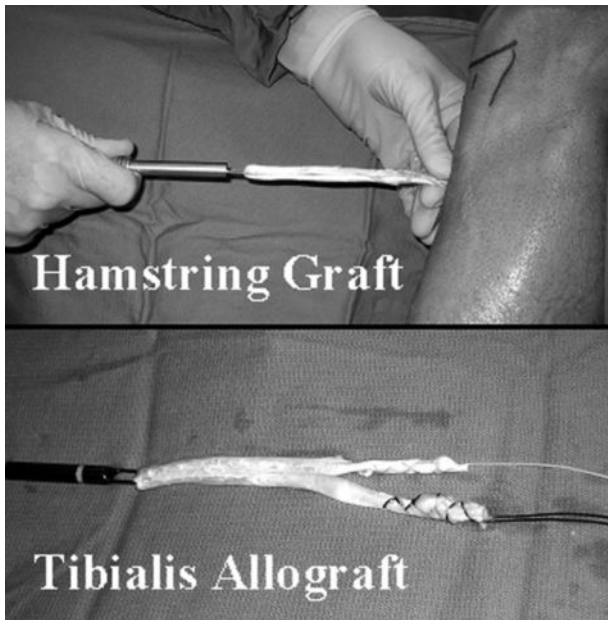


FIG. 4. The double-looped semitendinosus and gracilis autograft and the tibialis allograft require no special suturing for use with the EZLoc. A suture is sewn to the end of each tendon so that the graft can be tensioned at the time of tibial fixation.

the lever arm. With the lever arm facing lateral, the passing pin is pulled until the mark on the graft enters the femoral tunnel. The suture is cut, the passing pin is removed, the suture is tensioned, and the lever arm is deployed. Tension is applied to the graft exiting the tibial tunnel. The seating of the lever arm on the anterolateral cortex of the femur is easily felt. Hence, passing the graft and rigidly fixing the graft to the femur is accomplished with confidence and reliably in essentially the same step.

SURGICAL TECHNIQUE

The surgical technique for fixing a soft tissue ACL graft to the femur with the EZLoc using a single tunnel, trans-tibial technique can be viewed in streaming video at this web site: http://www.drstevehowell.com/ezloc_video.cfm.

Prepare and Size the Hamstring or Tibialis Allograft

The preparation of the soft tissue ACL graft for use with the EZLoc requires no special suturing or tensioning, which adds to the simplicity of the surgical technique. Sew a no. 1 suture to each end of a double-looped semitendinosus and gracilis autograft or a single-looped tibialis allograft (Fig. 4). Use the 7/8-mm and 9/10-mm sizing sticks to determine the diameter of the graft. Loop the graft in the slot of the 7/8-mm sizing stick. Judge the

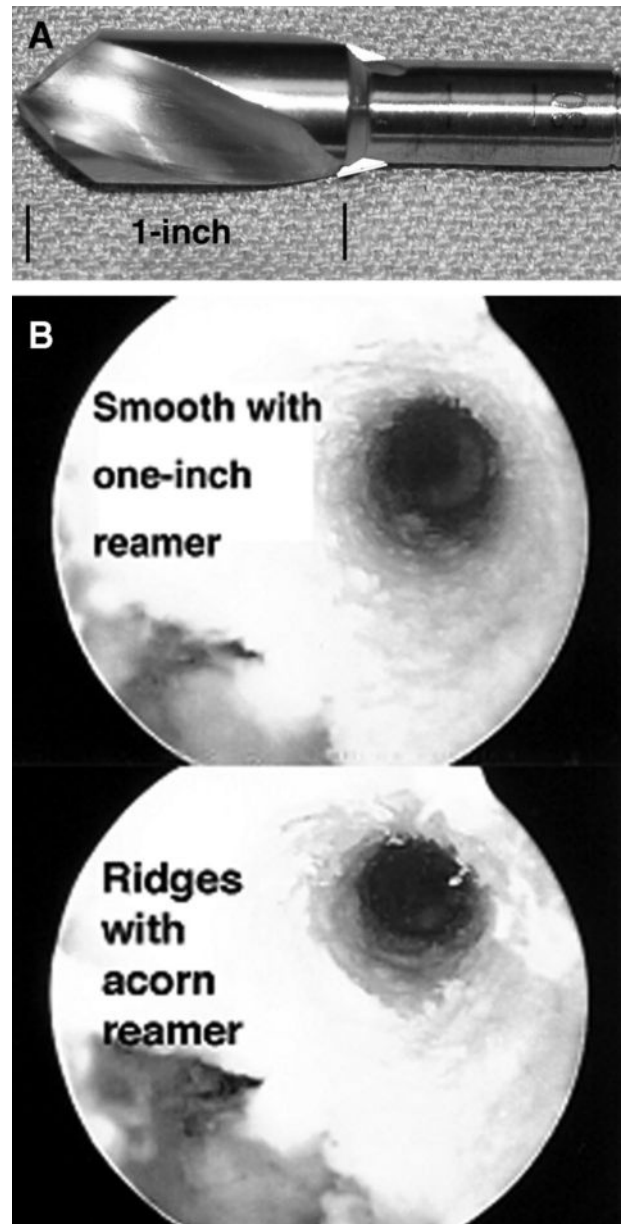


FIG. 5. The femoral tunnel should be drilled with a 1-inch reamer rather than an acorn reamer (left). The 1-inch reamer creates a smooth femoral tunnel, whereas the acorn reamer leaves ridges (right). The EZLoc passes reliably and without “hang up” in a smooth femoral tunnel made with the 1-inch reamer.

diameter of the graft by attempting to “throw” a 7 and 8 mm in diameter sizing sleeve over tip of the sizing stick and graft. Repeat the assessment with the 9/10-mm sizing stick and 9/10-mm sizing sleeves. Drill the tibial and femoral tunnels using the diameter of the smallest sizing sleeve that freely passes over the graft. Store the graft in a saline basin. Submerge the graft in a saline

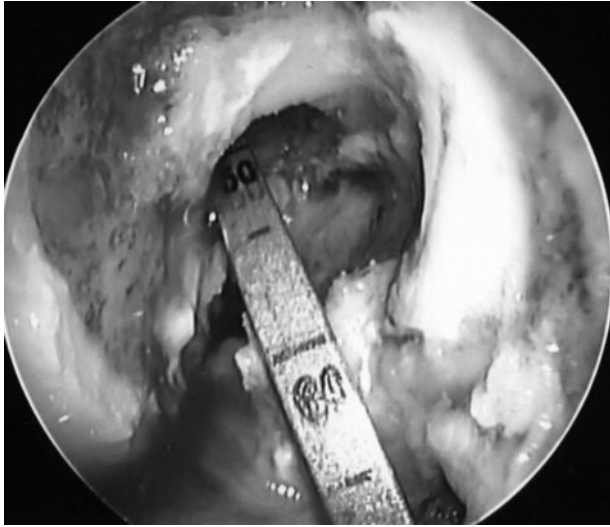


FIG. 6. The length of the lateral wall of the femoral tunnel is measured with a depth gauge inserted through the tibial and femoral tunnels. The tip of the depth gauge is hooked on the lateral cortex of the femur. The length of femoral tunnel in this subject is 50 mm and is measured at the opening of the femoral tunnel into the notch.

basin. Keep the graft inside the sizing sleeve, to prevent the submerged graft from swelling.

Place the Tibial Tunnel

Use the transtibial technique described in this issue of the journal to drill the femoral tunnel through a correctly placed tibial tunnel.¹² Briefly, correct placement of the tibial tunnel is easy and reproducible with use of the Howell 65 Degree Tibial Guide (Arthrotek, Inc.), which is designed to place the ACL graft without posterior cruciate ligament (PCL) and roof impingement. Angle the tibial tunnel 60° to 65° with the medial joint line and position the lateral edge of the tibial tunnel so that it passes through the apex of the lateral tibial spine in the coronal plane to avoid PCL impingement. Position the center of the tibial tunnel 5 to 6 mm posterior and parallel to the intercondylar roof with the knee in maximum hyperextension in the sagittal plane to avoid roof impingement without performing a roofplasty.⁷

Place and Adjust the Length of the Femoral Tunnel

Position the femoral tunnel with a 1-mm back wall with the use of a size-specific femoral aimer (Arthrotek, Inc.). Insert the femoral aimer through the tibial tunnel and hook it over the posterior edge of the intercondylar notch. Select the 2.4-mm drill tip K-wire with marks at 35 and 50 mm (Arthrotek, Inc.). Drill the K-wire until the tip stops at the anterolateral femoral cortex. Estimate the length of the femoral tunnel by checking the marks on

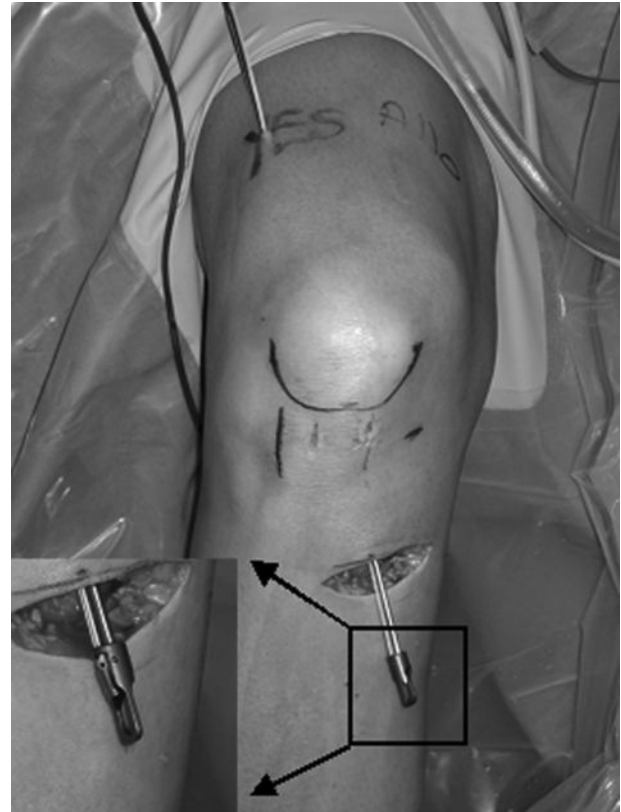


FIG. 7. The sharp end of the passing pin is inserted through the tibial and femoral tunnels and skin overlying the anterolateral thigh. The passing pin is rotated until the gold lever arm on the EZLoc faces lateral (inset).

the K-wire. If the 35-mm mark is inside the femur, but the 50-mm mark is not, then the length of the femoral tunnel will be between 35 and 50 mm. Finish drilling the K-wire through the anterolateral cortex. If the femoral tunnel is estimated to be longer than 50 mm, then remove the K-wire and femoral aimer, flex the knee an additional 10° to 15°, and drill the K-wire through the same starting hole. Adjust the trajectory of the K-wire until the length of the femoral tunnel is between 35° and 50°, which will require the “standard”-length EZLoc. The tension pattern of an ACL graft placed with this transtibial technique and with these specifications replicates the tension pattern of the intact ACL.¹⁵

Drill the Femoral Tunnel With a 1-Inch Femoral Reamer

Drill the femoral tunnel through the anterolateral cortex of the femur with a cannulated 1-inch femoral reamer (Arthrotek, Inc.) that matches the diameter of the ACL graft. Piston the reamer in and out of the femoral tunnel 2 to 3 times to smooth the tunnel. The 1-inch femoral

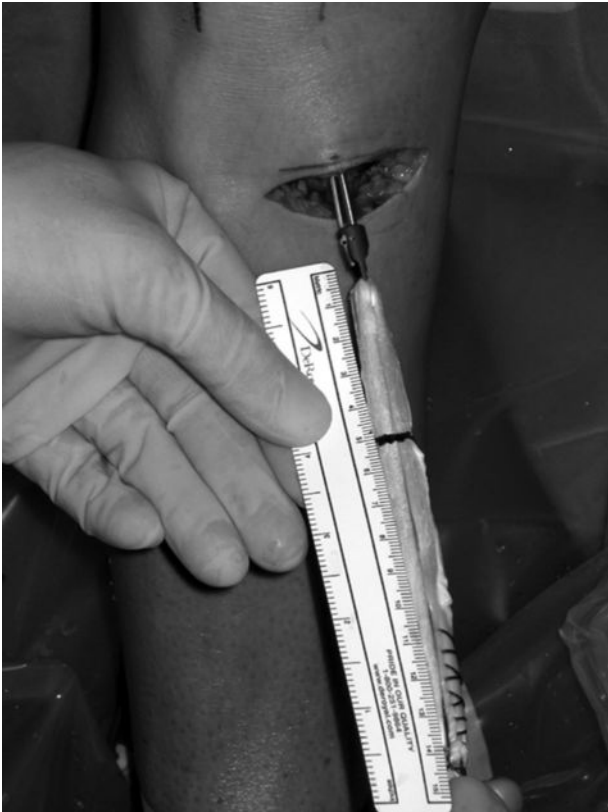

FIG. 8. The soft tissue graft is looped through the slot in the body of the EZLoc. A ruler is placed at the tip of the gold lever arm, and the length of the femoral tunnel is marked on the graft (blue line). The graft is pulled across the knee until the mark enters the femoral tunnel.

reamer creates a smoother tunnel wall than the shorter, tapered cutting tip of an acorn reamer (Fig. 5). The EZLoc does not hang up when the femoral tunnel is drilled with the 1-inch femoral reamer.

Measure the Length of Femoral Tunnel and Choose the Length of EZLoc

Insert the depth gauge through the tibial tunnel into the femoral tunnel. Hook a tip of the depth gauge on the lateral cortex of the femur. Read the length of the lateral wall of the femoral tunnel at the point where the depth gauge enters the femoral tunnel (Fig. 6). Choose a “standard EZLoc” when the femoral tunnel length is between 35 and 50 mm, a “short EzLoc” when the femoral tunnel length is less than 35 mm, and a “long EZLoc” when the femoral tunnel length is greater than 50 mm (Table 1).

Insert the EZLoc and Fix the Soft Tissue Graft to the Femur

Push the passing pin attached to the properly sized EZLoc across the tibial and femoral tunnels and through

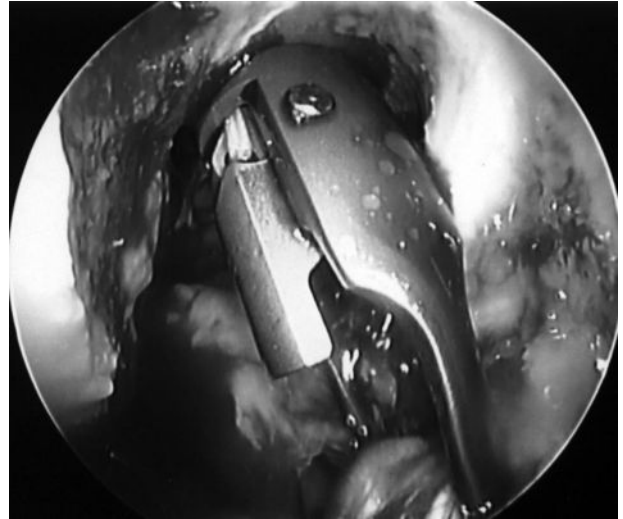


FIG. 9. The orientation of the gold lever arm is checked before the EZLoc enters the femoral tunnel. The gold lever should be lateral.

the skin overlying the anterolateral thigh. Rotate the gold lever arm lateral (Fig. 7). Loop the soft tissue ACL graft through the slot in the body of the EZLoc and tie together the sutures at the each end of each tendon. Mark the length of femoral tunnel on the graft by measuring from the tip of the lever arm (Fig. 8). Pull the passing pin proximally until the lever arm enters the notch. Confirm the lever arm points lateral (Fig. 9) and then pull the passing pin until the mark of the graft enters the femoral tunnel. Cut the suture, remove the passing pin, and tension the suture, which deploys the lever arm. Pull on the distal end of the graft until the sudden, firm grip of the lever arm on cortical bone is felt. The lever arm rests lateral and low profile on the anterolateral cortex of the femur (Fig. 1).

Tibial Fixation

Fix the graft to the tibia with the knee in maximum extension. We prefer to use WasherLoc and compact the bone dowel, which is described in this issue of the journal.¹³

CONCLUSION

The EZLoc is a femoral fixation device for soft tissue ACL reconstruction that is simple and reliable for both the high-volume and occasional ACL surgeon and surgical team. The EZLoc combines superior fixation properties (1427 N strength, ∞ N/mm stiffness, and high resistance to slippage) and allows circumferential healing of the tendon graft to the tunnel wall, which allows

aggressive rehabilitation without a brace and return to sport at 4 months.^{1,6,8}

REFERENCES

1. Aglietti P, Giron F, Buzzi R, et al. Anterior cruciate ligament reconstruction: bone-patellar tendon-bone compared with double semitendinosus and gracilis tendon grafts. A prospective, randomized clinical trial. *J Bone Joint Surg [Am]* 2004;86:2143–2155.
2. Amis AA. The strength of artificial ligament anchorages. A comparative experimental study. *J Bone Joint Surg [Br]* 1988;70:397–403.
3. Becker R, Voigt D, Starke C, et al. Biomechanical properties of quadruple tendon and patellar tendon femoral fixation techniques. *Knee Surg Sports Traumatol Arthrosc* 2001;9:337–342.
4. Eagar P, Hull ML, Howell SM. How the fixation method stiffness and initial tension affect anterior load-displacement of the knee and tension in anterior cruciate ligament grafts: a study in cadaveric knees using a double-loop hamstrings graft. *J Orthop Res* 2004; 22:613–624.
5. Grover DM, Howell SM, Hull ML. Early tension loss in an anterior cruciate ligament graft. A cadaver study of four tibial fixation devices. *J Bone Joint Surg [Am]* 2005;87:381–390.
6. Howell SM, Deutsch ML. Comparison of endoscopic and two-incision techniques for reconstructing a torn anterior cruciate ligament using hamstring tendons. *Arthroscopy* 1999;15:594–606.
7. Howell SM, Lawhorn KW. Gravity reduces the tibia when using a tibial guide that targets the intercondylar roof. *Am J Sports Med* 2004;32:1702–1710.
8. Howell SM, Taylor MA. Brace-free rehabilitation, with early return to activity, for knees reconstructed with a double-looped semitendinosus and gracilis graft. *J Bone Joint Surg [Am]* 1996; 78:814–825.
9. Karchin A, Hull ML, Howell SM. Initial tension and anterior load-displacement behavior of high-stiffness anterior cruciate ligament graft constructs. *J Bone Joint Surg [Am]* 2004;86:1675–1683.
10. Kousa P, Jarvinen TL, Vihavainen M, et al. The fixation strength of six hamstring tendon graft fixation devices in anterior cruciate ligament reconstruction. Part I: femoral site. *Am J Sports Med* 2003;31:174–181.
11. Magen HE, Howell SM, Hull ML. Structural properties of six tibial fixation methods for anterior cruciate ligament soft tissue grafts. *Am J Sports Med* 1999;27:35–43.
12. Matsumoto A, Howell SM. Avoiding PCL and roof impingement with transtibial anterior cruciate ligament reconstruction: keys to correct tunnel placement. *Techniques in Orthopaedics*. 2005.
13. Matsumoto A, Howell SM. WasherLoc and Bone Dowel. *Techniques in Orthopaedics*. 2005.
14. Roos PJ, Hull ML, Howell SM. Lengthening of double-looped tendon graft constructs in three regions after cyclic loading: a study using roentgen stereophotogrammetric analysis. *J Orthop Res* 2004;22:839–846.
15. Simmons R, Howell SM, Hull ML. Effect of the angle of the femoral and tibial tunnels in the coronal plane and incremental excision of the posterior cruciate ligament on tension of an anterior cruciate ligament graft: an in vitro study. *J Bone Joint Surg [Am]* 2003;85:1018–1029.
16. Singhatat W, Lawhorn KW, Howell SM, et al. How four weeks of implantation affect the strength and stiffness of a tendon graft in a bone tunnel: a study of two fixation devices in an extraarticular model in ovine. *Am J Sports Med* 2002;30:506–513.
17. To JT, Howell SM, Hull ML. Contributions of femoral fixation methods to the stiffness of anterior cruciate ligament replacements at implantation. *Arthroscopy* 1999;15:379–387.
18. Tomita F, Yasuda K, Mikami S, et al. Comparisons of intraosseous graft healing between the doubled flexor tendon graft and the bone-patellar tendon-bone graft in anterior cruciate ligament reconstruction. *Arthroscopy* 2001;17:461–476.