



Chapter 121

Kinematic Alignment in Total Knee Arthroplasty

Stephen M. Howell and Maury L. Hull

The most important predictor of clinical outcome in total knee arthroplasty (TKA) is placement of the femoral and tibial components. Prior to the advent of kinematic alignment, the placement of components was based on the widely accepted principles of classic mechanical alignment, as follows: (1) aligning the femoral component perpendicular to the mechanical axis of the femur; (2) aligning the tibial component perpendicular to the mechanical axis of the tibia; (3) adjusting the anterior-posterior and internal-external rotation positions of the femoral component so that the extension and flexion gaps are equal; and (4) releasing ligaments when necessary to restore motion and balance the knee. In kinematic alignment, the principles for placing the components are different from those of classic mechanical alignment, as follows: (1) coaligning the transverse axis of the best-fitting femoral component with the primary transverse axis in the femur about which the tibia flexes and extends; (2) removing osteophytes to restore ligament length motion and stability; and (3) placing the tibial component so that the longitudinal axis of the tibia is perpendicular to the transverse axis in the femur, about which the tibia flexes and extends.

Kinematic alignment can prevent the loss of flexion and extension, stiffness, instability, pain, and prolonged recovery associated with mechanical alignment.^{16,17} Kinematic alignment of the femoral component is confirmed intraoperatively by comparing the symmetry of the thickness of the distal medial, distal lateral, posterior medial, and posterior lateral femoral bone resections after measuring the thickness of the resections with calipers and after correcting for cartilage wear, bone wear, and kerf (i.e., the bone removed by the saw blade). Once kinematic alignment of the femoral component is confirmed, restoring motion and balancing the total knee arthroplasty is simplified by following a stepwise algorithm. The algorithm consists of four steps—removing osteophytes, adjusting the plane of the tibial cut, releasing the posterior capsule from the femur, and medializing or lateralizing the tibial component.

This chapter reviews the history and definition of kinematic alignment with patient-specific guides, highlights the inherent disadvantages of mechanical alignment that kinematic alignment strives to avoid, describes the planning, outlines the algorithm for restoring motion and balancing the kinematically aligned TKA, provides an overview of the surgical technique of kinematic alignment with patient-specific cutting guides and unconventional use of conventional instruments, addresses theoretical concerns of kinematic alignment, and reviews clinical studies showing the early benefits of kinematically aligning the TKA.

HISTORY AND DEFINITION OF KINEMATIC ALIGNMENT

The biomechanical rationale for kinematic alignment is traced to Hollister and colleagues' classic research on the

kinematics of the knee.¹² Kinematics refers to the relative relationship of the femur, patella, and tibia at any angle of flexion, without force applied to the knee. The joint surface, menisci, and ligament structures determine the normal kinematic relationship among the femur, patella, and tibia. The center of the femoral head and center of the ankle, which are used by conventional and computer-assisted instruments to align a TKA mechanically, have no bearing on the kinematics of the knee.^{10,11,14,15}

Three axes govern the movement of the patella and tibia with respect to the femur, and understanding how the placement of the femoral and tibial components affects the interrelationship of these axes is the key to kinematically aligning a TKA (Fig. 121-1). The primary axis is a transverse axis in the femur about which the tibia flexes and extends. It passes through the center of a circle fit to the articular surface of the femoral condyles from 10 to 160 degrees of flexion.^{7,10-12} There is a second transverse axis in the femur about which the patella flexes and extends that is parallel, proximal, and anterior to the transverse axis in the femur about which the tibia flexes and extends. The third axis is a longitudinal axis in the tibia about which the tibia internally and externally rotates on the femur that is perpendicular to each of the two transverse axes in the femur. Although each of the three axes is aligned parallel or perpendicular to one another, none are aligned orthogonally to the three anatomic planes, which means that the axis cannot be found with imaging studies performed in the sagittal, coronal, and axial planes.¹⁵

The goal for kinematically aligning the femoral component is to coalign the transverse axis of a symmetrical femoral component with the primary transverse axis in the femur about which the tibia flexes and extends (Fig. 121-2).^{7,10-12,14} Because there is no clinically important asymmetry between the medial and lateral femoral condyles in the varus and valgus knee with end-stage osteoarthritis, a symmetrical, single-radius femoral component is an optimal design for replicating knee kinematics.

The principle for kinematically aligning the femoral component to the femur is the simple step of shape-matching the femoral component to the articular surface of the femur on a three-dimensional model of the knee that has been restored to normal by filling in the worn articular surface. Shape matching the femoral component to the femur coaligns the transverse axis of the femoral component with the primary transverse axis in the femur about which the tibia flexes and extends, which is requisite to restoring the normal interrelationships among the three axes.^{13,16}

In contrast to the simplicity of kinematically aligning the femoral component, kinematically aligning the tibial component involves several steps. The first step is to align the anterior-posterior axis of the tibial component perpendicular to the transverse axis in the femoral component, which has previously been coaligned to the primary transverse axis in

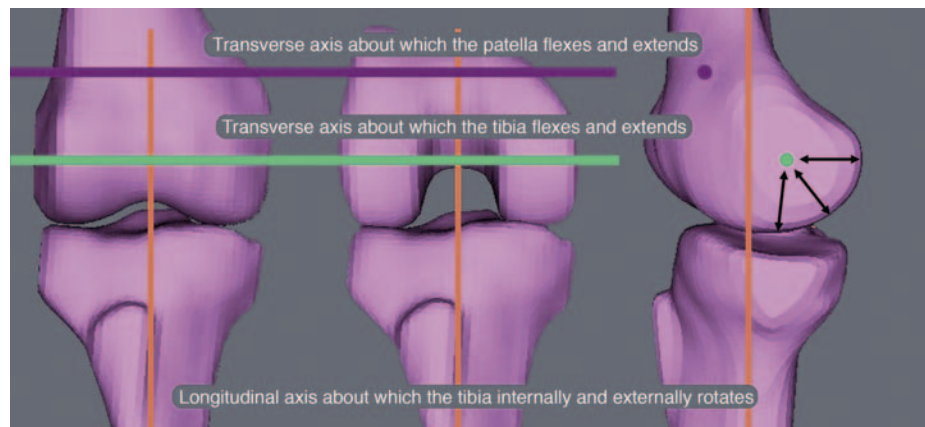


Figure 121-1. Interrelationship of the three kinematic axes in a right knee. **A**, Coronal projection with the knee in extension. **B**, Axial projection of the femur with the knee in 90 degrees of flexion. **C**, Lateral projection with the knee in extension. The primary transverse axis in the femur about which the tibia flexes and extends passes through the center point of the best-fit circles of the medial and lateral femoral condyles (*green line and circle*), which is equidistant from the articular surface of the condyles (*double-headed black arrows*). A second transverse axis in the femur about which the patella flexes and extends axis (*magenta line and circle*) is oriented parallel, proximally, and anteriorly to the transverse axis in the femur about which the tibia flexes and extends. A third longitudinal axis in the tibia (*vertical orange line*) about which the tibia rotates on the femur internally and externally is oriented perpendicular to both transverse axes in the femur.

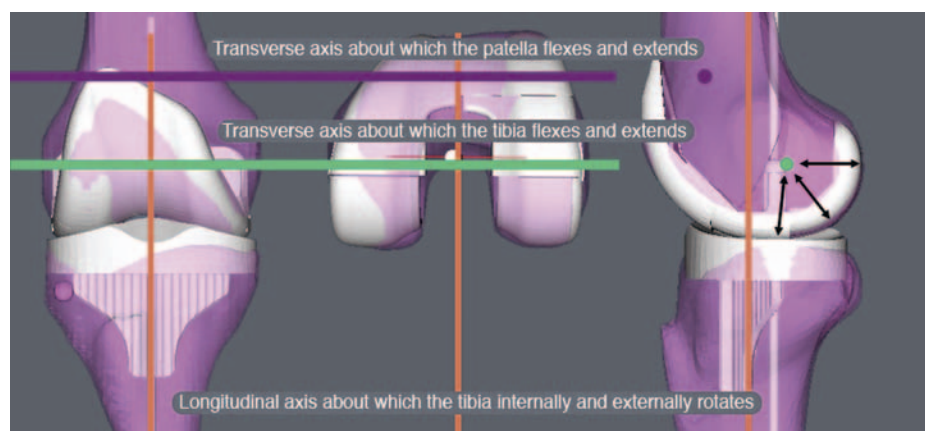


Figure 121-2. Single-radius femoral component of a right knee (*silver*) shape-matched to the femur of a normal knee model (*pink*). Shape matching the femoral component to the femur is the critical step in kinematically aligning the knee and in reestablishing the orthogonal interrelationships among the three kinematic axes. A kinematically aligned femoral component greatly simplifies the step-wise algorithm for identifying the correct options for restoring motion and balance to the knee before cementation of the components. The principle for kinematically aligning the tibial component to the femoral component is to align the anterior-posterior axis of the tibial component perpendicular to the transverse axis in the femur and femoral component. The principle for kinematically aligning the tibia to the tibial component is to accept the assumption that the internal-external rotational relationship between the femur and tibia is normal in a non-weight-bearing MRI scan and then center the tibia under the center of the tibial component.

the femur about which the tibia flexes and extends by the shape-matching step.^{1,7} The second step is to align the tibia to the tibial component kinematically, which is based on the assumption that the internal-external rotational relationship between the femur and tibia is normal in a magnetic resonance imaging (MRI) scan of the non-weight-bearing knee with end-stage osteoarthritis. The assumption that the internal-external rotational relationship is normal in the non-weight-bearing knee with end-stage osteoarthritis is inferred from the layer of joint fluid that is consistently seen separating the worn articular surface between the femur and tibia on the MRI scan of the knee. Both the layer of joint fluid and the image of a non-weight-bearing knee indicate that there is no contact between the worn femur and tibia and no transmission of force across the knee to malrotate the

tibia on the femur. The final step is aligning the center of the tibia under the center of the tibial component.

With a goal of improving on the 20% prevalence of patient dissatisfaction from mechanically aligned TKA with conventional and computer-assisted instruments,^{3,5} we began developing the method for performing kinematic alignment with patient-specific femoral and tibial cutting guides in 2005. We developed software that creates a three-dimensional model of the arthritic knee from a non-weight-bearing MRI or computed tomography (CT) arthrogram of the knee (OtisKnee, OtisMed, Alameda, Calif; <http://www.otismed.com>). Additional software transforms the arthritic knee model to a normal knee model and then kinematically aligns the components by shape-matching the best-fitting femoral and tibial components to the normal

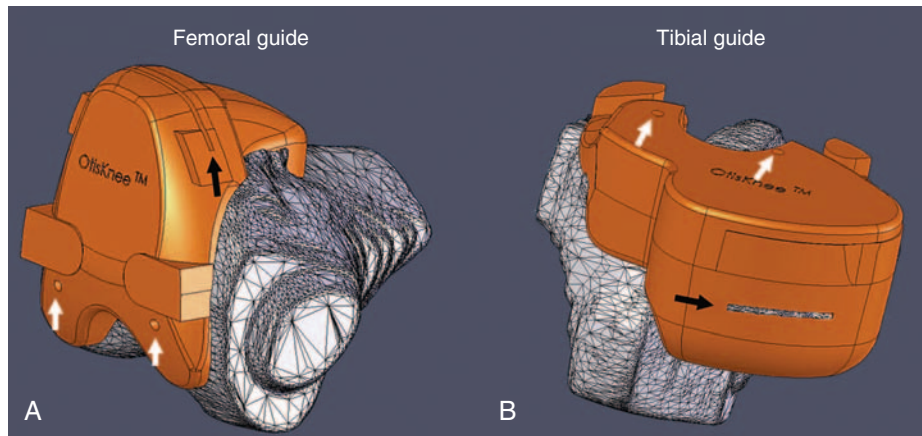


Figure 121-3. Femoral (A) and tibial (B) patient-specific cutting guides (orange) on the arthritic knee model (right knee). The saw slot (black arrow) in each guide sets the proximal-distal, flexion-extension, and varus-valgus degrees of freedom of each component. The two holes (white arrows) in each guide set the internal-external rotation, anterior-posterior, and medial-lateral degrees of freedom of each component.

knee model. The three-dimensional position of each component is then transferred from the normal knee to the arthritic knee model. Patient-specific cutting guides that incorporate the cut planes of each component and that reference the arthritic knee model are made to fit the patient's femur and tibia (Fig. 121-3). The cutting guides are used intraoperatively to transfer the six degrees of freedom (6DOF) positions of the femoral and tibial components from the computer to the patient—varus-valgus, internal-external rotation, flexion-extension, anterior-posterior, proximal-distal, and medial-lateral.^{13,14,16,25}

The first use of patient-specific cutting guides to align a TKA kinematically was in January 2006. As of August 2009, 23,000 kinematically aligned TKAs had been implanted with patient-specific cutting guides nationwide with the lead author (SMH) implanting over 700. From September through December 2009, he implanted 116 kinematically aligned TKAs with unconventional use of conventional instruments instead of patient-specific cutting guides. This 4-year developmental and clinical experience, which is admittedly limited in terms of long-term follow-up, forms the basis for the concepts shared in this chapter with the primary goals of stimulating debate and advancing the understanding of kinematic alignment of total knee arthroplasty.

ADVANTAGES OF KINEMATIC ALIGNMENT OVER MECHANICAL ALIGNMENT

Studies from the United Kingdom and Canada that reviewed more than 10,000 patients at 1 year following mechanically aligned TKA with conventional instruments and contemporary components have shown that one of five patients are not satisfied because of continued pain and poor function in activities of daily living (ADLs).^{3,5} The use of computer-assisted surgery has improved the mechanical alignment compared with conventional surgery, but has not improved the clinical outcome (much to the dismay of proponents of computer-assisted surgery).^{2,9,21,26} Therefore, a mechanically aligned TKA, whether performed with conventional instruments or computer assistance, has an unacceptably high prevalence of continued pain, poor function in ADLs, and

patient dissatisfaction, which means that there is ample room for improvement.

For the kinematics of a TKA to be the same as a normal knee, the three-dimensional placements of the femoral and tibial components have to be chosen so that the orientation of the three kinematic axes is unchanged from that of the normal knee. None of these axes can be found by referencing the transepicondylar axis, center of the femoral head, and center of the ankle with the use of conventional or computer-assisted instruments.^{1,10,15} There is a 5-degree average difference (range, 2 to 11 degrees) between the transepicondylar and primary transverse axes in the femur about which the tibia flexes and extends, which means that referencing the transepicondylar axis substantially changes the joint line from normal in the axial plane.¹¹ Of normal subjects, 98% do not have a neutral hip-knee-ankle axis because the longitudinal shape of the femur and tibia are unrelated and variable among subjects, which means that referencing the center of the femoral head and of the ankle changes the joint line in the coronal plane.¹² Changing the joint line of the femur from normal in the axial and/or coronal planes using instruments that align components to the transepicondylar axis, center of the femoral head, and center of the ankle kinematically malalign the knee and may explain the midrange instability reported in TKA (Fig. 121-4).⁷ Because mechanical alignment kinematically malaligns the knee, we hypothesized that kinematic alignment would reduce the high prevalence of persistent pain, poor function in ADLs, and patient dissatisfaction after mechanically aligned TKA with conventional and computer-assisted instruments.^{16,25}

PLANNING KINEMATIC ALIGNMENT WITH PATIENT-SPECIFIC CUTTING GUIDES

Protocol for Aligning and Performing Magnetic Resonance Imaging of the Knee

For kinematic alignment, the projection of the knee in the MRI scan has to be customized to the patient's knee position in the MRI scanner so that the oblique sagittal image plane

is perpendicular to the primary axis in the femur about which the tibia flexes and extends. A patient that has a painful osteoarthritic knee should be allowed to choose a position for the leg that is comfortable so that he or she does not inadvertently move the knee during image acquisition and cause

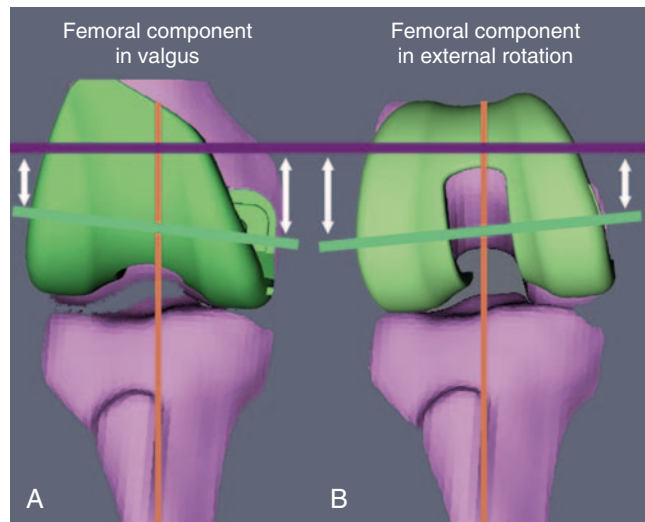


Figure 121-4. Illustration of how a femoral component not shape-matched to the articular surface of the normal knee in the coronal plane (A) or the axial plane (B) kinematically malaligns the knee. Placing the femoral component in more valgus (or varus) than normal (A) tilts the transverse axis in the femoral component (green line) so that it is no longer parallel to the primary transverse axis in the femur about which the patella flexes and extends (magenta line), nor is it perpendicular to the longitudinal axis in the tibia (orange), which kinematically malaligns the movement of the patella on the femur and the tibia on the femur. Placing the femoral component in more external rotation (or internal rotation) than normal (B) tilts the transverse axis in the femoral component (green line) so that it is no longer parallel to the transverse axis in the femur nor is it perpendicular to the longitudinal axis in the tibia (orange), which kinematically malaligns the movement of the patella on the femur and the tibia on the femur. Tilting the femoral component in just one plane or in opposite directions in the coronal and axial planes creates an uncorrectable ligament imbalance (white arrows). In this right knee, valgus positioning of the femoral component loosens the lateral side in extension (A) and external rotation of the femoral component worsens the ligament balance by tightening the lateral side in flexion (B). The only way to maintain ligament balance throughout the motion arc is to shape-match the femoral component to the femur.

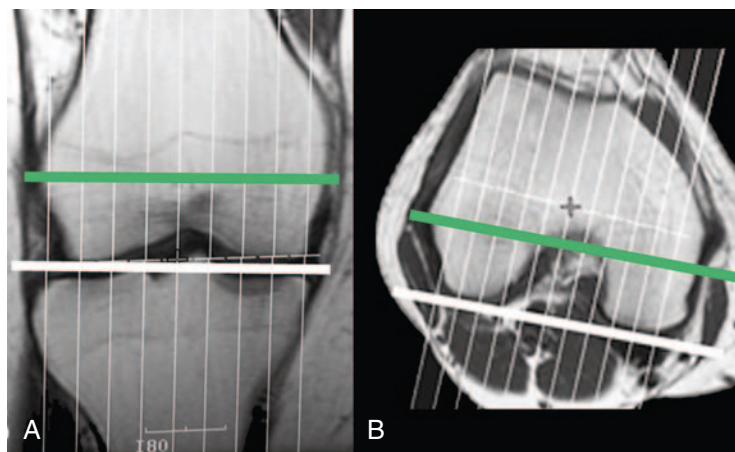
a motion artifact. The knee with a severe varus or valgus deformity or flexion contracture can be successfully imaged without forcing the knee into extension or an uncomfortable rotation by customizing the projection of the knee in the coronal and axial planes.

The following are contraindications for MRI of the knee for patient-specific cutting guides: (1) presence of a pacemaker; (2) movement of the knee during image acquisition because of inability to follow instructions, tremor, and claustrophobia; (3) obese knee that prevents the use of a dedicated knee coil; (4) hardware about the knee that distorts the image and subsequent three-dimensional model; and (5) metal in the body that might move in the magnetic field (e.g., brain aneurysm clips, metal in the eye, shrapnel near vital structures).

The following is a description of the suggested MRI technique, which relies on the use of coronal and axial locator images to obtain nonorthogonal, oblique, sagittal images perpendicular to the primary transverse axis in the femur about which the tibia flexes and extends (Fig. 121-5).¹⁴ A nonorthogonal, oblique, sagittal MRI scan of the treated knee is obtained using a 1.5- or 3.0-T scanner and dedicated knee coil. The plane for the nonorthogonal, oblique, sagittal scan is based on the use of coronal and axial locator images. These images are used to align the image plane perpendicular to the primary transverse axis in the femur about which the tibia flexes and extends, which projects the femoral condyles approximately in the same plane that the tibia flexes and extends about the femur. Coronal, axial, and sagittal high-resolution locator images are obtained using a 4-mm slice thickness, 1-mm spacing/gap, 256 × 128 matrix, one number of excitations (NEX), and 24-cm field of view (FOV), which yield nine slices in all three planes.

The locator image in the coronal plane that shows the largest projection of the distal femoral condyles is used to adjust the varus-valgus orientation of the plane of the nonorthogonal, oblique, sagittal scan. The nonorthogonal, oblique, sagittal scan plane is aligned perpendicular to a line connecting the cortical-cancellous bone interface of the distal femoral condyles on the locator image in the coronal plane. The locator image in the axial plane that shows the largest projection of the posterior femoral condyles is used to adjust the axial rotation of the plane of the nonorthogonal, oblique, sagittal scan. The nonorthogonal, oblique, sagittal

Figure 121-5. Illustration of the coronal (A) and axial (B) localizers, femoral joint line (thick white line), transverse axis in the femur about which the tibia flexes and extends (green line), and plane for the nonorthogonal, oblique, sagittal scan (thin parallel lines). Aligning the nonorthogonal, oblique, sagittal scan perpendicular to the distal femoral joint line (thick white line) in the coronal localizer and the posterior femoral joint line (thick white line) in the axial localizer aligns the nonorthogonal, oblique, sagittal scan perpendicular to the transverse axis in the femur about which the tibia flexes and extends (green line), which projects the femoral condyles as a circle in the same plane that the tibia flexes and extends about the femur.



scan plane is aligned perpendicular to a line connecting the cortical-cancellous bone interface of the posterior femoral condyles in the locator image in the axial plane. Because the contour of the posterior femoral condyles from 10 to 160 degrees forms a single radius of curvature, and because the primary transverse axis in the femur about which the tibia flexes and extends is equidistant from the distal and posterior articular surfaces of the femoral condyles, the femoral condyles are projected as circular in the nonorthogonal, oblique, sagittal imaging plane and perpendicular to the primary transverse axis in the femur about which the tibia flexes and extends.^{10,11,14}

A nonorthogonal, oblique, sagittal scan is then acquired of the knee, which is subsequently processed with software to generate a three-dimensional model of the knee. The scanning parameters are selected to provide contrast among fat, joint fluid, cartilage, degenerative and normal menisci, and subchondral, cancellous, and cortical bone. For a 1.5-T scanner and a dedicated knee coil (General Electric Medical Systems, Milwaukee, Wisc), we use these parameters: FRFSE PD, 30 to 35 TE, 2800 to 3400 TR, 31.25-Hz bandwidth, and minimum of two excitations using a 16-cm field of view centered at the joint line of the knee, 512 × 512 matrix, 2-mm slice thickness, with no spacing or gap. The length of each side of a pixel in the oblique sagittal image is 0.31 mm.¹⁴

Generation of Three-Dimensional Arthritic and Normal Knee Models

Kinematic alignment of the femoral and tibial components begins with a three-dimensional arthritic knee model generated from the MRI scans, from 44 to 60 slices, depending on the width of the knee (Fig. 121-6). Proprietary software segments the femur, tibia, articular cartilage, and osteophytes from each image and meshes the images together to form a

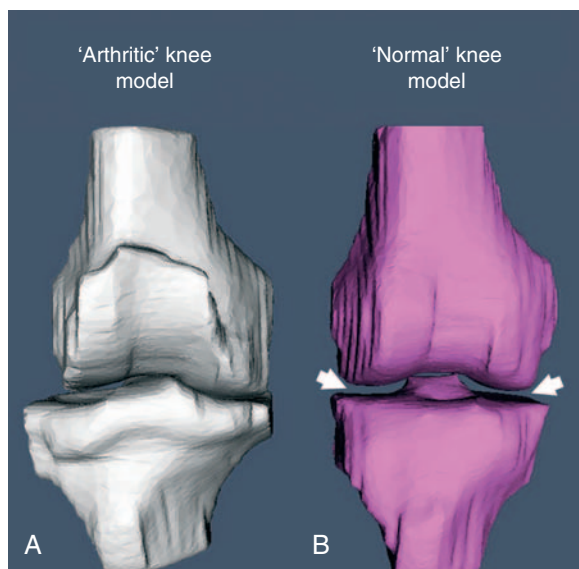


Figure 121-6. Illustration of the arthritic knee model (A) and normal knee model (B) created with software from an MRI scan of the knee. The software creates the normal knee model from the arthritic knee model by removing osteophytes, filling in worn joint surfaces, centering the tibia under the femur, and reestablishing an equal medial and lateral joint space (white arrows).

three-dimensional model of the arthritic knee (OtisMed). A series of steps is applied to the arthritic knee model to create a normal knee model. The articular surface of the arthritic knee model is transformed into a knee with a normal articular surface by filling articular defects. Osteophytes are removed to restore ligament length and restore a normal shape to the knee. The normal knee model is then aligned in the coronal plane by adjusting the varus-valgus rotation and proximal-distal position of the tibia until the distance between the femoral and tibial articular surfaces is equal medially and laterally.^{13,16} This process of creating a normal knee from an arthritic knee by filling defects, removing osteophytes to restore ligament length, and reestablishing a symmetrical medial-lateral joint space borrows from the well-established principles used to align the mobile-bearing unicompartmental knee replacement (i.e., Oxford Knee).

Shape-Matching Femoral and Tibial Components

The three-dimensional model of the femoral and tibial component that best fits the normal knee model is selected by proprietary software (see Fig. 121-2). Algorithms shape-match the femoral component to the restored articular surface of the femur in the normal knee model from 10 to 160 degrees, which kinematically aligns the femoral component by coaligning the transverse axis of the femoral component with the primary transverse axis in the femur about which the tibia flexes and extends. The internal-external rotation of the anterior-posterior axis of the tibial component is set perpendicular to the transverse axis of the femur and femoral component, which kinematically aligns the tibial component to the femoral component. The tibia is centered under the tibial component, which kinematically aligns the tibia to the tibial component.^{1,7,10,12} In theory, kinematic alignment restores the normal parallel and perpendicular interrelationship among the three kinematic axes of the prearthritic knee.¹⁴

Function, Design, and Machining of Patient-Specific Cutting Guides

A common function of all patient-specific cutting femoral and tibial cutting guides, whether they are made to align the TKA kinematically or mechanically, is to transfer the position of each component in three-dimensional space accurately from the computer to the operating room (see Fig. 121-3). Each cutting guide sets 6DOF positions of the component in three-dimensional space, which is comprised of three rotations—flexion-extension, varus-valgus, and internal-external—and three translations—(proximal-distal, anterior-posterior, and medial-lateral). When osteophyte removal changes the dimensions of the femur and tibia, the surgeon has the option to adjust the medial-lateral position of the femoral and tibial components visually.

The patient-specific cutting guides are designed to be small enough to fit in the knee using minimally invasive incisions, yet large enough to register enough knee topography so that the surgeon accurately seats the guide in the intended position. In the event that a cutting guide is inadvertently dropped on the floor, the guide must be sturdy enough to avoid breakage and retain its cavity shape during resterilization with heat. Rapid manufacturing is required to make the

production of patient-specific cutting guides cost-effective and to limit the turnaround time between receiving the MRI scan and shipping the finished guides. Currently, the turnaround time varies from 10 to 20 business days, depending on the manufacturer, but with future technologic improvements, might only be 1 day.

Patient-specific femoral and tibial cutting guides are machined to fit the arthritic knee model using a biocompatible plastic (polyoxymethylene [POM], Delrin). The cut planes corresponding to the positions of the femoral and tibial components in the normal knee model are transferred to the arthritic knee model. There is one saw slot and four holes for fixation pins in each guide (see Fig. 121-3). The saw slot sets the proximal-distal, flexion-extension, and varus-valgus degrees of freedom of each of the femoral and tibial components. The two pinholes on the articular surface of each guide set the anterior-posterior and internal-external rotation degrees of freedom of each of the femoral and tibial components. The two pinholes on the articular surface of each guide are used to pin the guide to the knee and also reference the conventional chamfer block and tibial component alignment instrument. The two pinholes on the anterior surface of each guide are used to pin the guide to the knee; they also accept the conventional distal femoral and proximal tibial cutting guides for the surgeon who prefers to use the conventional cutting block instead of the saw slot in the patient-specific guide. Hence, each guide provides the surgeon with the size and position of the femoral and tibial components and efficiently and accurately transfers the 6DOF position of each component from the computer to the patient.*

*References 1, 2, 6, 7, 9, and 13.

ALGORITHM FOR RESTORING MOTION AND BALANCING THE KINEMATICALLY ALIGNED TOTAL KNEE ARTHROPLASTY

The algorithm for determining the stepwise corrections to restore motion and balance to the knee before cementation of the components is greatly simplified by first aligning the femoral component kinematically (Fig. 121-7). Kinematic alignment of the femoral component is confirmed intraoperatively by comparing the symmetry of the thickness of the distal medial, distal lateral, posterior medial, and posterior lateral femoral bone resections after measuring the thickness of the resections with calipers and after correcting for cartilage wear, bone wear, and saw blade kerf. After correction, the thickness of each bone resection should equal the thickness of the condyle of the femoral component. For example, if a femoral component 8 mm thick and a saw blade 1.25 to 1.37 mm thick are used, then each bone resection should be 6.5 mm thick when there is no cartilage wear or bone wear.

Predicting the thickness of each bone resection is more complicated in the arthritic femur in which there is preexisting focal cartilage wear (typically, 1 to 2 mm) and occasionally bone wear (usually no more than 1 mm). The resection thickness can be predicted preoperatively from a biplanar, rotationally controlled MRI scan, which is carefully viewed to reveal the location and amount of wear (Fig. 121-8).¹⁴ After selecting the image that projects the largest radius of each femoral condyle using image analysis software (OsiriX DICOM Viewer, Dicom Solutions, Irvine, Calif; www.osirix-viewer.com), the thickness of the cartilage on the distal and posterior surface of the unworn and worn condyles is measured in millimeters. The difference in thickness between the worn and unworn condyle is computed in millimeters and

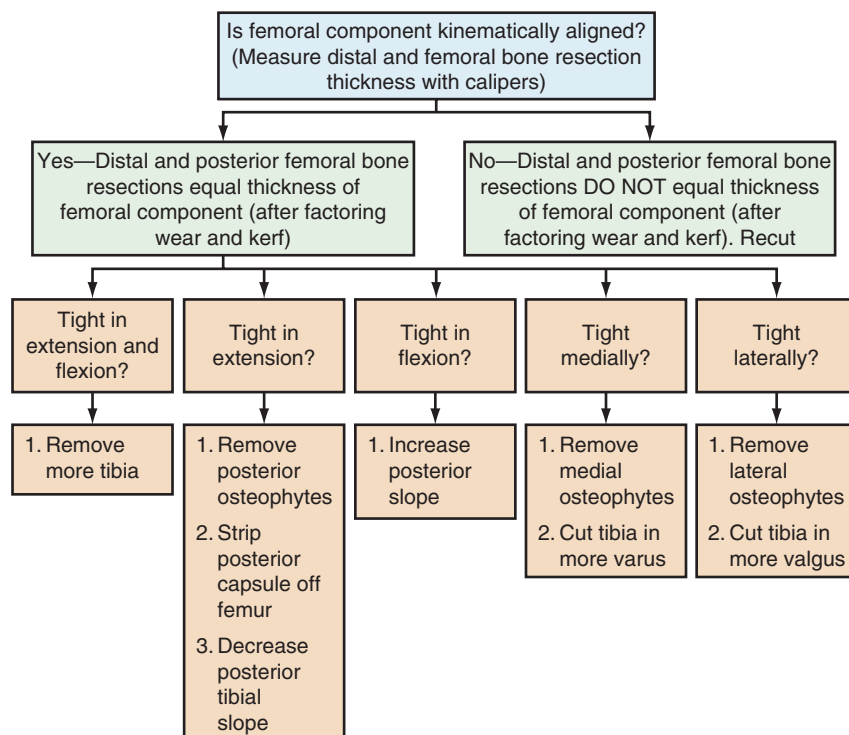


Figure 121-7. Algorithm for restoring motion and balancing the kinematically aligned TKA.

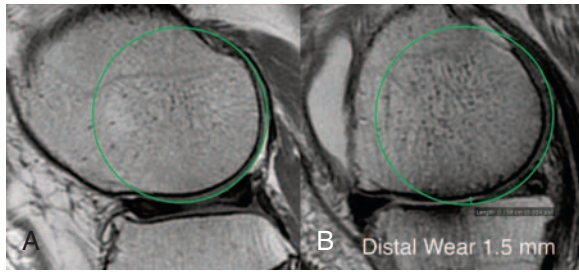


Figure 121-8. Illustration of a circle fit to the unworn lateral femoral condyle (A) and worn medial femoral condyle (B). On the medial side, the wear on the distal medial femoral condyle measures 1.5 mm and there is no wear on the posterior medial femoral condyle. For an 8-mm-thick femoral condyle, the thickness of the distal medial resection should be 5 mm and the thickness of the posterior medial, distal lateral, and posterior lateral resection should be 6.5 mm. The femoral component is kinematically aligned when the thicknesses of each femoral resection are equal and equal to the thickness of the femoral component, after correcting for cartilage wear, bone wear, and saw blade kerf.

used to determine the location and amount of correction needed for the worn condyle.

In a varus osteoarthritic knee, which typically has 2 mm of distal and 1 mm of posterior cartilage wear, the distal medial resection should be 4.5 mm thick and the distal lateral resection should be 6.5 mm, which give a 2-degree correction in the coronal plane (Fig. 121-9). The posterior medial resection should be 5.5 mm thick and the posterior lateral resection should be 6.5 mm thick, which gives a 1-degree correction in the axial plane. If the planned and executed cuts do not match, fine adjustments in the varus-valgus, internal-external rotation, proximal-distal, and anterior-posterior positions of the femoral component should be made. Accounting for cartilage wear, bone wear, and saw blade kerf when selecting the distal and posterior cut planes is needed to correct coronal and axial malrotation. This is also needed to set the varus-valgus and internal-external rotation and flexion-extension, proximal-distal, anterior-posterior, and medial-lateral positions of the femoral component so that the femoral component is shape-matched to a restored articular surface. When a single-radius femoral component is used, shape-matching the femoral component to a restored articular surface on the femur coaligns the transverse axis of the femoral component with the primary transverse axis of the femur about which the tibia flexes and extends and kinematically aligns the knee.^{16,17}

Once the femoral component is kinematically aligned, all subsequent steps to restore motion and balance the knee are limited to just four options—removing osteophytes, adjusting the plane of the tibial cut, releasing the posterior capsule from the femur, and medializing or lateralizing the tibial component. To determine which options are needed to restore motion and balance the knee, the knee is examined with trial components with the aim of deciding whether the knee fully flexes and extends and whether anterior-posterior and varus-valgus stability are acceptable at 30-degree intervals, from full extension to flexion. If the knee lacks extension and lacks flexion but has anterior-posterior and varus-valgus stability throughout the motion arc, then remove more tibia. If the knee lacks extension but fully flexes and has anterior-posterior and varus-valgus stability throughout the motion arc, then

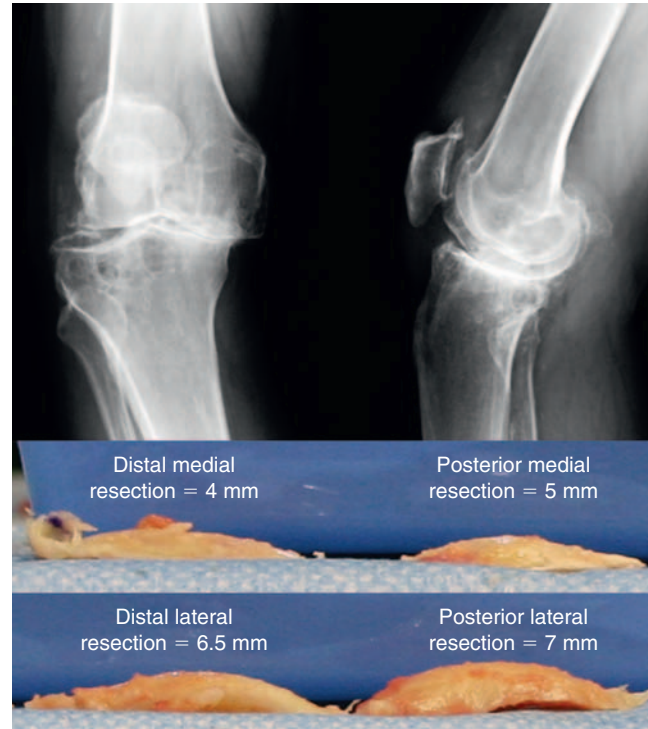


Figure 121-9. Illustration of a weight-bearing anteroposterior and lateral radiograph of a right knee with varus osteoarthritis (top) and the distal medial, posterior medial, distal lateral, and posterior lateral bone resections with their measured thickness in millimeters (mm; bottom). The distal medial resection is 4.5 mm thick and the distal lateral resection is 6.5 mm, which gives a 2-degree correction in the coronal plane. The posterior medial resection is 5 mm thick and the posterior lateral resection is 7 mm thick, which gives a 2-degree correction in the axial plane. To align an 8-mm-thick femoral component kinematically, each resection should be 6.5 mm thick after accounting for cartilage and bone wear and saw blade kerf, which is 1.25 to 1.5 mm thick, depending on the thickness of the saw blade.

remove posterior osteophytes and release the posterior capsule. If removal of the posterior osteophytes and releasing the posterior capsule are ineffective, decrease the posterior slope on the tibia.

We do not recommend additional resection of bone from the distal femur to restore extension unless the distal bone resection is 2 mm or more thinner than the posterior bone resection. The penalty from additional resection of bone from the distal femur is proximal movement of the femoral component, primary transverse axis of the femur, and joint line, which kinematically malaligns the knee and limits flexion.²⁴ If the knee lacks flexion but fully extends and has anterior-posterior and varus-valgus stability throughout the motion arc, then increase the posterior slope on the tibia. We have not found the need to recess or release the posterior cruciate ligament (PCL) to increase flexion. If the knee is tight medially throughout the motion arc, then remove all medial osteophytes. If the medial tightness persists after removing medial osteophytes from the tibia and femur, recut the tibia in 1 to 2 degrees more varus as long as the overall alignment of the limb will be acceptable. If the medial tightness persists after recutting, medialize the tibia on the tibial component and remove any bone from the tibia that extends beyond the tibial component¹⁹ (Fig. 121-10). If the knee is tight laterally

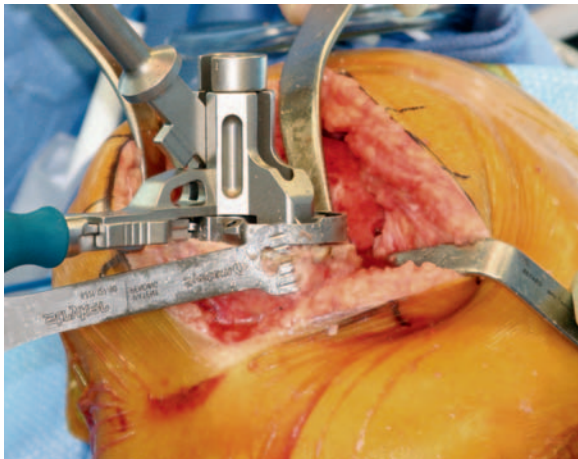


Figure 121-10. Intraoperative photograph of a right knee showing the tibia medialized on the trial base plate and a saw-trimming bone extending beyond the component to reduce medial tightness. The decision to medialize the tibia on the tibial component was made because of medial tightness that persisted after removing osteophytes from the medial femur and tibia, and after verifying that the plane of the varus-varus cut of the tibia was correct. This sequence of steps restores motion, stability, and alignment without releasing the medial collateral ligament in the knee with varus deformity caused by osteoarthritis.

throughout the motion arc, remove all lateral osteophytes. If the lateral tightness persists after removing lateral osteophytes from the tibia and femur, recut the tibia in 1 to 2 degrees more valgus as long as the overall alignment of the limb will be acceptable. If the PCL ligament is insufficient because of inadvertent release or incompetency and there is anterior-posterior and varus-valgus instability in 90 degrees of flexion but not in full extension, resect 2 mm of bone from the distal femur and use a 2-mm thicker liner. If the knee still has anterior-posterior and varus-valgus instability in 90 degrees of flexion, use a liner with an increased anterior slope or a posterior-stabilized component.

SURGICAL TECHNIQUES

Patient-Specific Cutting Guides

The range of motion and magnitude of varus-valgus deformity are assessed under anesthesia. A knee with a varus or valgus deformity is typically corrected by a thorough removal of medial or lateral femoral and tibial osteophytes, respectively.^{16,25} A knee with a flexion contracture of 10 degrees or more is typically corrected by removal of posterior osteophytes and posterior capsule release from the femur; this rarely requires additional resection of bone from the femur.²⁴

The operating room technician, circulating nurse, and surgeon should each cross-check the information etched on the patient-specific femoral and tibial cutting guides before anesthetizing the patient. Each guide has the name of the surgeon, patient initials and date of birth, component size, and an inscription of R or L, which indicates the side of the knee being operated on. The operating room technician and circulating nurse should also verify that they have sterilized the patient-specific cutting guides, correct subset of conventional instruments, and trial components that match the size determined by computer planning (Fig. 121-11). The use of

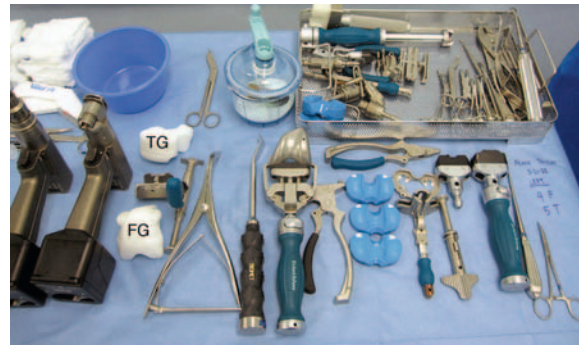

Figure 121-11. Photograph of the scrub table shows that one tray of instruments is needed to perform a kinematic TKA with patient-specific cutting guides. The patient-specific femoral guide (FG) and tibial guide (TG) are sterilized with the instruments and trial components that match the size of the components to be used, as determined by computer planning.

patient-specific cutting guides reduces the number of instrument trays from eight to one, which decreases operating time, room turnover time, and cost of processing instruments.¹⁶

A midvastus approach without patellar eversion gives an adequate exposure for using the patient-specific cutting guides. Fat is removed from the anterior surface of the femur proximal to the trochlear groove, as are any prominent osteophytes extending from the proximal trochlea. The patient-specific femoral guide is seated on the anterior cortex and trochlear groove, and centered mediolaterally on the distal femur (Fig. 121-12). The guide is secured with two articular and two anterior pins. The saw slot sets the varus-valgus, flexion-extension, and proximal-distal positions of the femoral component. The medial and the lateral distal pins are sequentially removed as the distal cut is made. Alternatively, the patient-specific femoral guide can be removed and the conventional distal femoral cutting guide can be placed over the two anterior pins, which allows visual assessment of the thickness of the distal resections before the cuts are made.

The thickness of each distal femoral resection is measured with a caliper. The symmetry between the distal resections is assessed using the stepwise algorithm and minor corrections are made when the symmetry is not correct. The chamfer guide from the conventional set of instruments that corresponds to the size of the femoral component determined by preoperative planning is inserted into the two articular pinholes. The chamfer guide sets the internal-external rotation, anterior-posterior, and medial-lateral positions of the femoral component. The two posterior femoral resections are made before the anterior and chamfer cuts, and the thickness of each resection is measured with calipers. The symmetry between the two posterior resections and between the two posterior and two distal resections is assessed using the algorithm, and minor corrections are made when the symmetry is not correct. An intramedullary alignment rod is not used because the wide variability in the longitudinal shape of the femur makes use of the center of the femoral head an unreliable landmark, and because referencing the center of the femoral head kinematically malaligns the knee.^{10,11,15}

The tibia is exposed by preserving the insertion of the PCL and by removing both menisci. With the tibia dislocated anteromedially, the patient-specific tibial guide is seated on the articular surface and anteromedial cortex of the tibia. The

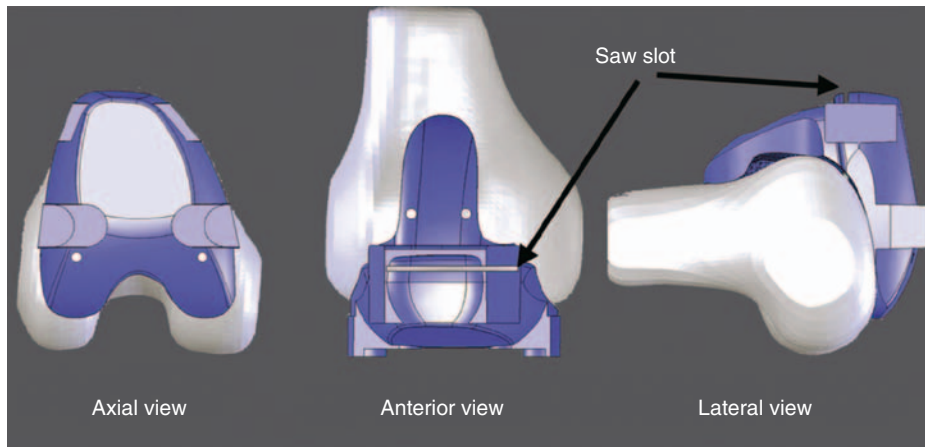


Figure 121-12. Illustration of the right knee showing axial, anterior, and lateral views of the patient-specific femoral guide on the normal knee model. The saw slot sets the varus-valgus, flexion-extension, and proximal-distal degrees of freedom of the femoral component. The axial view shows two articular pinholes through which pins are drilled to fix the femoral guide. After making the distal femoral resections, these two holes are used to position the conventional chamfer block, which sets the internal-external rotation, anterior-posterior, and medial-lateral positions of the femoral component. The anterior view shows two pinholes through which pins are drilled to fix the femoral guide. A conventional distal femoral cutting guide can be placed over these two pins to make the distal cut for the surgeon who wants to assess the thickness of each distal resection before making the cut.

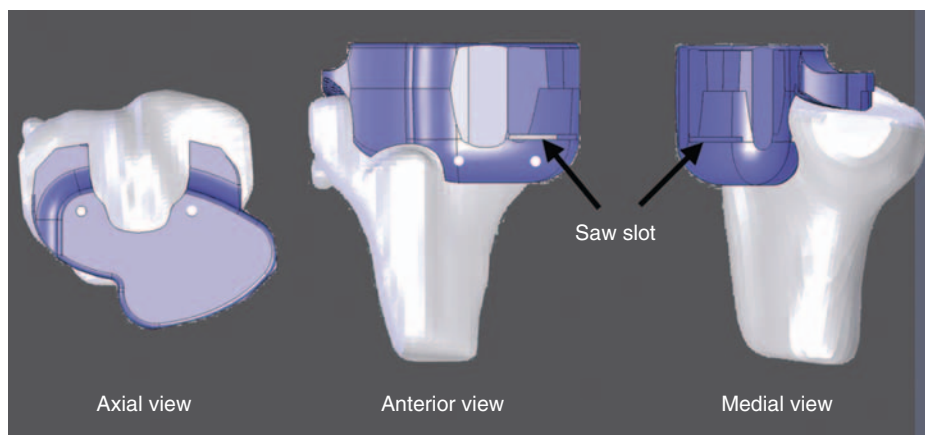


Figure 121-13. Illustration of a right knee showing axial, anterior, and medial views of the patient-specific tibial guide on the normal knee model. The saw slot sets the varus-valgus, flexion-extension, and proximal-distal position of the tibial component. The axial view shows two articular pinholes through which pins are drilled to fix the tibial guide. After making the tibial resection, these two holes are used to align the tibial positioning guide, which sets the internal-external rotation, anterior-posterior, and medial lateral positions of the tibial component. The anterior view shows two pinholes through which pins are drilled to fix the tibial guide. A conventional tibial cutting guide can be placed over these two pins for the surgeon who wants to assess the thickness and slope of the tibial resection before making the cut.

guide is secured with two articular and two anterior pins (Fig. 121-13). The medial and lateral articular pins are sequentially removed as the tibial cut is made. Alternatively, the patient-specific tibial guide can be removed and the conventional tibial guide can be placed over the two anterior pins to assess the thickness and slope of the tibial resection before making the cut. The medial-lateral thickness and anterior-posterior slope of the resected portion of the tibia are examined. The thickness of the worn side should be thinner than the unworn side by the amount of wear. After removing the resected portion of the tibia, the anterior-posterior slope of the proximal tibia should be neutral and conservative, which helps preserve the insertion of the PCL and tibial bone. A long-alignment rod is not used to check the varus-valgus

orientation of the tibial cut because the wide variability in the longitudinal shape of the tibia makes the use of the center of the ankle an unreliable landmark, and because referencing the center of the ankle kinematically malaligns the knee.¹⁵

The trial reduction is used to assess the range of motion and anterior-posterior and varus-valgus stability at 30-degree intervals, from full extension to flexion. Any loss of motion, instability, or tightness is noted and corrected using the algorithm. Correction of a flexion contracture rarely requires additional resection of distal femur as long as the sequence of removing posterior osteophytes, stripping the posterior capsule from the femur, and ensuring that the tibial cut is neutral and not sloped posteriorly is followed.²⁴ The sequence of complete removal of medial osteophytes, moving the tibia

medially on the tibial component and removing more medial tibia,²² and cutting the tibia in 1 to 2 degrees of varus corrects almost all knees with varus deformity and medial tightness without releasing the medial ligaments. The sequence of complete removal of lateral osteophytes (and, if necessary, then recutting the tibia in 1 to 2 degrees of valgus) corrects almost all knees with valgus deformity and lateral tightness without releasing the medial ligaments.¹⁶ The step of ensuring that the tibial cut is neutral and not anteriorly sloped corrects most knees with loss of flexion.

The articular pinholes made by drilling through the tibial guide are used to set the internal-external rotation of the tibial component on the tibia. We prefer to use the articular pinholes to set internal-external rotation because of the following factors: (1) medial-lateral location of the tibial tubercle is an inconsistent landmark (ranges 32 to 47 mm from the medial tibia); (2) the range of movement or floating trial technique, which allows the tibial component to orient itself in the best position relative to the femoral component gives widely variable results; and (3) registration of anatomic landmarks with conventional and computer-assisted techniques is not repeatable.^{18,23} The tibial template, corresponding to the size of the tibial component, is aligned with the articular pinholes. Small, 1- to 2-mm medial-lateral and anterior-posterior translation adjustments may be required to center the tibia on the tibial component. In the varus knee, moving the tibia medially on the tibial component and removing more medial tibia is effective for restoring coronal alignment and eliminating medial tightness.²²

Unconventional Use of Conventional Instruments

In September 2009, the OtisMed patient-specific cutting guides became unavailable in the United States because of a U.S. Food and Drug Administration (FDA) classification issue. Accordingly, the senior author (SMH) developed a

method to align the knee kinematically using a preoperative rotationally controlled MRI scan and using conventional total knee arthroplasty instruments unconventionally. We term this procedure *manual kinematic alignment* because the cut planes are selected and assessed manually without using patient-specific cutting guides.

Manual kinematic alignment requires preoperative planning to determine the location and amount of cartilage and bone wear on the femur. The thickness of each femoral bone resection is predicted by measuring the amount of cartilage and bone wear in millimeters from a nonorthogonal, oblique, sagittal MRI scan (see Fig. 121-8). A knee with end-stage varus osteoarthritis typically has 2 mm of distal wear and 1 mm of posterior wear confined to the medial femoral condyle; a knee with end-stage valgus osteoarthritis typically has 2 mm of distal wear and 2 mm of posterior wear confined to the lateral femoral condyle.

The surgical technique for manual kinematic alignment is the same as the surgical technique for kinematic alignment with patient-specific guides, regarding exposure, assessing and correcting motion, and addressing tightness and instability. The principle for kinematically aligning the femoral component is to remove the correct amount of bone and cartilage from the distal and posterior femur after accounting for wear and saw blade kerf, so that the total thickness of the missing and removed tissue matches the thickness of the femoral component. The location for the distal femoral cut is selected by manually positioning the conventional femoral guide on the distal surface of the femur, just posterior to the apex of the notch, without using an intramedullary rod (Fig. 121-14). The intramedullary rod is not used because it can kinematically malalign the femoral component because of the longitudinal shape of the femur being variable among subjects.⁷

The conventional femoral guide is placed flush on the unworn side and pinned, and then the guide is manually raised away from the worn side according to the thickness of the wear (typically, 2 mm) and pinned. The proximal-distal

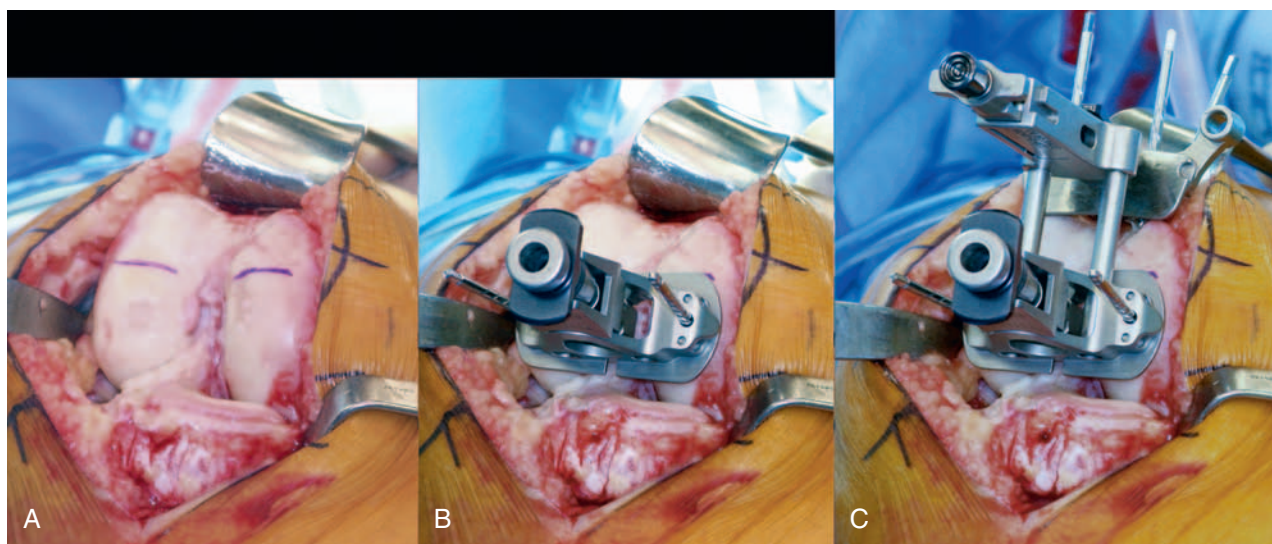


Figure 121-14. Photographs of a right knee showing the distal femur with the anterior boundary of the notch marked by blue lines (A), the conventional distal femoral guide pinned to the femur posterior to the anterior boundary of the notch (B), and the cutting guide attached to the conventional distal femoral guide (C). The conventional femoral guide is placed flush on the unworn side and manually raised away from the worn side according to the thickness of the wear (typically, 2 mm) and pinned.

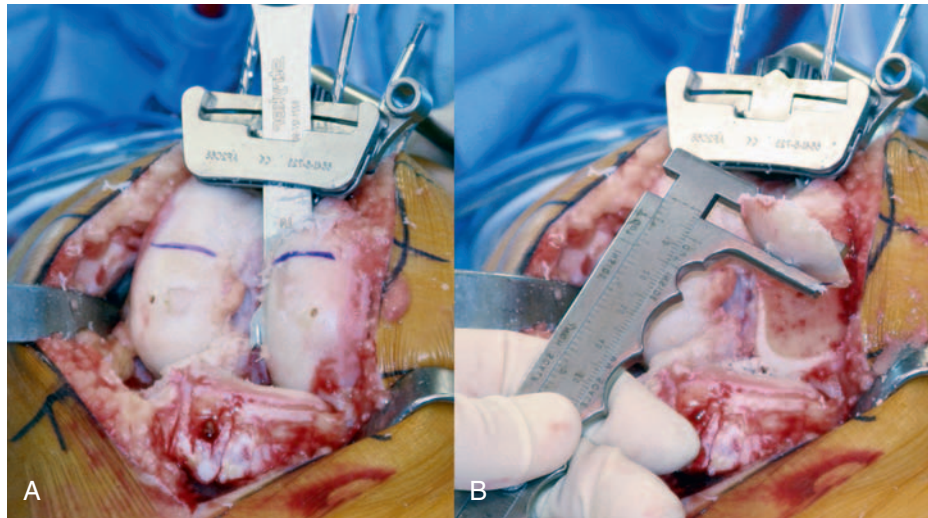


Figure 121-15. Photographs of a right knee showing the distal medial resection (A) and the caliper measurement of the thickness of the resection (B). The thickness of each distal femoral resection should be 6.5 ± 1 mm thick after correcting for cartilage wear, bone wear, and saw blade kerf.

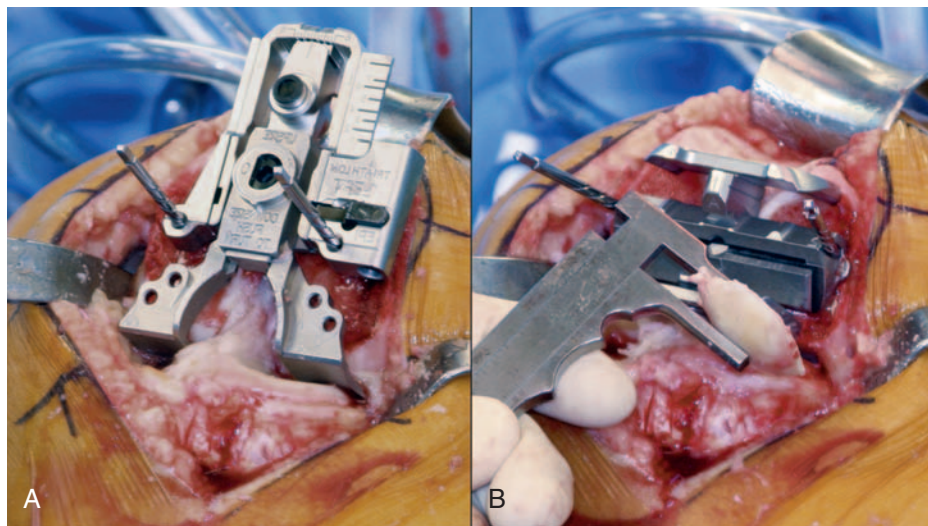


Figure 121-16. Photographs of a right knee showing the positioning of the conventional posterior referencing guide set at 0 degrees of rotation (A) and the caliper measurement of the posteromedial resection (B). Each posterior femoral resection should be 6.5 ± 1 mm thick after correcting for cartilage wear, bone wear, and saw blade kerf. Small internal-external rotational adjustments can be made without compromising the fit of the femoral component if the posterior resections are made and measured before making the anterior and chamfer resections.

setting on the proximal extension of the conventional femoral guide is set to match the thickness of the femoral component and the cutting block portion is pinned to the anterior surface of the femur. The distal femoral resection is made, and each distal bone resection is measured with calipers (Fig. 121-15). The worn side should be 4 to 5 mm thick and the unworn side should be 6 to 7 mm thick when an 8-mm thick femoral component is used. A parallel cutting guide is used to adjust the thickness of the distal femoral cut when the difference between the predicted and actual thickness of each distal resection is 2 mm or more. The location for the posterior femoral cut is selected with the conventional posterior referencing guide set at neutral rotation. The conventional posterior referencing guide is placed flush on the

unworn side and pinned. The guide is then manually raised away from the worn condyle equal to the amount of wear (typically, 1 to 2 mm) and pinned (Fig. 121-16). The chamfer block matching the size of the best-fitting femoral component is placed in the pinholes. The posterior cuts are made before making the anterior and chamfer cuts, and each posterior resection is measured with calipers. The worn side should be 4 to 5 mm thick and the unworn side 6 to 7 mm thick. If the difference between the predicted and actual thickness of each distal resection is 2 mm or more, the internal-external rotation and anterior-posterior positions of the chamfer guide are adjusted to correct the posterior femoral cut.

The principle for kinematically aligning the tibial component is to set the tibial cut plane so that the worn side of the

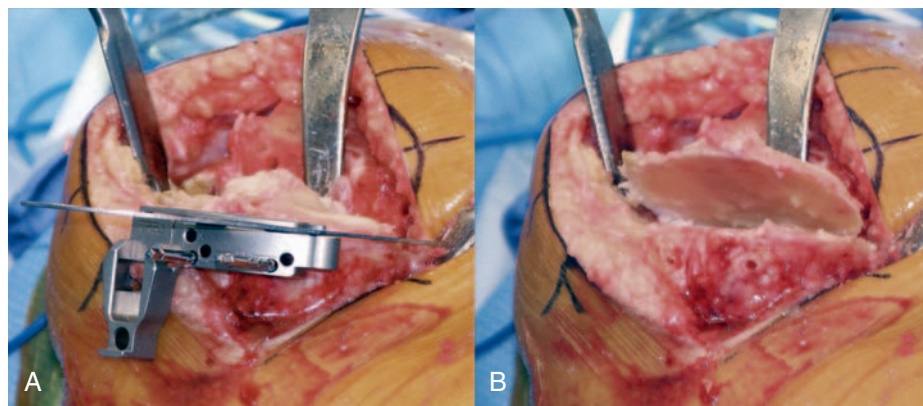


Figure 121-17. Photographs of a right knee showing the positioning of the conventional tibial cutting guide with an angel wing placed in the slot to assess the proximal-distal and anterior-posterior slopes of the tibial cut (**A**). The plane of the conventional tibial cutting guide is manually positioned so that the proximal-distal location of the tibial cut plane is conservative and the anterior-posterior slope of the tibial cut plane is neutral. The varus-valgus orientation of the tibial cut plane is adjusted until the worn side of the resected portion of the tibia is thinner than the unworn side by the amount of wear. **B**, The conservative tibial resection shows that more anterior bone is removed than posterior bone, which places the tibial component in neutral slope and preserves the insertion of the posterior cruciate ligament.

resected portion of the tibia is thinner than the unworn side by the amount of wear, and the anterior-posterior slope is neutral and conservative, which helps preserve the insertion of the posterior cruciate ligament. An angel wing is placed in the slot of the conventional tibial cutting guide (Fig. 121-17). The plane of the conventional tibial cutting guide is manually positioned so that the proximal-distal location of the tibial cut plane is conservative and the anterior-posterior slope of the tibial cut plane is neutral. One pin is placed in the conventional tibial cutting guide, which sets the proximal-distal and anterior-posterior slopes. The varus-valgus orientation of the tibial cut plane is adjusted by rotating the conventional tibial cutting guide until the worn side of the resected portion of the tibia is thinner than the unworn side by the amount of wear. The conventional tibial cutting guide is pinned to the tibia and the tibial cut is made. A long-alignment rod is not used to check the varus-valgus orientation of the tibial cut because the wide variability in the longitudinal shape of the tibia makes the use of the center of the ankle an unreliable landmark, and because referencing the center of the ankle kinematically malaligns the knee.⁷ The alignment of the limb is visually inspected during the trial reduction and varus-valgus adjustments of the tibial resection are made if the limb appears malaligned.

THEORETICAL CONCERNS

One theoretical concern is whether the hip-knee-ankle axis of the kinematically aligned TKA is different from a TKA mechanically aligned with conventional and computer-assisted instrumentation. A source of this concern was a pilot study, in September 2006, of four knees treated with patient-specific cutting guides at the request of an implant company to evaluate the first-time use of their knee component before commercial release. The authors of this pilot study suggested that kinematically aligned knees were malaligned in the coronal plane.²⁰

Although the primary goal of kinematic alignment is to restore knee kinematics and not to restore a neutral or 0-degree hip-knee-ankle axis, two other studies have shown

that kinematic alignment does not malalign the limb in the coronal plane, as suggested by Klatt and associates²⁰ in their study of four subjects.¹⁶ One level III study, consisting of 21 subjects, found an average hip-knee-ankle axis of 1.2 degree varus,²⁵ which was closer to the 0-degree mechanical axis and had less fewer outliers outside the range of 0 ± 3 degrees than many previously reported results using conventional and computer-assisted techniques.²⁵ A second level III study, consisting of 48 subjects, found an average hip-knee-ankle axis of 1.4 degrees valgus, which is within the range of 0 ± 3 degrees. A level I prospective, double-blinded, randomized clinical trial is underway to further clarify the differences in limb alignment between the kinematically aligned knee with patient-specific cutting guides and mechanical alignment with conventional instruments.⁸ However, on the basis of these level III studies, the hip-knee-ankle axis of the kinematically aligned TKA is similar to that of conventional and computer-assisted techniques.

Although there is a widely held opinion that a neutral hip-knee-ankle axis will result in better TKA survivorship, the mid- or long-term scientific support for this contention is surprisingly weak. Every study that has been considered evidence to support this contention is limited for various reasons. Six of seven published studies used short-leg radiographs, which cannot accurately assess the hip-knee-ankle axis.^{15,27} In the one study that used long-leg radiographs, a rudimentary implant design consisted of a noncondylar roller and trough design that was implanted with primitive instrumentation (Denham Knee).^{2,23a} A recent study of the survivorship of a modern implant design with better instrumentation in 395 knees has shown that factors other than the mechanical axis are more important for determining survivorship at 15 years, which suggests that the surgical goal of restoring a 0-degree hip-knee-ankle axis should be revisited. The study indicated that the group with a hip-knee-ankle axis outside the range of 0 ± 3 degrees, which consisted of 25% of the knees, had a threefold better survivorship at 15 years than the group with a hip-knee-ankle axis inside the range of 0 ± 3 degrees, which consisted of 75% of the knees, a finding that starkly contrasts with the study of the Denham

Knee.² The better survivorship of so-called outliers, with modern implant design and modern instrumentation, might be the result of better balancing of the knee and restoration of normal kinematics. Studies have shown that release of the collateral ligaments is not needed with kinematic alignment,^{17,25} which may explain why kinematic alignment restores more normal contact kinematics than mechanical alignment, with the potential for better mid- and long-term survivorship.¹³

A second theoretical concern is whether the process of kinematic alignment that begins with performing MRI of the knee and ends with surgical implantation of the components consistently aligns the knee kinematically. There are many sources of error in the process, including the quality of the MRI image (i.e., proper biplanar alignment, high signal-to-noise ratio, no motion artifact), generation of the arthritic and normal knee models, shape fitting of the components, manufacturing the patient-specific cutting guides, and the surgeon using the guides in the operating room. Although some studies have shown that the process is reliable,^{16,17,25} we believe that there is still a need to follow the algorithm intraoperatively to verify that the actual and predicted thickness of each bone resection is correct and, when necessary, to make adjustments in component position before cementing.

EARLY CLINICAL BENEFITS

As of December 2009, the clinical experience with kinematic alignment spanned 4 years and comprised 23,000 knees, which is sufficient to determine whether there are any early clinical benefits or failures associated with kinematic alignment. We have prospectively used a handheld computer (OrthoSight, Conshohocken, Pa; www.orthosight.com) to eliminate interviewer bias that patients self-administer to respond to a survey of queries consisting of custom questions, Oxford score, Short Form Health Survey (12 items; SF-12), and Knee Society score. Patients spend an average of 8 to 10 minutes preoperatively and postoperatively filling out the survey in the waiting room, which has improved our office efficiency. The handheld computer is used intraoperatively to record operative time, ligament releases, bone recuts, guide fit, and whether the implanted component matches the size of the planned component.^{16,17}

The perioperative data suggest that kinematic alignment may lessen the surgical stress experienced by the patient, shorten the recovery time, and increase the rate of return to ADLs. The average operative duration of 53 minutes is less than the average reported operative times for conventional (73 minutes) and computer-assisted (90 minutes) approaches.^{16,25,26} Currently, our average operative duration is 30 minutes with patient-specific cutting guides and 36 minutes with the unconventional use of conventional instruments. Transfusions are infrequent, which is attributed to not releasing collateral and retinacular soft tissue releases. Fat emboli have not occurred because intramedullary rods are not used with either kinematic alignment technique. The hospital stay of 2 nights is short, with 98% of patients discharged to home rather than to a rehabilitation facility. At 4 to 5 weeks postoperatively, 80% of patients walk without a cane, 54% drive a car, 88% notice that their knee functions better than before surgery, 94% judge the treated knee as

normal or almost normal, and 98% judge the alignment of their limb as “just right.” In terms of patient response to standardized questionnaires, by 4 to 5 weeks patients experience less pain than before surgery and show significant improvements in 11 of 12 activities evaluated by the Oxford score, SF-12 physical score, knee function score, and Knee Society score.¹⁷ A level I prospective, double-blinded, randomized clinical trial is underway to clarify further the differences in early recovery between the kinematically aligned knee with patient-specific cutting guides and mechanical alignment with conventional instruments.⁸

SUMMARY

The primary goals of this chapter were to stimulate debate and advance the understanding of kinematic alignment of TKA. Kinematic alignment offers a much-needed alternative to mechanical alignment because mechanical alignment with conventional and computer-assisted techniques has a prevalence of patient dissatisfaction (20%) because of continued pain and poor function in ADLs. Kinematic alignment does not malalign the hip-knee-ankle axis. The early success of the kinematically aligned TKA (OtisKnee) has been recognized by the implant manufacturing industry. Most major implant manufacturers have since developed patient-specific cutting guides, but these guides align the limb mechanically and do not align the knee kinematically. As of the end of 2009, the available patient-specific cutting guides that mechanically align the limb are Signature (Biomet, Warsaw Ind), Visionaire (Smith & Nephew, Memphis, Tenn), Prophecy (Wright Medical Technology, Arlington, Tenn), and Tru-Match (DePuy Orthopaedics, Warsaw, Ind). We have recognized that there is a need for level I studies to clarify differences in limb alignment and early recovery between the kinematically aligned knee with patient-specific cutting guides and mechanical alignment with conventional and computer-assisted instruments, and we await the publication of the registered level I study that is currently underway.⁸ We also want to emphasize that level I studies are also needed to determine whether patient-specific cutting guides that mechanically align the limb improve on the high prevalence of patient dissatisfaction with mechanically aligned TKAs implanted with conventional and computer-assisted instruments.

KEY REFERENCES

- Alden KJ, Pagnano MW: Computer-assisted surgery: a wine before its time. *Orthopedics* 31:936–939, 2008.
- Baker PN, van der Meulen JH, Lewsey J, Gregg PJ: The role of pain and function in determining patient satisfaction after total knee replacement. Data from the National Joint Registry for England and Wales. *J Bone Joint Surg Br* 89:893–900, 2007.
- Coughlin KM, Incavo SJ, Churchill DL, Beynon BD: Tibial axis and patellar position relative to the femoral epicondylar axis during squatting. *J Arthroplasty* 18:1048–1055, 2003.
- Dossett GH: Total knee replacement study using standard cutting guide vs. Otismed MRI generated cutting guide, Phoenix, Ariz, 2010, Department of Veterans Affairs.
- Eckhoff D, Hogan C, DiMatteo L, et al: Difference between the epicondylar and cylindrical axis of the knee. *Clin Orthop Relat Res* 461:238–244, 2007.
- Eckhoff DG, Bach JM, Spitzer VM, et al: Three-dimensional mechanics, kinematics, and morphology of the knee viewed in virtual reality. *J Bone Joint Surg Am* 87(Suppl 2):71–80, 2005.

- Hollister AM, Jatana S, Singh AK, et al: The axes of rotation of the knee. *Clin Orthop Relat Res* 290:259–268, 1993.
- Howell SM, Hodapp EE, Kuznik K, Hull ML: In vivo adduction and reverse axial rotation (external) of the tibial component can be minimized. *Orthopedics* 32:319, 2009.
- Howell SM, Howell SJ, Hull ML: Assessment of the radii of the medial and lateral femoral condyles in varus and valgus knees with osteoarthritis. *J Bone Joint Surg Am* 92:98–104, 2010.
- Howell SM, Kuznik K, Hull ML, Siston RA: Results of an initial experience with custom-fit positioning total knee arthroplasty in a series of 48 patients. *Orthopedics* 31:857–863, 2008.
- Howell SM, Kuznik K, Hull ML, Siston RA: Longitudinal shapes of the tibia and femur are unrelated and variable. *Clin Orthop Relat Res* 468:1142–1148, 2010.
- Howell SM, Rogers SL: Method for quantifying patient expectations and early recovery after total knee arthroplasty. *Orthopedics* 32:884–890, 2009.
- Matziolis G, Krockner D, Weiss U, et al: A prospective, randomized study of computer-assisted and conventional total knee arthroplasty. Three-dimensional evaluation of implant alignment and rotation. *J Bone Joint Surg Am* 89:236–243, 2007.
- Smith C, Chen J, Howell SM, Hull ML: An in vivo study of the effect of distal femoral resection on passive knee extension. *J Arthroplasty* 25:1137–1142, 2010.
- Spencer BA, Mont MA, McGrath MS, et al: Initial experience with custom-fit total knee replacement: intra-operative events and long-leg coronal alignment. *Int Orthop* 33:1571–1575, 2009.

Full references for this chapter can be found on www.expertconsult.com.

REFERENCES

1. Akagi M, Oh M, Nonaka T, et al: An anteroposterior axis of the tibia for total knee arthroplasty. *Clin Orthop Relat Res* 420:213–219, 2004.
2. Alden KJ, Pagnano MW: Computer-assisted surgery: a wine before its time. *Orthopedics* 31:936–939, 2008.
3. Baker PN, van der Meulen JH, Lewsey J, Gregg PJ: The role of pain and function in determining patient satisfaction after total knee replacement. Data from the National Joint Registry for England and Wales. *J Bone Joint Surg Br* 89:893–900, 2007.
4. Barrack RL, Schrader T, Bertot AJ, et al: Component rotation and anterior knee pain after total knee arthroplasty. *Clin Orthop Relat Res* 392:46–55, 2001.
5. Bourne RB, Chesworth BM, Davis AM, et al: Patient satisfaction after total knee arthroplasty: who is satisfied and who is not? *Clin Orthop Relat Res* 468:57–63, 2010.
6. Burnett RS, Boone JL, Rosenzweig SD, et al: Patellar resurfacing compared with nonresurfacing in total knee arthroplasty. A concise follow-up of a randomized trial. *J Bone Joint Surg Am* 91:2562–2567, 2009.
7. Coughlin KM, Incavo SJ, Churchill DL, Beynon BD: Tibial axis and patellar position relative to the femoral epicondylar axis during squatting. *J Arthroplasty* 18:1048–1055, 2003.
8. Dossett GH: Total knee replacement study using standard cutting guide vs. Otismed MRI generated cutting guide, Phoenix, Ariz, 2010, Department of Veterans Affairs.
9. Dutton AQ, Yeo SJ, Yang KY, et al: Computer-assisted minimally invasive total knee arthroplasty compared with standard total knee arthroplasty. A prospective, randomized study. *J Bone Joint Surg Am* 90:2–9, 2008.
10. Eckhoff DG, Bach JM, Spitzer VM, et al: Three-dimensional mechanics, kinematics, and morphology of the knee viewed in virtual reality. *J Bone Joint Surg Am* 87(Suppl 2):71–80, 2005.
11. Eckhoff D, Hogan C, DiMatteo L, et al: Difference between the epicondylar and cylindrical axis of the knee. *Clin Orthop Relat Res* 461:238–244, 2007.
12. Hollister AM, Jatana S, Singh AK, et al: The axes of rotation of the knee. *Clin Orthop Relat Res* 290:259–268, 1993.
13. Howell SM, Hodapp EE, Kuznik K, Hull ML: In vivo adduction and reverse axial rotation (external) of the tibial component can be minimized. *Orthopedics* 32:319, 2009.
14. Howell SM, Howell SJ, Hull ML: Assessment of the radii of the medial and lateral femoral condyles in varus and valgus knees with osteoarthritis. *J Bone Joint Surg Am* 92:98–104, 2010.
15. Howell SM, Kuznik K, Hull ML, Siston RA: Longitudinal shapes of the tibia and femur are unrelated and variable. *Clin Orthop Relat Res* 468:1142–1148, 2010.
16. Howell SM, Kuznik K, Hull ML, Siston RA: Results of an initial experience with custom-fit positioning total knee arthroplasty in a series of 48 patients. *Orthopedics* 31:857–863, 2008.
17. Howell SM, Rogers SL: Method for quantifying patient expectations and early recovery after total knee arthroplasty. *Orthopedics* 32:884–890, 2009.
18. Ikeuchi M, Yamanaka N, Okanou Y, et al: Determining the rotational alignment of the tibial component at total knee replacement: a comparison of two techniques. *J Bone Joint Surg Br* 89:45–49, 2007.
19. Jeffery RS, Morris RW, Denham RA: Coronal alignment after total knee replacement. *J Bone Joint Surg Br* 73:709–714, 1991.
20. Klatt BA, Goyal N, Austin MS, Hozack WJ: Custom-fit total knee arthroplasty (OtisKnee) results in malalignment. *J Arthroplasty* 23:26–29, 2008.
21. Matziolis G, Krockner D, Weiss U, et al: A prospective, randomized study of computer-assisted and conventional total knee arthroplasty. Three-dimensional evaluation of implant alignment and rotation. *J Bone Joint Surg Am* 89:236–243, 2007.
22. Mihalko WM, Saleh KJ, Krackow KA, Whiteside LA: Soft tissue balancing during total knee arthroplasty in the varus knee. *J Am Acad Orthop Surg* 17:766–774, 2009.
23. Siston RA, Goodman SB, Patel JJ, et al: The high variability of tibial rotational alignment in total knee arthroplasty. *Clin Orthop Relat Res* 452:65–69, 2006.
- 23a. Parratte S, Pagnano MW, Trousdale RT, et al: Effect of postoperative mechanical axis alignment on the fifteen-year survival of modern, cemented total knee replacements. *J Bone Joint Surg* 92(12):2143, 2010.
24. Smith C, Chen J, Howell SM, Hull ML: An in vivo study of the effect of distal femoral resection on passive knee extension. *J Arthroplasty* 25:1137–1142, 2010.
25. Spencer BA, Mont MA, McGrath MS, et al: Initial experience with custom-fit total knee replacement: intra-operative events and long-leg coronal alignment. *Int Orthop* 33:1571–1575, 2009.
26. Stulberg SD, Yaffe MA, Koo SS: Computer-assisted surgery versus manual total knee arthroplasty: a case-controlled study. *J Bone Joint Surg Am* 88(Suppl 4):47–54, 2006.
27. van Raaij TM, Brouwer RW, Reijman M, et al: Conventional knee films hamper accurate knee alignment determination in patients with varus osteoarthritis of the knee. *Knee* 16:109–111, 2009.