

# Femoral bone and cartilage wear is predictable at 0° and 90° in the osteoarthritic knee treated with total knee arthroplasty

Denis Nam · Kenneth M. Lin · Stephen M. Howell ·  
Maury L. Hull

Received: 21 January 2014 / Accepted: 11 May 2014  
© Springer-Verlag Berlin Heidelberg 2014

## Abstract

**Purpose** Kinematically aligned total knee arthroplasty (TKA) positions the femoral component at the natural angle and level of the distal (0°) and posterior (90°) joint line. This technique applies referencing guides at 0° and 90° that are adjusted to compensate for wear and kerf and perform resections equal in thickness to the femoral component. Knowing whether femoral bone and cartilage wear is predictable would assist in establishing general guidelines for adjusting the resection level of these two referencing guides. This study tests the hypothesis that femoral bone and cartilage wear is predictable at 0° and 90° in the varus and valgus osteoarthritic knee treated with TKA.

**Methods** The study consists of 205 patients and 208 knees with Kellgren–Lawrence Grade 3 or 4 osteoarthritis and treated with a TKA. Each knee had a narrow slice (2 mm) preoperative 1.5 tesla magnetic resonance image in the sagittal plane. Femoral bone and cartilage wear at 0° and 90° was computed from best-fit circles superimposed on the peripheral boundary of the subchondral bone on the medial and lateral femoral condyles.

**Results** Overall, 99.5 % of knees had minimal bone wear (<1 mm) at 0° and 90°. In the 74 % (154 of 208) of knees with a varus deformity, 92 % at 0° and 2 % at 90° had >1 mm cartilage wear on the medial femoral condyle. In the 26 % (54 of 208) of knees with a valgus deformity, 78 % at 0° and 55 % at 90° had ≥1 mm cartilage wear on the lateral femoral condyle.

**Conclusions** As a general guideline, adjustment for femoral bone wear is rarely required when performing kinematically aligned TKA. Most osteoarthritic knees require adjustment of the distal referencing guide to compensate for cartilage wear on the medial femoral condyle in the varus knee and the lateral femoral condyle in the valgus knee. Adjustment of the posterior referencing guide is required in about half of valgus osteoarthritic knees to compensate for lateral cartilage wear at 90°. Knowing that bone wear is rare and cartilage wear is predictable in varus and valgus Kellgren–Lawrence Grade 3 or 4 osteoarthritic knees helps establish general guidelines for adjusting the distal and posterior femoral referencing guides to restore the natural angle and level of the femoral joint lines when performing kinematically aligned TKA with generic instruments.

**Level of evidence** IV.

**Keywords** Total knee arthroplasty · Kinematic alignment · Cartilage wear · Osteoarthritis

---

D. Nam · K. M. Lin  
Department of Orthopedic Surgery, Washington University  
School of Medicine/Barnes-Jewish Hospital, St. Louis, MO,  
USA

D. Nam (✉)  
Washington University Orthopedics, Barnes Jewish Hospital,  
660 S. Euclid Avenue, Campus Box 8233, St. Louis,  
MO 63110, USA  
e-mail: namd@wudosis.wustl.edu

S. M. Howell · M. L. Hull  
Biomedical Engineering Graduate Group, University of  
California, Davis, Davis, CA, USA

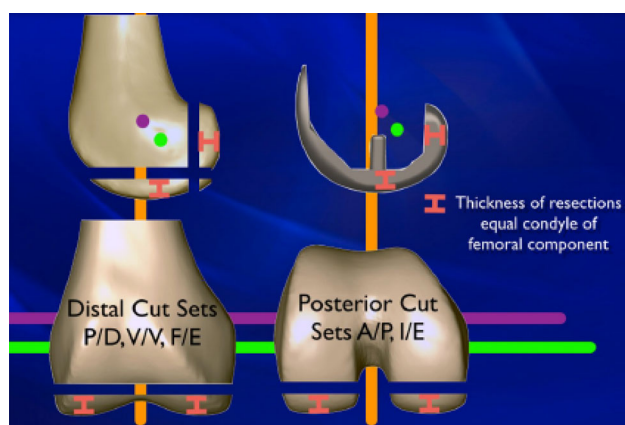
S. M. Howell · M. L. Hull  
Department of Mechanical Engineering, University of  
California, Davis, Davis, CA, USA

M. L. Hull  
Department of Biomedical Engineering, University of  
California, Davis, Davis, CA, USA

## Introduction

Total knee arthroplasty (TKA) reduces pain and restores function in patients with end-stage osteoarthritis. Most knee surgeons performing TKA have believed that neutral mechanical alignment should be restored. Surgeons have questioned the concept of mechanical alignment because patients with preoperative varus have better function when alignment is left in mild varus, and because a neutral alignment is undesirable and unnatural in some patients [1, 3, 13].

Kinematic alignment is a new method for aligning a TKA that provides better pain relief and restores better function and flexion at 2 years and better survivorship at 3 years than mechanical alignment performed with conventional instruments [2, 7]. Kinematically aligned TKA strives to position the femoral component at the natural angle and level of the distal ( $0^\circ$ ) and posterior ( $90^\circ$ ) joint line. Restoring the natural joint lines requires use of referencing guides applied at  $0^\circ$  and  $90^\circ$  with the goal of coaligning the femoral component with the three kinematic axes of the knee (Fig. 1) [8]. The resection level of these referencing guides is adjusted to resect bone and cartilage equal in thickness to the femoral component after correcting for bone and cartilage wear and kerf. Understanding whether femoral bone and cartilage wear is predictable



**Fig. 1** Illustration shows the relationship between the three kinematic axes, distal and posterior femoral resections, thickness of the condyles of the femoral component, and the distal and posterior joint lines of the femur. The transverse axis in the femur about which the tibia flexes and extends (*green line*) is parallel to the transverse axis in the femur about which the patella flexes and extends (*magenta line*). Both transverse axes are parallel to the distal and posterior joint line of the femur and perpendicular to the longitudinal axis in the tibia about which the tibia internally and externally rotates on the femur. The femoral component is “kinematically aligned” when the thickness of the distal and posterior resections equal the thickness of the condyle of the femoral component after correcting for wear and kerf

would assist in establishing general guidelines for adjusting the resection level of the referencing guides.

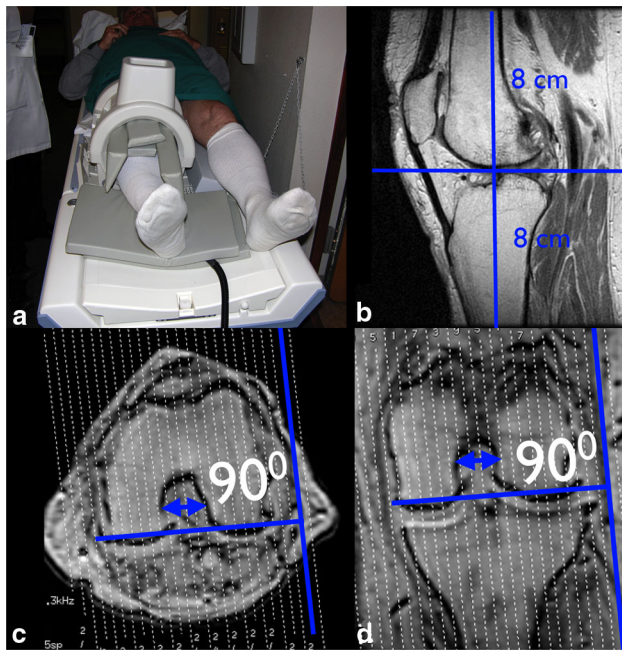
Magnetic resonance imaging allows reliable computation of cartilage wear on the condyles of the femur in the normal and osteoarthritic knee [4, 5, 11, 12]. However, no study has determined whether femoral bone and cartilage wear is predictable in a large series of patients with end-stage osteoarthritis treated with TKA. Accordingly, the present study tested the hypothesis that femoral bone and cartilage wear is predictable at  $0^\circ$  and  $90^\circ$  in the varus and valgus osteoarthritic knee requiring treatment with a TKA.

## Methods and materials

Between January and December of 2011, 296 patients underwent a kinematically aligned TKA at a single institution and were prospectively followed. The senior operating surgeon (SMH) routinely obtained rotationally aligned preoperative MRI scans, and standing radiographs of the knee in full extension and in  $45^\circ$  of flexion to determine the location and degree of femoral bone and cartilage wear for performing kinematically aligned TKA with generic instruments [8]. Patients were included when they had poor function, a diagnosis of a Kellgren–Lawrence Grade 3 or 4 osteoarthritis of the knee, were treated with a primary kinematically aligned TKA for any severity of varus–valgus deformity and flexion contracture, and had a rotationally aligned preoperative MRI scan. Patients were excluded when they had isolated patellofemoral arthritis, inflammatory arthritis, and arthritis as a sequela of a fracture. Review of the standing radiographs of the knee in full extension and in  $45^\circ$  of flexion and the magnetic resonance imaging scan determined whether a knee was assigned to the varus or valgus category. A varus knee had medial joint-space narrowing on radiograph and medial wear on the magnetic resonance imaging scan. A valgus knee had

**Table 1** Preoperative demographics and clinical characteristics

Preoperative demographics and clinical characteristics	Number of patients or knees	Mean (SD) or numbers (%)	Range or maximum
<i>Demographics</i>			
Age (years)	$N = 205$	67 (10)	47–92
Sex (male)	$N = 205$	41 %	
Body mass index ( $\text{kg}/\text{m}^2$ )	$N = 201$	31 (5.3)	21–44.4
<i>Preoperative deformity and function</i>			
Varus (–)/valgus (+) deformity ( $^\circ$ )	$N = 198$	0 (10.4)	–15 to 27
Oxford knee score (48 is best, 0 is worst)	$N = 198$	21 (8.4)	0–36



**Fig. 2** Composite shows the extended knee shimmed in the knee coil in the MRI scanner (a), the sagittal field of view of the knee (b), and the axial (c) and coronal (d) scout images used to align the image plane and project the knee in the sagittal kinematic plane. In the axial scout image, the sagittal plane was oriented perpendicular to a line tangent to the subchondral bone of the posterior femoral condyles (c). In the coronal scout image, the sagittal plane was oriented perpendicular to a line tangent to the subchondral bone of the distal femoral condyles (d). The sagittal kinematic plane projected the knee perpendicular to the two transverse axes in the femur about which the tibia and patella flex and extend

lateral joint-space narrowing on radiograph and lateral wear on the magnetic resonance imaging scan [9].

Accordingly, 208 knees in 205 patients met our inclusion criteria and were analysed. These patients had a mean age of  $67 \pm 10$  years, mean BMI of  $31 \pm 5$  kg/m<sup>2</sup>, and 41 % were male (Table 1). The average preoperative Oxford knee score of  $21 \pm 8.5$  (48 best) indicated poor function [10]. Of the 208 knees, 76 % were categorized as a varus deformity and 24 % were categorized as a valgus deformity. The preoperative tibiofemoral angle measured nonweight bearing during clinical examination with a long-arm goniometer ranged from  $-15^\circ$  varus to  $27^\circ$  valgus (mean  $0^\circ \pm 10^\circ$ ).

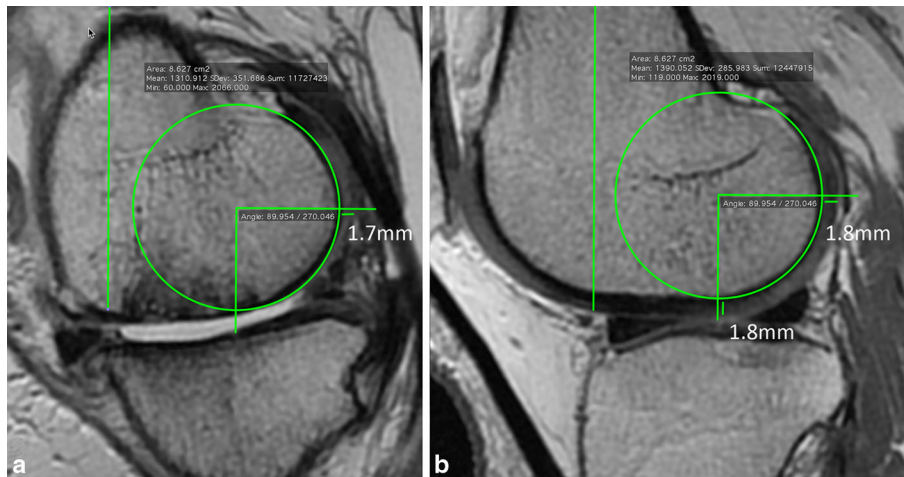
Preoperatively, a rotationally aligned MRI scan of each knee was obtained with a 1.5-T scanner and a dedicated knee coil (General Electric Medical Systems, Milwaukee, Wisconsin, U.S.A.). A previously described protocol that imaged the knee in the sagittal kinematic plane and that enabled accurate measurement of the radii of the medial and lateral femoral condyles was used to acquire each MRI (Fig. 2) [9]. The protocol aligned the knee in the sagittal kinematic plane by projecting the knee perpendicular to the

transverse axes in the femur about which the tibial and patella flex and extend on the femur. Projecting the knee perpendicular to the transverse axes required the use of coronal and axial localizer images, which were obtained with a 4-mm slice thickness, a 1-mm spacing/gap, a  $256 \times 224$  matrix, one excitation, and a 24-cm field of view that yielded nine slices in all three planes. The axial localizer image and the coronal localizer image showing the largest radius of the femoral condyles were selected. The sagittal kinematic plane was aligned perpendicular to a line tangent to the posterior femoral condyles on the axial localizer image, and perpendicular to a line tangent to the distal femoral condyles on the coronal localizer image. A two-dimensional scan was then acquired in the sagittal kinematic plane with the use of the following parameters: fast-relaxation fast-spin-echo proton density, 30–35-ms echo time, 2,800–3,400-ms repetition time, 31.25-Hz bandwidth, a minimum of two excitations with use of a 16-cm field of view centred at the joint line of the knee,  $256 \times 224$  matrix, 2-mm slice thickness, and no spacing/gap.

Free, open-source, image analysis software (Osirix, <http://www.osirix-viewer.com>, Geneva, Switzerland) was used to compute cartilage and bone wear at specific locations on the femur to assist in predicting the compensation for the distal and posterior femoral resections. The assessment of femoral bone and wear was performed at  $0^\circ$  and  $90^\circ$  in the medial–lateral centre of each femoral condyle. The distal and posterior referencing guides reference these specific locations when performing a kinematically aligned TKA with generic instruments [8].

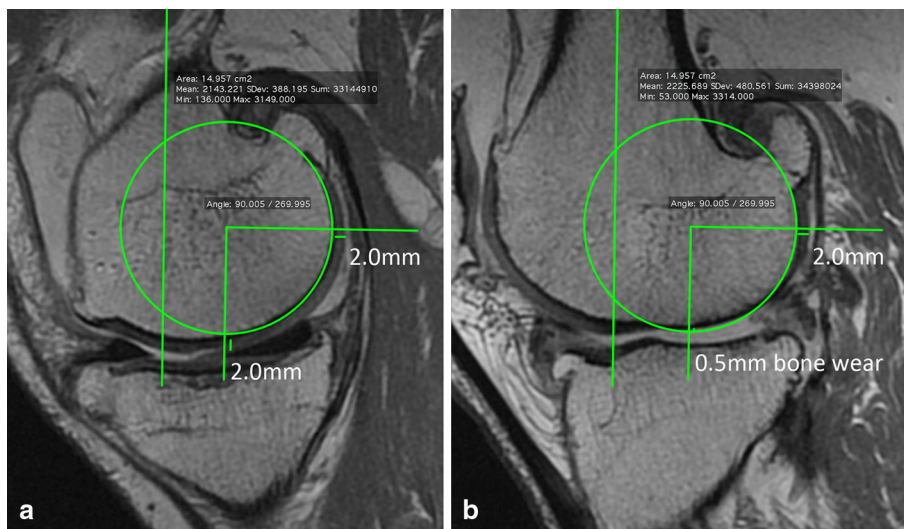
The following explanation justifies and describes the reliability of the method of applying a best-fit circle on each femoral condyle to compute femoral bone and cartilage wear in the osteoarthritic knee. The subchondral bone of the medial and lateral femoral condyles has the same single radius of curvature from  $10^\circ$  to  $160^\circ$  [9] and a single transverse axis [6]. Imaging the knee in the sagittal kinematic plane projects both femoral condyles as a circle because the sagittal kinematic plane is perpendicular to the transverse axis in the femur about which the tibia flexes and extends [9]. The reported interobserver variability of the difference in the measurement of the radius from the application of a best-fit circle by two observers averaged 0.02 mm (95 % confidence interval (CI) of 0.04 to  $-0.08$  mm) for the medial femoral condyle and  $-0.04$  mm (95 % CI of 0.02 to  $-0.1$  mm) for the lateral femoral condyle in the osteoarthritic knee [9].

Femoral bone and cartilage wear was computed by applying the best-fit circle on the peripheral boundary of the subchondral bone from  $10^\circ$  to  $160^\circ$  on the unworn lateral femoral condyle in the varus knee, and the unworn medial femoral condyle in the valgus knee with use of a



**Fig. 3** Composite shows the method for measuring and then computing cartilage and bone wear on the medial femoral condyle (**a**) and lateral femoral condyle (**b**) of a representative knee with a varus deformity. On the image showing the lateral femoral condyle, a vertical green line is drawn indicating the longitudinal axis of the femur. The best-fit circle is fit to the periphery of the subchondral bone. A right angle is centred on the circle. The side of the right angle aligned parallel to the longitudinal axis indicates 0° distal, and the

other side indicates 90° posterior. The thickness of the cartilage is measured at 0° (1.8 mm) and 90° (1.8 mm). All these regions-of-interest are propagated to the medial condyle, and the cartilage thickness and bone wear are measured. On the medial femoral condyle, there is no cartilage at the 0° distal aspect, no bone wear, and 1.7 mm of cartilage at 90° posterior. Cartilage loss is 1.8 mm distal medial and 0.1 mm posterior medial relative to the unworn lateral femoral condyle

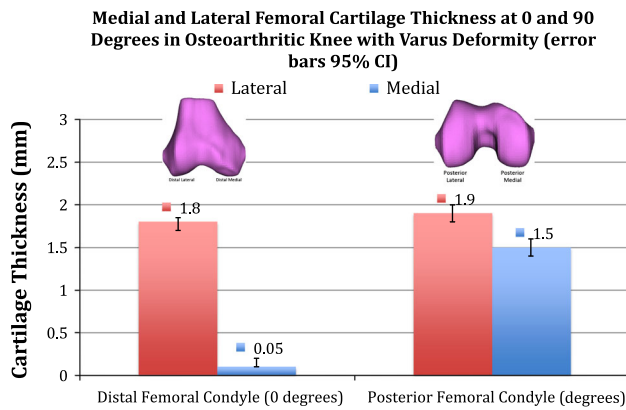


**Fig. 4** Composite shows the method for measuring and then computing cartilage and bone wear on the medial femoral condyle (**a**) and lateral femoral condyle (**b**) of a representative knee with a valgus deformity. On the medial femoral condyle, the cartilage thickness is 2.0 mm at 0° distal and 2.0 mm at 90° posterior. On the

lateral femoral condyle, there is no cartilage at the 0° distal aspect, 0.5 mm of bone wear, and 2.0 mm of cartilage at 90° posterior. Cartilage loss is 2.0 mm distal lateral and 0 mm posterior lateral relative to the unworn medial femoral condyle. Bone wear was not observed in 95 % of knees

previously described technique (Figs. 3, 4). The best-fit circle on the unworn condyle was copied, propagated, and centred (when necessary) on the peripheral boundary of the subchondral bone of the opposite or worn condyle. The distance between the best-fit circle and the periphery of the subchondral bone was measured at 0° and 90° on the medial and lateral femoral condyles (Fig. 4). Computation

of the difference in the distance between the best-fit circle and the periphery of the subchondral bone between the condyles at 0° and 90° determined bone wear. The thickness of the cartilage of each condyle was measured at 0° and 90°. Computation of the difference in cartilage thickness between the condyles at 0° and 90° determined cartilage wear [9]. Measurements were performed to the tenth



**Fig. 5** Column graph shows the mean cartilage thickness of the medial and lateral condyle at 0° distal and 90° posterior for the osteoarthritic knees with a varus deformity

position decimal point. A single observer (KL) applied the best-fit circles and computed femoral bone and cartilage wear.

#### Statistical analysis

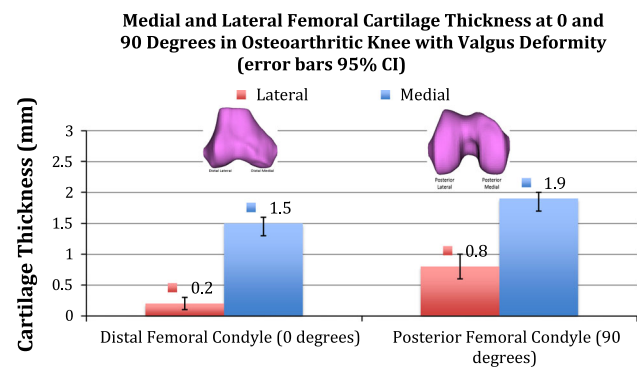
Computation of the intraclass correlation coefficient (ICC) determined the reliability of the measurements of femoral bone and cartilage wear performed by two trained observers (DN, KL) on 30 randomly selected MRI scans in the present study. The arithmetic mean, standard deviation, and 95 % CI of the mean were used to describe demographic data and femoral bone and cartilage wear. Analyses were performed with software (JMP, 10.02, <http://www.jmp.com>).

Sample size was calculated based on the hypothesis that greater than 90 % of knees with a varus deformity would demonstrate cartilage wear at 0° on the medial femoral condyle of greater than 1 mm. Confidence limits of plus or minus 5 % were used. It was determined that a sample of 139 knees would provide 95 % confidence that the true frequency would lie between 85 and 95 %.

#### Results

Intraclass correlation coefficients were between 0.86 and 0.91 for the measurements of femoral bone and cartilage wear. These high ICC values indicate computation of femoral bone and cartilage wear made by two independent observers were highly reliable [11].

In the 74 % (154 of 208) of the osteoarthritic knees with a varus deformity and medial joint-space narrowing on MRI and radiograph, femoral bone wear >1 mm was observed in 0.6 % (1 of 144) varus knees. Bone wear averaged  $0.0 \pm 0.2$  mm (95 % CI 0.0–0.1) at 0° on the



**Fig. 6** Column graph shows the mean cartilage thickness of the medial and lateral condyle at 0° distal and 90° posterior for the osteoarthritic knees with a valgus deformity

medial femoral condyle, 0 mm at 0° on the lateral femoral condyle, 0 mm at 90° on the medial femoral condyle, and 0 mm at 90° on the lateral femoral condyle. Femoral cartilage wear >1 mm was observed in 93 % (144 of 154) at 0° and in 18 % (28 of 154) at 90° on the medial femoral condyle. Femoral cartilage wear averaged  $1.7 \pm 0.5$  mm (95 % CI 1.7–1.8) at 0° and  $0.4 \pm 0.7$  mm (95 % CI 0.3–0.5) at 90° on the medial femoral condyle. The average cartilage thickness at 0° and 90° on the medial and lateral femoral condyle in the osteoarthritic knee that was used to compute medial and lateral cartilage wear in the knee with a varus deformity is shown in Fig. 5.

In the 26 % (54 of 208) of the osteoarthritic knees with a valgus deformity and lateral joint-space narrowing, bone wear >1 mm was not observed. Femoral bone wear averaged  $0.0 \pm 0.1$  mm (95 % CI 0.0–0.1) at 0° on the lateral femoral condyle, 0 mm at 0° on the medial femoral condyle, 0 mm at 90° on the lateral femoral condyle, and 0 mm at 90° on the medial femoral condyle. Femoral cartilage wear >1 mm was observed in 78 % (42 of 54) at 0° and in 56 % (30 of 54) at 90° on the lateral femoral condyle. Femoral cartilage wear averaged  $1.3 \pm 0.6$  mm (95 % CI 1.2–1.5) at 0° and  $1.1 \pm 0.7$  mm (95 % CI 0.9–1.3) at 90° on the lateral femoral condyle. The average femoral cartilage thickness at 0° and 90° that was used to compute medial and lateral cartilage wear in the knee with a valgus deformity is shown in Fig. 6.

#### Discussion

The most important findings of the present study were (1) that femoral bone wear is infrequent and (2) the pattern of femoral cartilage wear is predictable in the Kellgren–Lawrence Grade 3 or 4 osteoarthritic knees with a varus or valgus treated with TKA. Knowing that femoral bone wear

is rare, and femoral cartilage wear is predictable is helpful for establishing general guidelines for adjusting the referencing guides for positioning the femoral component when performing kinematically aligned TKA [8].

Two limitations should be discussed before interpreting the findings of our study. One is the assumption that the average cartilage thickness of 1.8 mm at 0° and 1.9 mm at 90° on the unworn lateral femoral condyle in the knee with a varus deformity and the average cartilage thickness of 1.5 mm at 0° and 1.9 mm at 90° on the unworn medial femoral condyle in the knee with a valgus deformity represents the cartilage thickness in a normal knee (Figs. 5, 6). This assumption is justified because they are comparable with the average cartilage thickness of 1.7–2.0 mm on the medial femoral condyle and 1.6–1.7 mm on the lateral femoral condyle from 0 to 140° reported for healthy normal knees [5, 11]. A second limitation is that the present study analysed Western subjects, and the results might be different when Eastern subjects are analysed because of known anatomic differences [11].

The present study's observation that femoral bone wear is rare in Kellgren–Lawrence Grade 3 and 4 osteoarthritic knees establishes the general guideline that compensation for femoral bone wear is rarely needed when performing kinematically aligned TKA. The finding that femoral bone wear is rare contradicts an observation of another study [14]. Victor et al. observed the tibial joint line diverged from parallel in patients with advanced varus arthritis, and attributed bone wear on the distal medial femoral condyle as the cause of the divergent joint line. Because their study did not measure femoral or tibial bone wear, it is unclear how the location of bone wear was determined. Our findings from analysing the MRIs of 208 knees in the present study suggest that tibial bone and cartilage wear and femoral cartilage wear is the likely cause of the divergent joint line in patients with advanced varus arthritis and not femoral bone wear.

Knowing that femoral cartilage wear is predictable in varus and valgus Kellgren–Lawrence Grade 3 or 4 osteoarthritic knees is helpful for establishing general guidelines for adjusting the referencing guides for positioning the femoral component when performing kinematically aligned TKA. The steps for treating the varus deformity include removing any remaining cartilage (average 0.1 mm) at the 0° location on the medial condyle, adjusting the resection level of the distal referencing guide to compensate for 2 mm of medial cartilage wear (average 1.9 mm), and using the posterior referencing guide at the 90° location set at neutral internal–external rotation with no adjustment for cartilage wear (Fig. 5). The steps for treating the valgus deformity include removing any remaining cartilage (average 0.2 mm) from the 0° location on the lateral condyle, adjusting the resection level of the distal

referencing guide to compensate for 2 mm of femoral cartilage wear (average 1.7), and using the posterior referencing guide at the 90° set at neutral internal–external rotation when the cartilage wear on the lateral femoral condyle is negligible, and adjusting the resection level of the posterior referencing guide to compensate for 1 mm of cartilage wear when there is >1 mm of femoral cartilage wear on the lateral femoral condyle (Fig. 6). The use of these general guidelines accurately restored alignment of the limb, knee, and the natural angle and level of the distal joint line in the coronal plane, rotational alignment of the femoral and tibial component in the axial plane, and provided high function as measured by an average Oxford knee score of 42 (best 48) when kinematically aligned TKA was performed with generic instruments [8].

A reliable relationship between the thickness of the joint space on a standing radiograph and the thickness of femoral bone and cartilage wear on MRI could eliminate the expense and inconvenience a preoperative MRI. A pilot study of the knees analysed in the present study revealed two reasons this relationship is not reliable. First, the measurement of femoral bone and cartilage wear cannot be made from a standing radiograph of the knee because the thickness of the joint space represents the combined wear of the femur and tibia. Second, identifying the maximum wear of the joint space may require multiple anteroposterior radiographs at different flexion angles because the interactions between the flexion angle of the knee, the anteroposterior location of wear on the tibial condyle, and the anteroposterior location of wear on the femoral condyle affect the thickness of the projected joint space. For these reasons, the present study determined femoral bone and cartilage wear from an MRI and not a standing radiograph of the knee.

## Conclusion

Knowing that bone wear is rare and cartilage wear is predictable in varus and valgus Kellgren–Lawrence Grade 3 or 4 osteoarthritic knees helps establish general guidelines for adjusting the distal and posterior femoral referencing guides to restore the natural angle and level of the femoral joint lines when performing kinematically aligned TKA with generic instruments [8].

## References

1. Bellemans J, Colyn W, Vandenuecker H, Victor J (2012) The Chitranjan Ranawat award: is neutral mechanical alignment normal for all patients? The concept of constitutional varus. *Clin Orthop Relat Res* 470(1):45–53

2. Dossett HG, Swartz GJ, Estrada NA, LeFevre GW, Kwasman BG (2012) Kinematically versus mechanically aligned total knee arthroplasty. *Orthopedics* 35:e160–e169
3. Eckhoff DG, Bach JM, Spitzer VM, Reinig KD, Bagur MM, Baldini TH, Flannery NM (2005) Three-dimensional mechanics, kinematics, and morphology of the knee viewed in virtual reality. *J Bone Joint Surg Am* 87(Suppl 2):71–80
4. Eckstein F, Kwok CK, Boudreau RM, Wang Z, Hannon MJ, Cotofana S, Hudelmaier MI, Wirth W, Guermazi A, Nevitt MC, John MR, Hunter DJ, Investigators OAI (2013) Quantitative MRI measures of cartilage predict knee replacement: a case-control study from the Osteoarthritis Initiative. *Ann Rheum Dis* 72:707–714
5. Frobell RB, Nevitt MC, Hudelmaier M, Wirth W, Wyman BT, Benichou O, Dreher D, Davies R, Lee JH, Baribaud F, Gimona A, Eckstein F, Osteoarthritis Initiative Investigators (2010) Femorotibial subchondral bone area and regional cartilage thickness: a cross-sectional description in healthy reference cases and various radiographic stages of osteoarthritis in 1,003 knees from the Osteoarthritis Initiative. *Arthritis Care Res (Hoboken)* 62:1612–1623
6. Hollister AM, Jatana S, Singh AK, Sullivan WW, Lupichuk AG (1993) The axes of rotation of the knee. *Clin Orthop Relat Res* 290:259–268
7. Howell SM, Howell SJ, Kuznik KT, Cohen J, Hull ML (2013) Does a kinematically aligned total knee arthroplasty restore function without failure regardless of alignment category? *Clin Orthop Relat Res* 471(3):1000–1007
8. Howell SM, Papadopoulos S, Kuznik KT, Hull ML (2013) Accurate alignment and high function after kinematically aligned TKA performed with generic instruments. *Knee Surg Sports Traumatol Arthrosc* 21:2271–2280
9. Howell SM, Howell SJ, Hull ML (2010) Assessment of the radii of the medial and lateral femoral condyles in varus and valgus knees with osteoarthritis. *J Bone Joint Surg Am* 92:98–104
10. Kalairajah Y, Azurza K, Hulme C, Molloy S, Drabu KJ (2005) Health outcome measures in the evaluation of total hip arthroplasties—a comparison between the Harris hip score and the Oxford hip score. *J Arthroplasty* 20:1037–1041
11. Li H, Hosseini A, Li JS, Gill TJ IV, Li G (2012) Quantitative magnetic resonance imaging (MRI) morphological analysis of knee cartilage in healthy and anterior cruciate ligament-injured knees. *Knee Surg Sports Traumatol Arthrosc* 20:1496–1502
12. Tashiro Y, Uemura M, Matsuda S, Okazaki K, Kawahara S, Hashizume M, Iwamoto Y (2012) Articular cartilage of the posterior condyle can affect rotational alignment in total knee arthroplasty. *Knee Surg Sports Traumatol Arthrosc* 20:1463–1469
13. Vanlommel L, Vanlommel J, Claes S, Bellemans J (2013) Slight undercorrection following total knee arthroplasty results in superior clinical outcomes in varus knees. *Knee Surg Sports Traumatol Arthrosc* 21(10):2325–2330
14. Victor JM, Bassens D, Bellemans J, Gursu S, Dhollander AA, Verdonk PC (2013) Constitutional varus does not affect joint line orientation in the coronal plane. *Clin Orthop Relat Res* 472(1):98–104