


*Variability of the location of the tibial tubercle affects the rotational alignment of the tibial component in kinematically aligned total knee arthroplasty*

**Stephen M. Howell, Justin Chen & Maury L. Hull**

**Knee Surgery, Sports Traumatology, Arthroscopy**

ISSN 0942-2056

Knee Surg Sports Traumatol Arthrosc  
DOI 10.1007/s00167-012-1987-5



**Your article is protected by copyright and all rights are held exclusively by Springer-Verlag. This e-offprint is for personal use only and shall not be self-archived in electronic repositories. If you wish to self-archive your work, please use the accepted author's version for posting to your own website or your institution's repository. You may further deposit the accepted author's version on a funder's repository at a funder's request, provided it is not made publicly available until 12 months after publication.**

# Variability of the location of the tibial tubercle affects the rotational alignment of the tibial component in kinematically aligned total knee arthroplasty

Stephen M. Howell · Justin Chen · Maury L. Hull

Received: 2 September 2011 / Accepted: 20 March 2012  
© Springer-Verlag 2012

## Abstract

**Purpose** Our experience with computer plans of kinematically aligned total knee arthroplasty showed that the anteroposterior (AP) axis of the tibial component when viewed in an axial plane did not consistently intersect either the medial border or the medial 1/3 of the tibial tubercle. The purposes were (1) to determine the variability in the mediolateral location of the tibial tubercle with respect to the medial tibia on the magnetic resonance image (MRI) of the knee and (2) to determine whether the AP axis of the kinematically aligned tibial component intersects either the medial border or the medial 1/3 of the tibial tubercle.

**Methods** One hundred and fifteen knees in 111 consecutive subjects treated with total knee arthroplasty were studied. The mediolateral location of the tibial tubercle was measured from a magnetic resonance image (MRI) of the knee. The distances between the AP axis of the tibial component and the medial border of the tibial tubercle and between the AP axis and the medial 1/3 of the tibial tubercle were measured from a computer plan of the reconstructed knee.

**Results** On the MRI, the medial border of the tibial tubercle varied 15 mm from the medial border of the tibia. On the computer plan, the AP axis of the tibial component in an axial

view of the tibia did not intersect either the medial border ( $p < 0.0001$ ) or the medial 1/3 of the tibial tubercle ( $p < 0.0001$ ). In 70 and 86 % of knees, the mediolateral distance of the AP axis of the tibial component was 2 mm or greater from the medial border of the tibial tubercle and the medial 1/3 of the tibial tubercle, respectively, which causes a clinically meaningful error in rotation of  $5^\circ$  or more.

**Conclusions** Because the mediolateral location of the tibial tubercle varies, the medial border and medial 1/3 of the tibial tubercle are not reliable landmarks when the goal is to kinematically align the rotation of the tibial component on the tibia.

**Level of evidence** IV.

**Keywords** Rotation · Tibial component · Kinematic alignment · Knee

## Introduction

Several factors affect surgical outcome of total knee arthroplasty (TKA), one of which is the method used to align the tibial and femoral components with respect to the limb in the coronal plane [13]. Mechanical alignment is the prevalent method where the goal is to establish a neutral mechanical axis [6, 8, 29]. Using this method, however, 18–25 % of patients are dissatisfied after TKA and more than 7 % of patients require a revision surgery (<http://www.cdhb.govt.nz/njr/>) [4, 9, 28]. Kinematic alignment is a new method with which has lowered the percentage of dissatisfied patients [13]. The goal of kinematic alignment is to position the femoral and tibial components so that the three axes of motion of the knee and the alignment of the limb are restored to those of the prearthritic knee [19, 21].

---

S. M. Howell · J. Chen · M. L. Hull (✉)  
Department of Mechanical Engineering, University of California  
at Davis, One Shields Avenue, Davis, CA 95616, USA  
e-mail: mlhull@ucdavis.edu

S. M. Howell  
Biomedical Engineering Graduate Group, University  
of California at Davis, One Shields Avenue,  
Davis, CA 95616, USA

M. L. Hull  
Department of Biomedical Engineering, University of California  
at Davis, One Shields Avenue, Davis, CA 95616, USA

A second factor that affects surgical outcome is the internal–external rotational alignment of the femoral and tibial components on their respective bones. For the rotational alignment of the femoral component, the transepicondylar axis has been widely used as a reference because it was thought that this axis represented the flexion–extension axis of the knees. However, recent studies have shown that the flexion–extension axis of the knee passes through the center of the medial and lateral femoral condyles on a line averaging 5° different from the transepicondylar axis [14]. As a result, kinematic alignment uses the flexion–extension axis that passes through the center of the medial and lateral femoral condyles for rotationally aligning the femoral component.

To rotationally align the tibial component on the tibia during surgery, an anatomical landmark on the tibia must be referenced. Two possible tibial landmarks are the medial border and the medial 1/3 of the tibial tubercle. Although the reliability of each of these landmarks in mechanical alignment has been questioned and debated [2, 3, 23, 30], no study known to the authors has analyzed the reliability of these landmarks in kinematic alignment. Hence the two primary objectives of this study were (1) to determine the variability in the mediolateral location of the tibial tubercle with respect to the medial tibia on the magnetic resonance image (MRI) of the knee and (2) to determine whether the AP axis of the kinematically aligned tibial component intersects either the medial border or the medial 1/3 of the tibial tubercle on an axial view of the computer plan. If the AP axis of the tibial component did not consistently intersect either landmark of interest, a secondary objective was to determine the strength of the relationships between the mediolateral location of the tibial tubercle on the MRI and the distance from the AP axis of the tibial component to the medial border and from the AP axis to the medial 1/3 of the tibial tubercle on a kinematically aligned computer plan. Strong relationships would further establish that these landmarks are not useful references when kinematically aligning the tibial component.

## Methods and materials

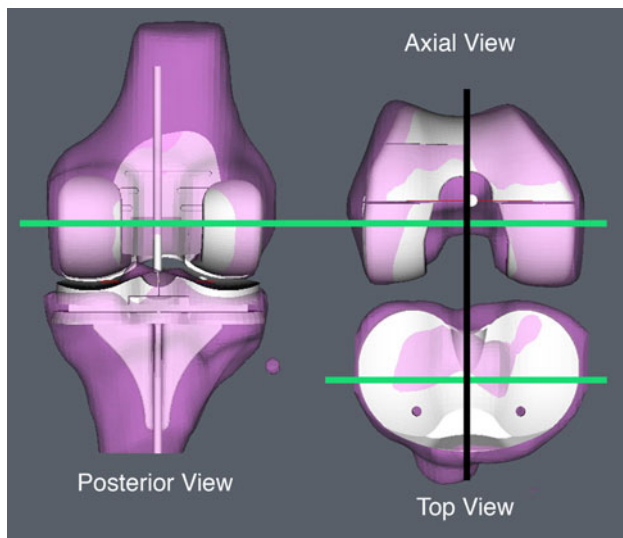
All subjects treated from January 2009 to June 2009 with a total knee arthroplasty for primary osteoarthritis of the knee by the lead author were considered for inclusion ( $N = 112$ ). Subjects were excluded if they had a tibial tubercle transfer ( $N = 1$ ) or fracture about the knee. The study consisted of 115 knees in 111 consecutive subjects. An institutional review board approved the study (University California at Davis, protocol number 200917495-1, date of approval November 6, 2009).

The measurement of the mediolateral location of the tibial tubercle was made on a magnetic resonance image

scan of the knee. The scan was obtained in a projection plane aligned perpendicular to a line connecting the distal femoral condyles and perpendicular to a line connecting the posterior femoral condyles. This protocol projected the knee in the kinematic sagittal plane, which is perpendicular to the transverse axis in the femur about which the tibia flexes and extends [14, 20]. The two-dimensional scan was obtained with a 2-mm slice thickness, no spacing/gap and with use of these parameters: fast-relaxation fast-spin-echo proton density, 30 to 35-ms echo time, 2,800 to 3,400-ms repetition time, 31.25-Hz bandwidth, a minimum of two excitations with use of a 16-cm field of view centered at the joint line of the knee, 256 × 224 matrix.

One author (SMH) measured the mediolateral location of the medial border of the tibial tubercle. The image lateral to the one that showed the smallest projection of the medial metaphysis was the medial border of the tibia. The image medial to the one that showed the smallest projection of the lateral metaphysis was the lateral border of the tibia. The image that first showed the medial border of the patella tendon attaching to the tibia was the medial border of the tibial tubercle. The mediolateral location of the tibial tubercle was the number of images from the medial tibia to the medial border of the tibial tubercle multiplied by the image thickness of 2 mm. The width of the tibia was the number of images between the medial and lateral borders of the tibia multiplied by the image thickness of 2 mm. The location of the tibial tubercle was standardized to an 80-mm-wide tibia by multiplying the location of the tibial tubercle by 80 mm and dividing by the width of the tibia.

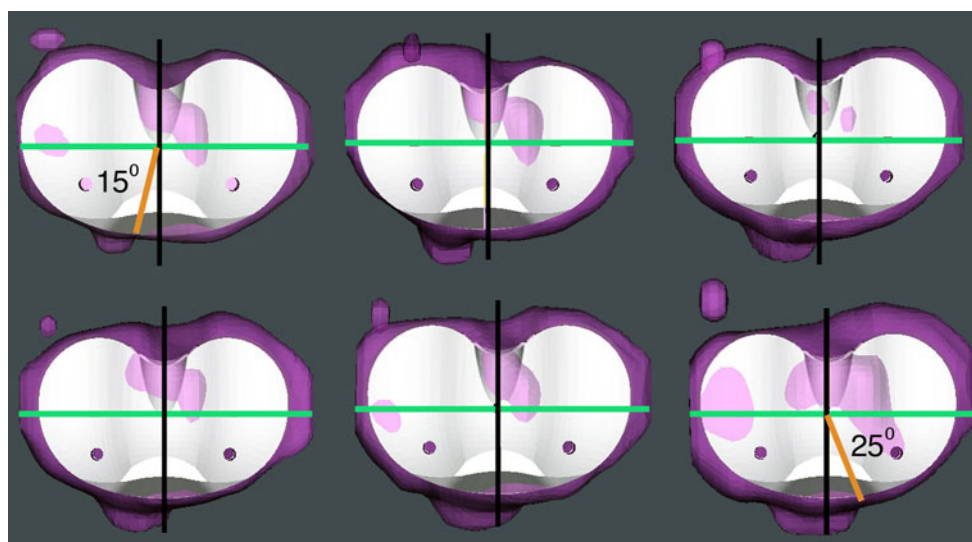
The mediolateral distances between the AP axis of the tibial component and the medial border of the tibial tubercle and between the AP axis and the medial 1/3 of the tibial tubercle were measured on a 3-dimensional model of the normal knee with the femoral and tibial components kinematically aligned. The creation of the normal knee model began with segmenting the femur, tibia, articular cartilage, and osteophytes from each image slice of the MR scan using proprietary software (OtisMed, Corp, Alameda, CA). After the worn articular surfaces were conceptually transformed into normal articular surfaces by filling in defects, software meshed the slices and formed 3-dimensional models of the long bones. With the knee in extension, the long bones were aligned with respect to one another. Anteroposterior and mediolateral positions of the tibia were centered on the femur, and the varus–valgus orientation was adjusted until there was equal separation between the medial and lateral hemijoints. The internal–external rotation of the tibia on the femur was not changed from that of the unweighted MR scan. Proprietary software selected the best-fitting 3-dimensional models of symmetric femoral and tibial components (cruciate-retaining Vanguard, Biomet Inc, Warsaw, IN) (Fig. 1). The surfaces of the condyles in a



**Fig. 1** The *posterior*, *axial*, and *top (superior)* views of a right knee are shown of a 3-dimensional model of the knee made from an MRI with the best-fitting femoral and tibial components kinematically aligned. The femoral component is shape-matched to the articular surface of the femur, which coaligns the transverse axis of the femur about which the tibia flexes and extends (transverse *green line*) with the transverse axis of the femoral component. The transverse axis of the femur is projected on the tibia. Aligning the anteroposterior axis of the tibial component (*black line*) perpendicular to the transverse axis of the femoral component while preserving the axial rotation of the tibia relative to the femur in the unweighted MR images kinematically aligns the tibial component to the femoral component

3-dimensional model of the femoral component were shape-matched to the 3-dimensional model of the normal femur hence superimposing the transverse axes in the femur and femoral component and kinematically aligning the femoral component. Because there is no clinically important asymmetry between the medial and lateral femoral condyles in the varus and valgus knee with end-stage osteoarthritis [18], a symmetric femoral component seems an optimal design for replicating knee kinematics. With the knee in full extension, the symmetric tibial component was centered on the femoral component, adjusted in flexion–extension so that the posterior slope was neutral, and rotated so that the AP axis of the tibial component was perpendicular to the transverse axis of the femoral component. Because the internal–external rotation of the tibia with respect to the femur in the normal model of the knee was preserved, the rotation of the tibia was thereby kinematically aligned. The size of the tibial component was determined by the one that gave the greatest coverage without extending beyond the peripheral rim of the tibia.

Another author (JC) different from the one who measured the tibial tubercle location on the MRI imported the axial view of the computer plan that included the tibial component on the tibia into image analysis software (Scion Image 4.0.2, Scion, Corp., Frederick, MD, USA) (Fig. 2). The points corresponding to the medial border of the tibial tubercle, the lateral border of the tibial tubercle, the AP



**Fig. 2** *Top view* of the computer plan of six right tibias standardized to an 80-mm width shows the variability of the location of the tibial tubercle with respect to the anteroposterior axis of the tibial component (*black line*). The transverse axis in the femur about which the tibia flexes and extends (*green line*) is projected onto the tibia. For the tibia with the most lateral tibial tubercle (*upper left*), 15° of external malrotation of the tibial component is required to align the anteroposterior axis to the medial border of the tibial tubercle. For the

tibia with the most medial tibial tubercle (*lower right*), 25° of internal malrotation of the tibial component is required to align the anteroposterior axis to the medial border of the tibial tubercle. Aligning the anteroposterior axis of the tibial component to a line drawn from the center of the posterior cruciate ligament fossa to the medial border of the patella tendon (tubercle) also is unreliable because it matches the anteroposterior axis of the tibial component in only one of the six computer plans (*upper right*)

axis of the tibial component, the medial border of the tibial component, and the lateral border of the tibial component were recorded. Custom routines calculated the mediolateral distance in pixels between the AP axis of the tibial component and the medial border and between the AP axis and the medial 1/3 of the tibial tubercle (Excel, Microsoft, Inc, Redmond, WA, USA). The distances in pixels were converted to millimeters with use of the known width of the tibial component. Following this conversion, the values corresponding to the standardized tibia width of 80 mm were calculated. A positive value indicated that the AP axis of the tibial component was lateral to the point of interest on the tibial tubercle. A negative value indicated that the AP axis of the tibial component was medial to the point of interest on the tibial tubercle.

### Statistical analysis

The arithmetic mean, 95 % confidence interval, and frequency distribution described the data. A Student's *t* test determined whether the AP axis of the kinematically aligned tibial component intersects with either the medial border or the medial 1/3 of the tibial tubercle on the axial view of the computer plan. The maximum error from rotating the tibial component on the tibia until the AP axis intersected the medial border of the tibial tubercle was calculated using the knees with the most medial and most lateral tibial tubercles. The rotational error was the angle opposite the base of an isosceles triangle. The base of the triangle was the distance between the intersection of the AP

axis of the tibial component and the medial border of the tibial tubercle, one side of the triangle was the AP axis, and the sides were 23 mm in length, which is the average distance from the center of the tibia to the center of the tibial tubercle [11]. Two examiners (blinded) independently determined the location of the intersections in 18 randomly selected subjects. A simple linear regression determined the strength of the relationship between the mediolateral location of the tibial tubercle on the MRI and the distance between the AP axis of the tibial component and the medial border of the tibial tubercle and between the AP axis and medial 1/3 of the tibial tubercle on the kinematically aligned computer plan.

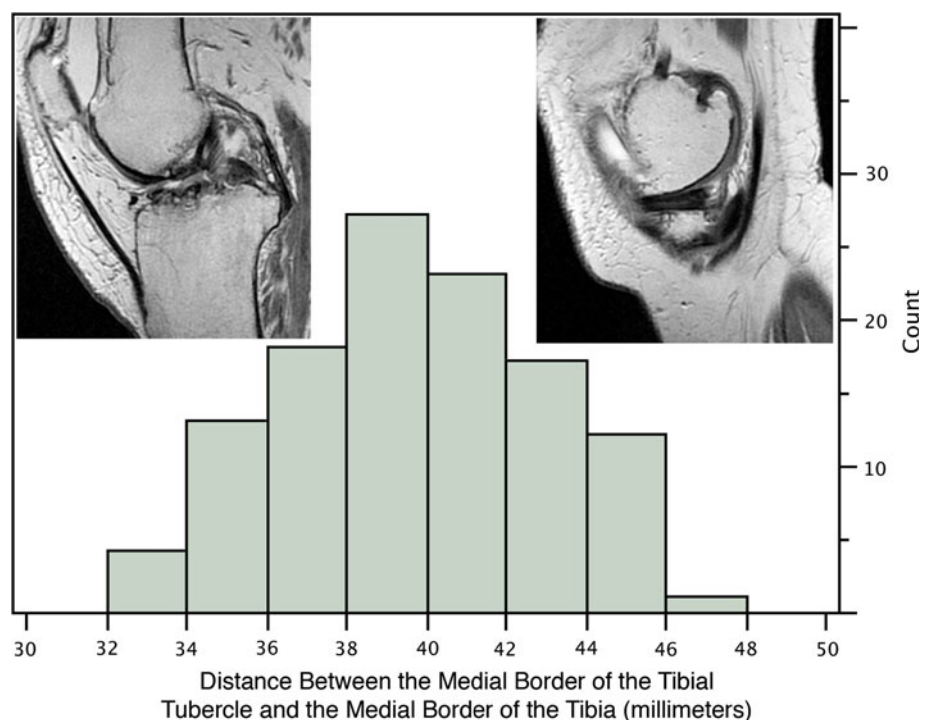
Inter-examiner reliability was determined with simple linear regression (JMP Version 7.0.2, JMP for MacIntosh; SPSS, Chicago, IL, USA; <http://www.jmp.com>). The sample size of 18 was chosen to provide a sufficient data set for the analysis. With this sample size and the high slope (described below), the power was virtually 100 %.

### Results

The mean age of the 111 subjects was  $69 \pm 11$  years (range, 40–90) of which 69 were women and 42 were men.

The measurements on the MR images showed wide variability in the location of the tibial tubercle on the standardized tibia between subjects (Figs. 2 and 3). The mean location of the tibial tubercle was  $39 \pm 3$  mm (95 % CI, 39 to 40 mm), ranged from 32 to 47 mm, and varied

**Fig. 3** Histogram shows the variability in the medial–lateral location of the medial border of the tibial tubercle expressed as the distance in millimeters from the medial border of the tibia as determined from the MR images of the knee. The distance was measured from tibias standardized to an 80-mm width. The *upper right inset* figure shows the image of the medial border of the tibia, and the *upper left inset* figure shows the image of the medial border of the tibial tubercle. The y axis provides a count of the number of subjects in each distance grouping. The mean location of the tibial tubercle was  $39 \pm 3$  mm (95 % CI, 39 to 40 mm), ranged from 32 to 47 mm, and varied 15 mm from the medial border of the tibia



15 mm from the medial border of the tibia. The 15-mm variability in location equates to 40° of variability in the location of the medial border of the tibial tubercle on the tibia when referenced to the AP axis of the tibial component (Fig. 2).

The AP axis of the kinematically aligned tibial component did not intersect the medial border of the tibial tubercle ( $p < 0.0001$ ). The location of the medial border of the tibial tubercle averaged  $-3 \pm 3$  mm medial (95 % CI,  $-3$  to  $-4$  mm), ranged from  $-10$  mm medial to 6 mm lateral, and varied 16 mm with respect to the intersection of the AP axis of the tibial component (Fig. 4). In 70 % of knees, the medial border of the tibial tubercle was 2 mm or greater away from the intersection of the AP axis of the tibial component, which causes an error in rotational alignment of 5° or more.

The AP axis of the kinematically aligned tibial component did not intersect the medial 1/3 of the tibial tubercle ( $p < 0.0001$ ). The medial 1/3 of the tibial tubercle averaged  $4 \pm 2$  mm lateral (95 % CI, 4 to 5 mm), ranged from  $-2$  mm medial to 9 mm lateral, and varied 11 mm with respect to the AP axis of the tibial component (Fig. 5). In 86 % of knees, the mediolateral distance of the AP axis of

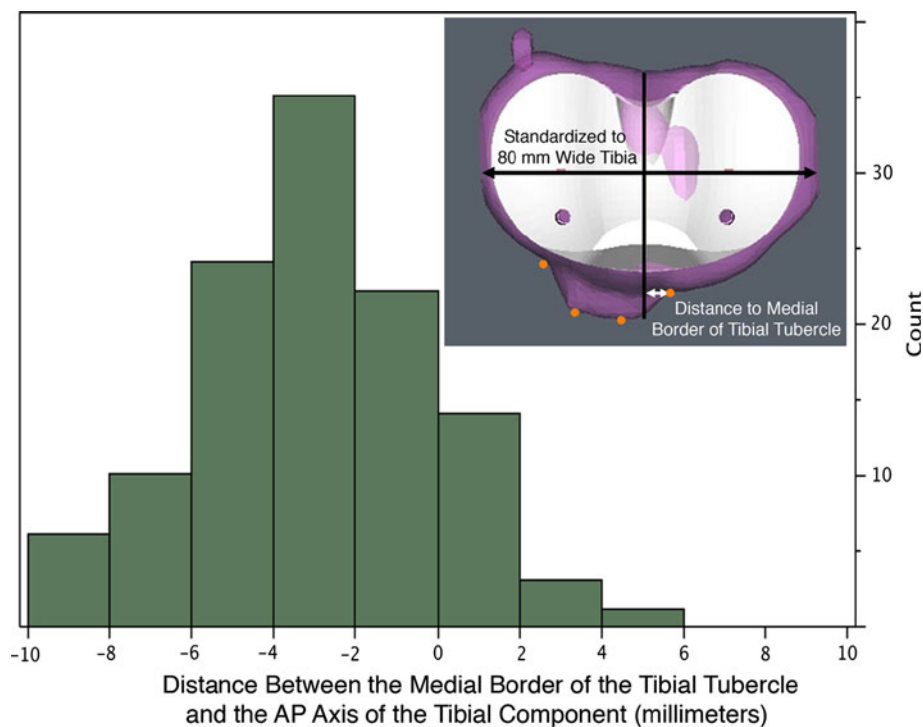
the tibial component was 2 mm or greater away from the medial 1/3 of the tibial tubercle, which causes a clinically meaningful error in rotation of 5° or more.

The interobserver analysis of the two examiners' measurement of the mediolateral distance between the AP axis of the tibial component and the medial border (intercept = 0.0, slope = 0.97,  $r^2 = 0.97$ ) and the medial 1/3 (intercept = 0.29, slope = 0.95,  $r^2 = 0.98$ ) of the tibial tubercle showed high repeatability with an intercept close to 0, a slope close to 1, and an  $r^2 > 0.95$ .

There was a moderately strong correlation between the mediolateral location of the tibial tubercle and the distance between the AP axis of the tibial component and the medial border and medial 1/3 of the tibial tubercle ( $r^2 = 0.549$  and 0.583, respectively).

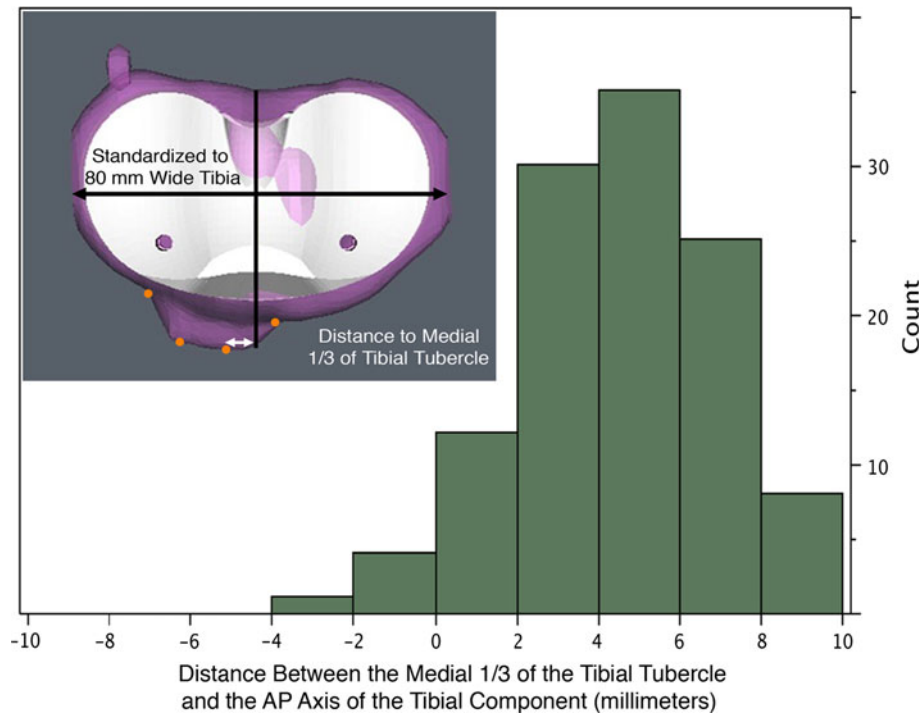
## Discussion

One important finding was that the mediolateral location of the tibial tubercle varied 15 mm. Another important finding was that most knees (70 and 86 %, respectively) required 5° or more of malrotation of the tibial component for the



**Fig. 4** Histogram shows the variability of the distance in millimeters between the anteroposterior axis of the kinematically aligned tibial component and the medial border of the tibial tubercle. The inset figure (upper right) shows the method for determining the distance (white double-headed arrow) between the anteroposterior axis of the tibial component (vertical black line) and the medial border of the tibial tubercle. In this case, the medial border of the tibial tubercle is

$-4$  mm medial to the anteroposterior axis, which means 10° of internal malrotation of the tibial component aligns the anteroposterior axis of the tibial component to the medial border of the tibial tubercle. In 70 % of knees, the intersection of the anteroposterior axis of the tibial component was 2 mm or greater away from the medial border of the tibial tubercle, which causes a clinically meaningful error in rotation of 5 or more degrees



**Fig. 5** Histogram shows the variability of the distance between the medial 1/3 of the tibial tubercle and the anteroposterior axis of the kinematically aligned tibial component. The inset figure (upper left) shows the method for determining the distance (white double-headed arrow) between the anteroposterior axis of the tibial component (vertical black line) and the medial 1/3 of the tibial tubercle (orange dots). In

this case, the medial 1/3 of the tibial tubercle is 6 mm lateral to the intersection of the anteroposterior axis, which means 15° of external malrotation of the tibial component aligns the anteroposterior axis of the tibial component to the medial 1/3 of the tibial tubercle. In 86 % of knees, the intersection of the anteroposterior axis of the tibial component was 2 or more mm away from the medial 1/3 of the tibial tubercle, which causes a clinically meaningful error in rotation of 5 or more degrees

AP axis to intersect the medial border of the tibial tubercle and the medial 1/3 of the tibial tubercle. The correlation analysis between the mediolateral location of the tibial tubercle and the mediolateral distance between the AP axis of the kinematically aligned tibial component and the two anterior tibial landmarks of interest amplified this finding.

Three limitations might affect the generalization that the location of the tibial tubercle is variable and that the AP axis of a kinematically aligned tibial component does not intersect either landmark for most subjects. First, error in the segmentation of the tibial tubercle used to recreate the shape of the tibial tubercle in the 3-dimensional model of the knee affected the distance measured between the medial border and medial 1/3 of the tibia tubercle and the AP axis of the tibial component on the axial view of the computer plan. However, segmentation was performed within  $\pm 0.5$  mm, which is a small error when considering the 15-mm range between the medial border and the 11-mm range between the medial 1/3 of the tibial tubercle and the AP axis of the tibial component.

Second, the procedural step of standardizing the results to an 80-mm-wide tibia affected our results to some degree. This step was taken to reduce the variability in the angular

location of the landmarks. Accordingly, the analysis presented herein must be viewed as conservative. Inasmuch as this conservative analysis showed wide variability in the landmarks, clearly this finding would only be amplified in a less conservative analysis.

Third, several studies have shown a variety of anatomic differences between the limbs of Eastern and Western subjects [31, 34]. In Japanese, for example, increased medial torsion of the tibia can cause extreme internal rotation of the foot if the tibial component is aligned to the medial 1/3 of the tibial tubercle [27]. Accordingly, our study has revealed clinically important information about the variability and location of the tibial tubercle in a Western population that might be different in Eastern subjects.

Our finding that the AP axis of the kinematically aligned tibial component did not intersect either the medial border or the medial 1/3 of the tibial tubercle for most subjects indicates that neither of these landmarks is useful for setting the rotational alignment of the tibial component in kinematically aligned TKA. An error of less than 5° is needed to minimize anterior knee pain, patella-tracking complications including tilt, subluxation, and dislocation,



as well as asymmetric wear of the tibial liner [5, 7, 22, 25]. The use of the medial border of the tibial tubercle and the medial 1/3 of the tibial tubercle malrotated the tibial component  $5^\circ$  or more in 70 and 86 % of subjects, respectively. The conclusion that neither the medial border nor the medial 1/3 of the tibial tubercle is a useful landmark in kinematic alignment of total knee arthroplasty is similar to the conclusions from other studies which used different alignment methods [22, 26, 30, 32].

An important difference between the present study and other studies is the orientation of the axis in the femur that was used to align the AP axis of the tibial component. Other studies have aligned the AP axis of the tibial component perpendicular to the transepicondylar axis [1, 10, 14], whereas the present study aligned the AP axis of the tibial component perpendicular to the transverse axis of the femoral component in the femur which theoretically coincides with the axis about which the tibia flexes and extends [2, 3, 23, 26]. Eckhoff et al. described a mean difference of  $5^\circ$  with a range of  $2^\circ$ – $11^\circ$  between the transepicondylar and transverse axis about which the tibia flexes and extends in 3-dimensional space and emphasized that the use of the transepicondylar axis does not restore normal ligament length and kinematics [14]. If rotational alignment of the tibial component should be perpendicular to a rotational axis in the femur, then the transverse axis of the femoral component is preferred because in theory this axis defines kinematic movement of the tibia and patella on the femur whereas the transepicondylar axis does not [12, 14, 15, 17, 18, 24, 33].

Even though a rotational axis in our study to align the tibial component was different from that used in previous studies, our finding of wide variability in the tibial tubercle landmarks investigated is similar to the findings of studies which used different axes. For example, one study [32] defined an AP axis on the tibia which originated at the center of a line parallel to the transepicondylar axis projected onto the axial plane and shifted so that it traversed the widest part of the tibia. The angle between the AP axis, which was perpendicular to the projected and shifted transepicondylar axis, and a line to the medial 1/3 of the tibial tubercle varied  $26^\circ$  with approximately 50 % of knees having an angle of  $5^\circ$  or more. Another study [3] defined an AP line perpendicular to the projection of the transepicondylar axis in the axial plane, but their line passed through the projected middle of the PCL. The angle between this line and a line originating at the middle of the PCL and passing through the medial 1/3 of the tibial tubercle varied  $24^\circ$ . The fact that our range of  $40^\circ$  exceeded these previously reported ranges by  $16^\circ$  is not surprising because the angle between the cylindrical axis that coincides with the transverse axis of the femoral component and the transepicondylar axis varies up to  $14^\circ$  [16].

Aligning the rotation of the tibial component intraoperatively remains a challenge. The use of the medial border of the tibial tubercle limits the error within  $5^\circ$  in just 30 % of subjects, and the use of the medial 1/3 limits the error within  $5^\circ$  in only 14 % of subjects. The use of a line drawn anterior from the center of the posterior cruciate ligament fossa to the medial border of the patella tendon or tubercle, which is perpendicular to the transepicondylar axis [2, 3], also is unreliable as shown in Fig. 2. The use of the medial 1/3 of the tibial tubercle is even less reliable in patients from the Far East because extreme internal rotation of the foot may result from the increased medial torsion of the tibia [27]. The use of the “range-of-motion technique,” which allows the tibial component to orient itself relative to the femoral component, has a tendency to leave the tibia externally rotated [23]. Finally, the repeatability between skilled arthroplasty surgeons is poor in selecting conventional anatomic tibial landmarks such as (1) the line between the most medial and most lateral points of the tibial plateau, (2) the line between the medial 1/3 of the tubercle and the posterior cruciate ligament insertion, (3) the line between the medial border of the tubercle and the PCL, and 4) the line between the projection of the anterior crest and the posterior cruciate ligament insertion with both conventional and computer-assisted instruments [30].

Recognizing all these difficulties, we currently use a combination of visual inspection of the internal–external rotation of the ankle and foot with the knee in full extension to avoid excessive internal–external rotation of the limb, a visual assessment of patella tracking, the range-of-motion technique, and the medial border of the tibial tubercle. When the internal–external rotation of the ankle and foot with the knee in full extension looks normal, when the patella tracks well, when there is no binding or gapping during passive motion throughout the motion arc, and when the intersection of the AP axis of the tibial component is near the medial side of the tibial tubercle, the rotation of the tibial component on the tibia has been set to the best of our ability.

## Conclusion

The medial border of the tibial tubercle varies widely from the medial tibia. For a tibia width standardized to 80 mm, the variability was 15 mm. Accordingly, neither the medial border of the tibial tubercle nor the medial 1/3 of the tibial tubercle are useful landmarks for rotationally aligning the tibial component in kinematically aligned total knee arthroplasty. The use of the medial border of the tibial tubercle will cause a clinically important error of  $5^\circ$  or more in 70 % of patients while the use of the medial 1/3 of the tibial tubercle will cause this error in 86 % of patients.

**Conflict of interest** No authors have signed any agreement with a commercial interest related to this study, which would in any way limit publication of any and all data generated for the study or to delay publication for any reason. One of the authors (SMH) is a paid consultant for and receives royalties from Biomet Sports Medicine, Inc, and is a consultant for Stryker Orthopaedics. Two authors (SMH, MLH) receive research support from Stryker Orthopaedics.

## References

- Abadie P, Galaud B, Michaut M, Fallet L, Boisrenoult P, Beaufile P (2009) Distal femur rotational alignment and patellar subluxation: a CT scan in vivo assessment. *Orthop Traumatol Surg Res* 95:267–271
- Akagi M, Mori S, Nishimura S, Nishimura A, Asano T, Hamanishi C (2005) Variability of extraarticular tibial rotation references for total knee arthroplasty. *Clin Orthop Relat Res* 436:172–176
- Akagi M, Oh M, Nonaka T, Tsujimoto H, Asano T, Hamanishi C (2004) An anteroposterior axis of the tibia for total knee arthroplasty. *Clin Orthop Relat Res* 420:213–219
- Baker PN, van der Meulen JH, Lewsey J, Gregg PJ (2007) The role of pain and function in determining patient satisfaction after total knee replacement. Data from the national joint registry for England and Wales. *J Bone Jt Surg* 89B:893–900
- Barrack RL, Schrader T, Bertot AJ, Wolfe MW, Myers L (2001) Component rotation and anterior knee pain after total knee arthroplasty. *Clin Orthop Relat Res* 392:46–55
- Bellemans J, Colyn W, Vandenneucker H, Victor J (2012) The Chitranjan Ranawat award: is neutral mechanical alignment normal for all patients? The concept of constitutional varus. *Clin Orthop Relat Res* 470:45–53
- Berger RA, Crosssett LS, Jacobs JJ, Rubash HE (1998) Malrotation causing patellofemoral complications after total knee arthroplasty. *Clin Orthop Relat Res* 356:144–153
- Bonner TJ, Eardley WGP, Patterson P, Gregg PJ (2011) The effect of post-operative mechanical axis alignment on the survival of primary total knee replacements after a follow-up of 15 years. *J Bone Jt Surg* 93B:1217–1222
- Bourne RB, Chesworth BM, Davis AM, Mahomed NN, Charron KD (2010) Patient satisfaction after total knee arthroplasty: who is satisfied and who is not? *Clin Orthop Relat Res* 468:57–63
- Chauhan SK, Clark GW, Lloyd S, Scott RG, Breidahl W, Sikorski JM (2004) Computer-assisted total knee replacement. A controlled cadaver study using a multi-parameter quantitative CT assessment of alignment (the Perth CT Protocol). *J Bone Jt Surg* 86B:818–823
- Cobb JP, Dixon H, Dandachli W, Iranpour F (2008) The anatomical tibial axis: reliable rotational orientation in knee replacement. *J Bone Jt Surg* 90B:1032–1038
- Coughlin KM, Incavo SJ, Churchill DL, Beynon BD (2003) Tibial axis and patellar position relative to the femoral epicondylar axis during squatting. *J Arthroplasty* 18:1048–1055
- Dossett GH, Swartz GJ, A EN, LeFevre GW, Kwasman BG (in press) Kinematic versus mechanically aligned total knee arthroplasty: a prospective randomized double blind study. *Orthopedics* 32:e160–169
- Eckhoff D, Hogan C, DiMatteo L, Robinson M, Bach J (2007) Difference between the epicondylar and cylindrical axis of the knee. *Clin Orthop Relat Res* 461:238–244
- Eckhoff DG, Bach JM, Spitzer VM, Reinig KD, Bagur MM, Baldini TH, Flannery NM (2005) Three-dimensional mechanics, kinematics, and morphology of the knee viewed in virtual reality. *J Bone Joint Surg* 87A(Suppl 2):71–80
- Eckhoff DG, Bach JM, Spitzer VM, Reinig KD, Bagur MM, Baldini TH, Rubinstein D, Humphries S (2003) Three-dimensional morphology and kinematics of the distal part of the femur viewed in virtual reality. Part II. *J Bone Joint Surg* 85A(Suppl 4):97–104
- Hollister AM, Jatana S, Singh AK, Sullivan WW, Lupichuk AG (1993) The axes of rotation of the knee. *Clin Orthop Relat Res* 290:259–268
- Howell SM, Howell SJ, Hull ML (2010) Assessment of the radii of the medial and lateral femoral condyles in varus and valgus knees with osteoarthritis. *J Bone Joint Surg* 92A:98–104
- Howell SM, Kuznik K, Hull ML, Siston RA (2008) Results of an initial experience with custom-fit positioning total knee arthroplasty in a series of 48 patients. *Orthopedics* 31:857–863
- Howell SM, Kuznik K, Hull ML, Siston RA (2010) Longitudinal shapes of the tibia and femur are unrelated and variable. *Clin Orthop Relat Res* 468:1142–1148
- Howell SM, Rogers SL (2009) Method for quantifying patient expectations and early recovery after total knee arthroplasty. *Orthopedics* 32:884–890
- Huddleston JI, Scott RD, Wimberley DW (2005) Determination of neutral tibial rotational alignment in rotating platform TKA. *Clin Orthop Relat Res* 440:101–106
- Ikeuchi M, Yamanaka N, Okanou Y, Ueta E, Tani T (2007) Determining the rotational alignment of the tibial component at total knee replacement: a comparison of two techniques. *J Bone Jt Surg* 89B:45–49
- Iranpour F, Merican AM, Dandachli W, Amis AA, Cobb JP (2010) The geometry of the trochlear groove. *Clin Orthop Relat Res* 468:782–788
- Lewis P, Rorabeck CH, Bourne RB, Devane P (1994) Postero-medial tibial polyethylene failure in total knee replacements. *Clin Orthop Relat Res* 299:11–17
- Lutzner J, Krummenauer F, Gunther KP, Kirschner S (2010) Rotational alignment of the tibial component in total knee arthroplasty is better at the medial third of tibial tuberosity than at the medial border. *BMC Musculoskelet Disord* 11:57
- Nagamine R, Miyamishi K, Miura H, Urabe K, Matsuda S, Iwamoto Y (2003) Medial torsion of the tibia in Japanese patients with osteoarthritis of the knee. *Clin Orthop Relat Res* 408:218–224
- Noble PC, Conditt MA, Cook KF, Mathis KB (2006) The John Insall award: patient expectations affect satisfaction with total knee arthroplasty. *Clin Orthop Relat Res* 452:35–43
- Parratte S, Pagnano MW, Trousdale RT, Berry DJ (2010) Effect of postoperative mechanical axis alignment on the fifteen-year survival of modern, cemented total knee replacements. *J Bone Joint Surg* 92A:2143–2149
- Siston RA, Goodman SB, Patel JJ, Delp SL, Giori NJ (2006) The high variability of tibial rotational alignment in total knee arthroplasty. *Clin Orthop Relat Res* 452:65–69
- Tang WM, Zhu YH, Chiu KY (2000) Axial alignment of the lower extremity in Chinese adults. *J Bone Joint Surg* 82A:1603–1608
- Uehara K, Kadoya Y, Kobayashi A, Ohashi H, Yamano Y (2002) Bone anatomy and rotational alignment in total knee arthroplasty. *Clin Orthop Relat Res* 402:196–201
- Weber WE, Weber EFM (1836) *Mechanik der menschlichen Gehwerkzeuge (Mechanics of the human walking apparatus)*. Verlag der Dietrichschen Buchhandlung, Göttingen
- Yip DK, Zhu YH, Chiu KY, Ng TP (2004) Distal rotational alignment of the Chinese femur and its relevance in total knee arthroplasty. *J Arthroplast* 19:613–619