

# **Transtibial Surgical Technique for Placement of the Femoral Tunnel in the **I.D.E.A.L. Position****

Rationale and Technique  
Using the Anatomy Specific Tibial Guide,  
EZLoc Fixation, and WasherLoc Tibial Fixation

Surgical Protocol by  
Stephen M. Howell, M.D.



**BIOMET**

## One Surgeon. One Patient.

**Over 1 million times per year, Biomet helps one surgeon provide personalized care to one patient.**

The science and art of medical care is to provide the right solution for each individual patient. This requires clinical mastery, a human connection between the surgeon and the patient, and the right tools for each situation.

At Biomet, we strive to view our work through the eyes of one surgeon and one patient. We treat every solution we provide as if it's meant for a family member.

Our approach to innovation creates real solutions that assist each surgeon in the delivery of durable personalized care to each patient, whether that solution requires a minimally invasive surgical technique, advanced biomaterials or a patient-matched implant.

**When one surgeon connects with one patient to provide personalized care, the promise of medicine is fulfilled.**

# Transtibial Surgical Technique for Placement of the Femoral Tunnel in the I.D.E.A.L. Position

## Table of Contents

---

<b>Introduction and Design Rationale.....</b>	<b>2</b>
Tibial Tunnel Considerations for Placing the Femoral Tunnel in the I.D.E.A.L. Location with the Transtibial Technique.....	3
Two Steps for Limiting PCL Impingement .....	4-5
Steps for Limiting Roof Impingement.....	6
Steps for Replicating the Low Tension-Flexion Pattern of the Native ACL.....	7-8
<b>Surgical Technique.....</b>	<b>9</b>
Place the Medial Portal .....	10
Widen the Notch .....	11
Insert the Anatomy Specific Tibial Guide.....	12
Position the Guide in the Sagittal Plane.....	13
Adjust the Angle of the Tibial Guide in the Coronal Plane.....	13
Assess the Position of the Tibial Guide Pin.....	14
Check for Roof Impingement .....	15
Prepare the Pilot Hole for the Counter Bore .....	16
Ream the Counter Bore.....	17
Remove the ACL Origin from the Femur .....	18
Position the Size-Specific Femoral Aimer .....	18
Redirect the Femoral Guide Pin with the Knee in 90° or More of Flexion.....	19
Assess Placement of Femoral Guide Pin.....	19
Ream an Open Ended Femoral Tunnel .....	20
Measure the Length of the Open-Ended Femoral Tunnel.....	21
Choose the Length of the EZLoc Femoral Fixation Device .....	21
Pass the Soft-Tissue ACL Graft.....	22-23
Confirm Fixation in the Femoral Tunnel.....	24
Select the Correct Size WasherLoc Device .....	24
Tension the Graft and Impact the WasherLoc Device.....	25-26
Drill, Measure and Insert the Cancellous Compression Screw.....	27-28
<b>Ordering Information .....</b>	<b>29-31</b>
<b>Indications/Contraindications.....</b>	<b>32</b>
<b>References .....</b>	<b>33</b>

# Rationale for the I.D.E.A.L. Femoral Tunnel Position

A general consensus from *in vitro* and *in vivo* studies is that the ideal placement of the femoral tunnel for the ACL graft should be Isometric, in the Direct Fibers, Eccentrically located high and deep within the footprint, Equidistant between the top and bottom of the notch, Anatomic, and Low in Tension. "I.D.E.A.L." is a useful acronym for intraoperatively judging the position of the guide pin for placing the femoral tunnel, which applies to the transtibial, anteromedial portal, or two-incision surgical techniques.

The two intraoperative checks for judging the I.D.E.A.L. placement of the femoral tunnel is when the femoral guide pin is 1) Equidistant between the top and bottom of the notch in the green zone, and 2) far enough posterior so the femoral tunnel has a  $\leq 1$  mm tunnel backwall<sup>1,2</sup> (Figure 1).

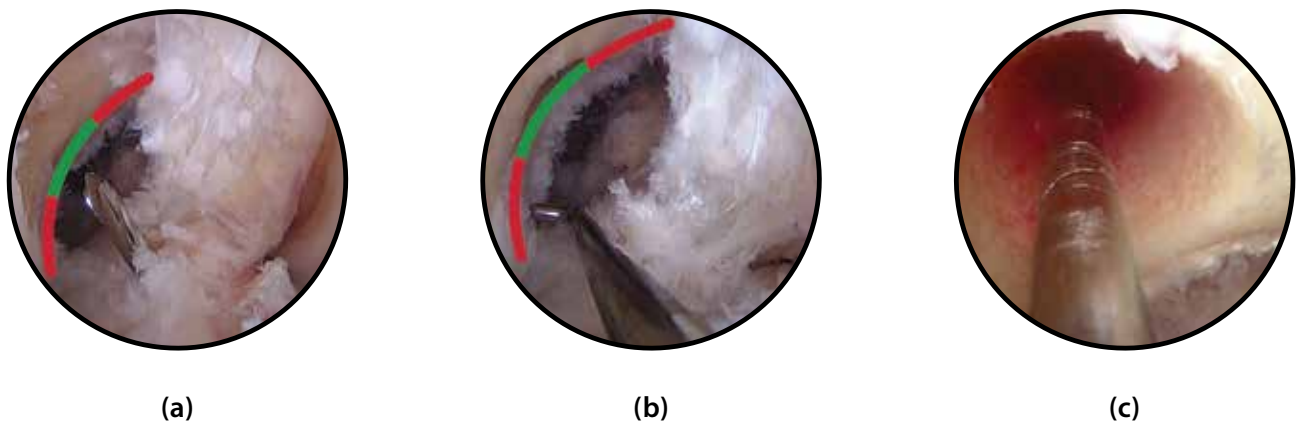


Figure 1

● Green Zone ● Red Zone Tunnel Too Vertical or Low

An arthroscopic view of the notch of a right knee at 90° of flexion shows the I.D.E.A.L. placement of the femoral tunnel guide pin centered within the **green zone** (a), which places the femoral tunnel within the boundaries of the green zone (b) and with a  $\leq 1$  mm backwall (c). A guide pin placed too vertical or above the **green zone** may cause the boundary of the femoral tunnel to extend into the **red zones**, which should be avoided because an ACL graft in the **red zone** has high tension that may cause undesirable loss of motion or stretch of the ACL graft.<sup>1,4,6</sup>

Centering the femoral guide pin within the green zone has the advantages of Isometrically setting graft length,<sup>1,3,4</sup> Anatomically centering the graft in the Direct Fibers of the origin of the native ACL,<sup>5</sup> and matching the Low tension-flexion pattern of the native ACL.<sup>1,4,6</sup> Each are important for restoring high function, full motion, and stability.<sup>2,7</sup>

## Tibial Tunnel Considerations for Placing the Femoral Tunnel in the I.D.E.A.L. Location with the Transtibial Technique

Reliably performing the transtibial technique depends on appropriate placement of the tibial tunnel in both the coronal and sagittal planes. Correct placement of the tibial tunnel requires 1) customizing the width of the space between the lateral femoral condyle and PCL to fit the transverse diameter of the ACL graft, and 2) correct use of the Anatomy Specific Tibial Guide (Figure 2).

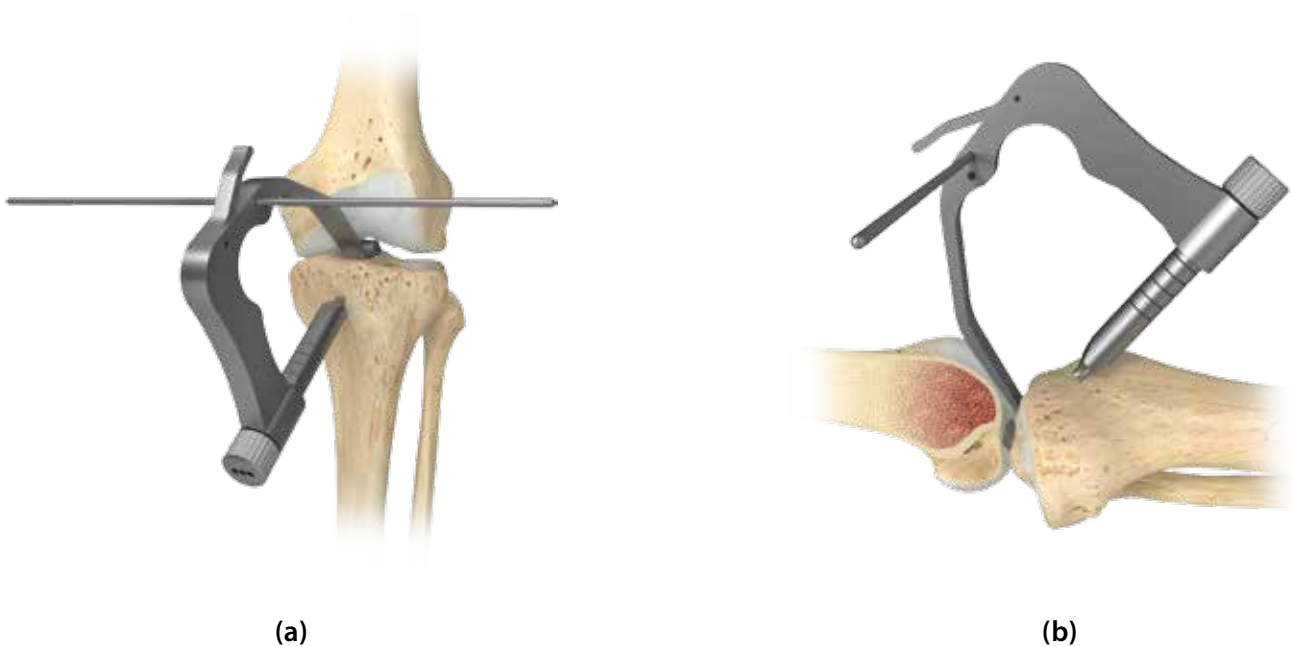


Figure 2

The Anatomy Specific Tibial Guide places the tibial tunnel in the coronal (a) and sagittal (b) planes and enables an I.D.E.A.L. placement of the femoral tunnel with the transtibial technique.

When the space between the lateral femoral condyle and PCL is widened to fit the diameter of the ACL graft and the tibial tunnel is correctly positioned, the insertion of a size-specific offset femoral aimer through the tibial tunnel reliably places the femoral tunnel guide pin equidistant from the top and bottom of the intercondylar notch with a <1 mm backwall.<sup>1,2,7</sup> These four steps help limit PCL and roof impingement, and replicate the low tension-flexion pattern of the native ACL.<sup>1,2,7,8,9,10,11</sup>

## Two Steps for Limiting PCL Impingement

### Adjust the Width of the Space Between the Lateral Femoral Condyle and PCL

The transverse diameter of an ACL graft is typically larger than the width of the space between the lateral femoral condyle and PCL.<sup>2</sup> Widening the space limits impingement of the ACL graft against the lateral femoral condyle and PCL by allowing lateralization of the femoral tunnel. Bone is removed from the lateral femoral condyle until the space exceeds the diameter of the ACL graft by 1 mm, which is confirmed by measuring the space with the 9.5 mm wide tip of the Anatomy Specific Tibial Guide (Figure 3).




Figure 3

An arthroscopic view of the notch of a right knee at 90° flexion (a). Figure 3(b) shows the 9.5 mm wide tip of the Anatomy Specific Tibial Guide assessing the space between the lateral femoral condyle and the PCL, and (c) shows a widened space that exceeds the diameter of the ACL graft by 1 mm.

## Two Steps for Limiting PCL Impingement (cont.)

### Align the Tibial Tunnel 65° From the Medial Joint Line of the Tibia

Alignment of the tibial tunnel at  $65 \pm 5^\circ$  from the medial joint line of the tibia in the coronal plane limits PCL impingement by confining the boundary of the femoral tunnel and ACL graft within the green zone.<sup>1</sup> Not customizing the width of the space and aligning the tibial tunnel more vertical than ( $70^\circ$ ) places the boundary of the femoral tunnel above the green zone, which may cause the ACL graft to impinge against the PCL during knee flexion (Figure 4).<sup>1,7</sup>

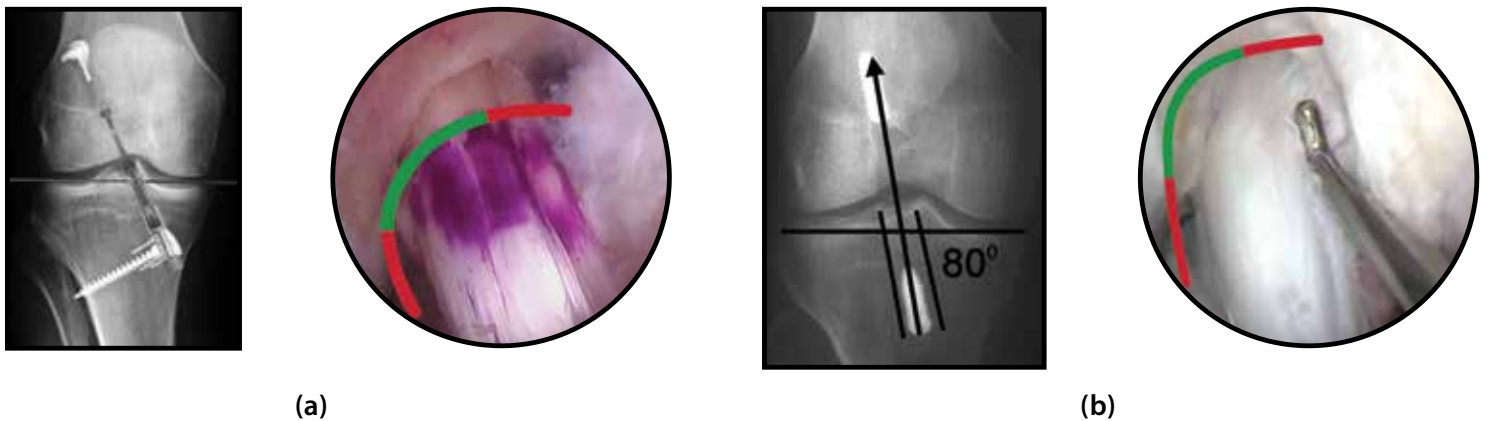


Figure 4

The use of a  $65^\circ$  tibial tunnel in a right knee places the boundary of the femoral tunnel and ACL graft within the green zone and limits PCL impingement (a). A tibial tunnel more vertical than  $70^\circ$  places the boundary of the femoral tunnel and ACL graft above the green zone and may cause PCL impingement (b).

Preventing PCL impingement allows for improved flexion, restored stability and normal walking mechanics, and allows for replication of the low tension-flexion pattern of the native ACL.<sup>1,7,12</sup>

## Steps for Limiting Roof Impingement

In the sagittal plane, placement of the anterior boundary of the tibial tunnel 1–2 mm posterior and parallel to the intercondylar roof in the extended knee, limits roof impingement and places the ACL graft anatomically within the boundary of the native ACL. Because the angle of the intercondylar roof and knee extension varies widely between patients, adjustment of the anteroposterior position and angle of the tibial tunnel is required to match the patient's unique combination of roof angle and knee extension (Figure 5).<sup>8,9,11</sup>




Figure 5

The Anatomy Specific Tibial Guide limits roof impingement by adjusting the anteroposterior position and angle of the tibial tunnel in the sagittal plane to the patient. The patient with the 23° roof angle (a) requires a more posterior tibial tunnel than the patient with a 45° roof angle (b).

Preventing roof impingement improves extension, stability, and the MRI appearance of the graft.<sup>8-11,13-18</sup>



## Steps for Replicating the Low Tension-Flexion Pattern of the Native ACL

An ACL graft should replicate the low tension-flexion pattern of the native ACL.<sup>1,6</sup> When performing the transtibial technique, the angle of the tibial tunnel from the medial joint line of the tibia in the coronal plane determines the tension-flexion pattern of the ACL graft. An ACL graft in a 65° tibial tunnel has the desired low tension-flexion pattern. A more vertical ACL graft in a tibial tunnel (>75°) has a higher tension-flexion pattern than the native ACL (Figure 6).<sup>1</sup> A lower ACL graft in a tibial tunnel (~<45°) has a higher tension-flexion pattern than the native ACL (Figure 6).<sup>6</sup>

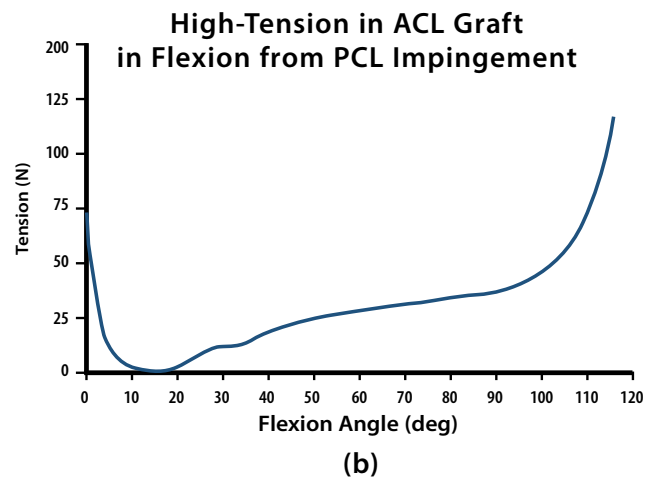
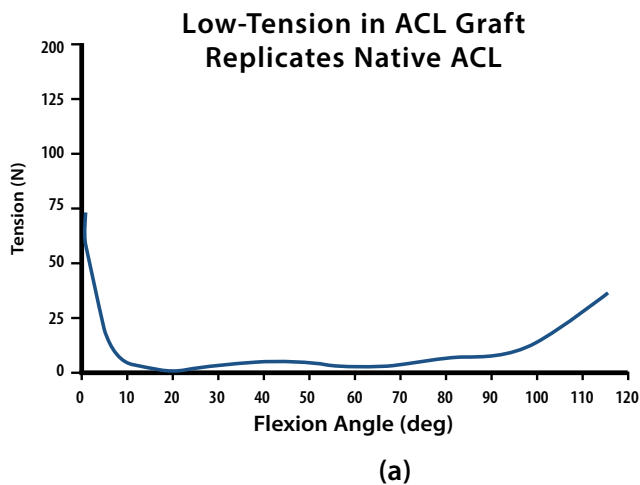
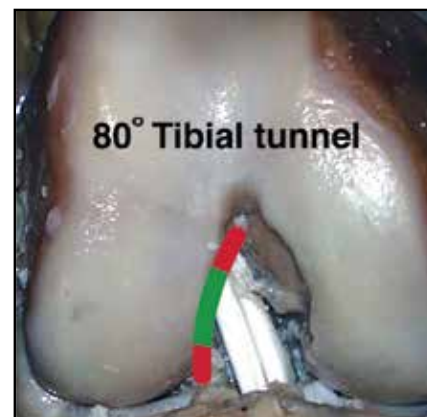
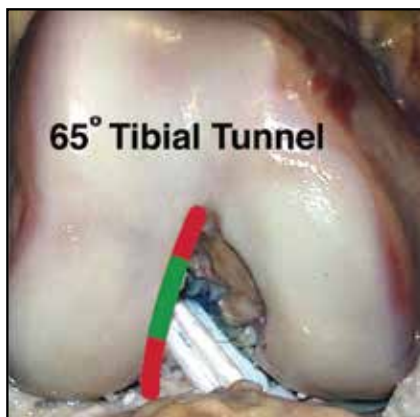


Figure 6<sup>1</sup>

An ACL graft placed in a 65° tibial tunnel with the transtibial technique replicates the low tension-flexion pattern of the native ACL because the boundary of the femoral tunnel is within the green zone (a). An ACL graft placed in an 80° tibial tunnel has a high tension-flexion pattern because the boundary of the ACL graft and femoral tunnel is in the red zone, above the green zone (b).<sup>1</sup>

## Steps for Replicating the Low Tension-Flexion Pattern of the Native ACL (cont.)

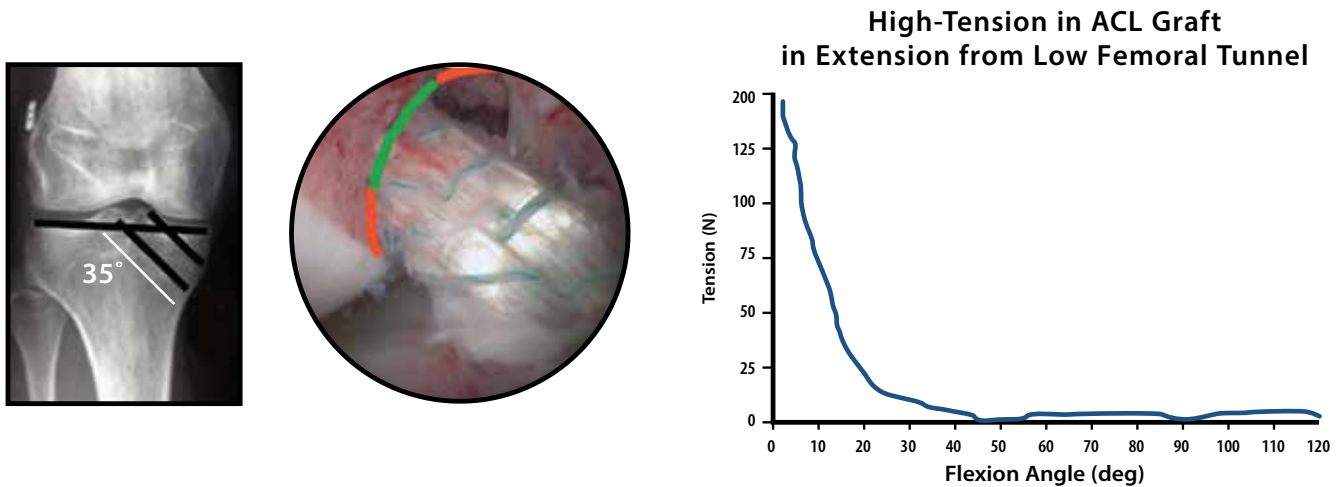


Figure 7<sup>1</sup>

An ACL graft placed in a 35° tibial tunnel with the anteromedial portal technique has a high tension-flexion pattern because the boundary of the ACL graft and femoral tunnel is in the red zone, below the green zone.<sup>1</sup>

An ACL graft with a higher tension in extension or in flexion than the native ACL may have many undesirable consequences including loss of extension and flexion,<sup>7</sup> instability from stretching of the ACL graft due to PCL impingement,<sup>6,7</sup> slippage at the sites of graft fixation,<sup>21,22</sup> excessive graft wear at the femoral tunnel,<sup>23</sup> myxoid degeneration and inferior mechanical properties of the graft,<sup>25</sup> and posterior subluxation of the tibia.<sup>21,25</sup>

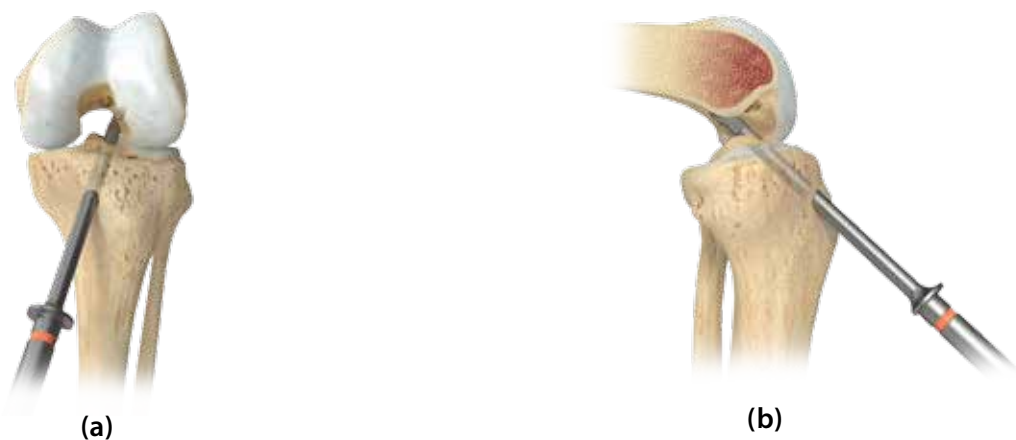


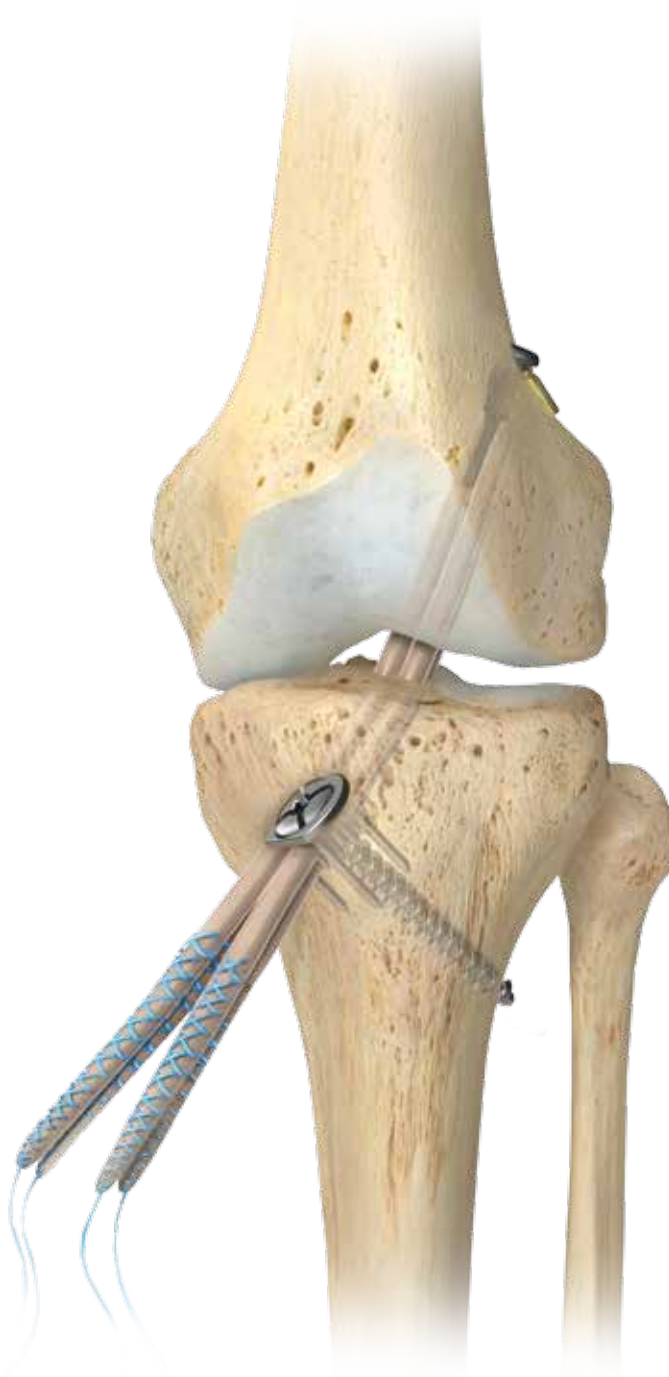Figure 8

A size-specific femoral aimer that matches the diameter of the ACL graft and inserted through a correctly positioned tibial tunnel in both the coronal and sagittal planes reliably replicates the low tension-flexion pattern of tension of the native ACL (Figure 8).<sup>1,26</sup> The size-specific femoral aimer positions the femoral guide pin in the green zone (a) and creates a femoral tunnel with a <1 mm backwall (b).

# Transtibial ACL Reconstruction with the **Anatomy Specific Tibial Guide**, **EZLoc Femoral Fixation**, and **WasherLoc Tibial Fixation**

Surgical Technique

Surgical Protocol by  
Stephen M. Howell, M.D.



# Transtibial ACL Reconstruction with the Anatomy Specific Tibial Guide, EZLoc Femoral Fixation, and WasherLoc Tibial Fixation

## Surgical Technique

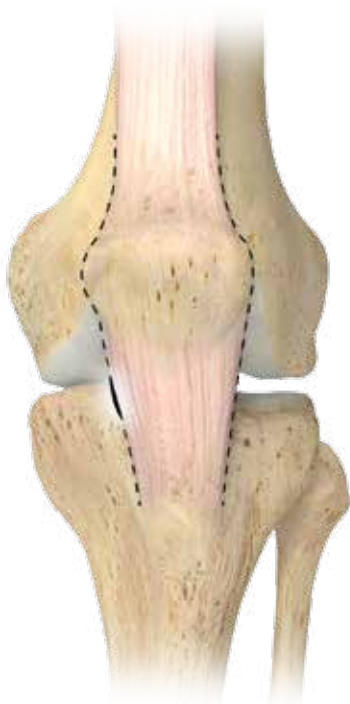

Figure 1a

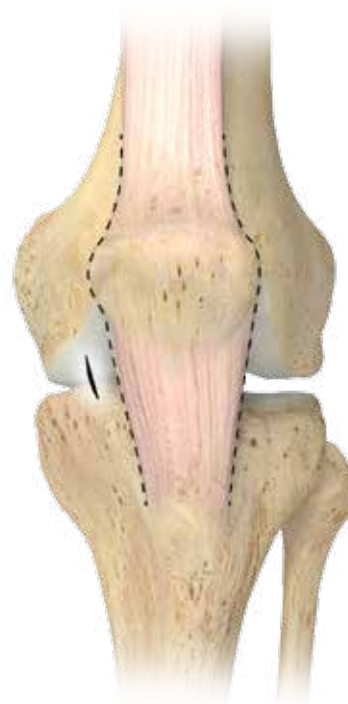

Figure 1b

### Place the Medial Portal

Mark the medial and lateral edge of the patellar tendon. Place the medial portal at the medial edge of the patellar tendon (Figure 1a).

The Anatomy Specific Tibial Guide is difficult to place in the intercondylar notch when the portal is more medial to the patellar tendon (Figure 1b). Alternatively, the tibial guide can be inserted through the patellar tendon defect when a BTB graft is harvested.

This material represents the surgical technique utilized by Stephen M. Howell, MD. Biomet does not practice medicine and does not recommend any particular orthopedic implant or surgical technique for use on a specific patient. The treating surgeon is responsible for determining the appropriate treatment, technique(s), and product(s) for each individual patient.

The Anatomy Specific Tibial Guide, EZLoc, and WasherLoc were developed in conjunction with Stephen M. Howell, M.D., Sacramento, California.

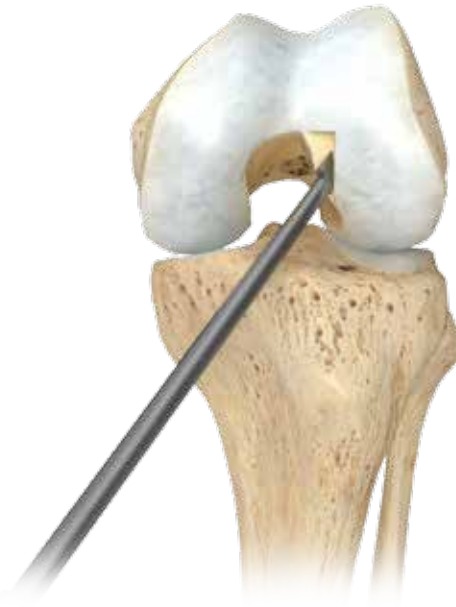

Figure 2

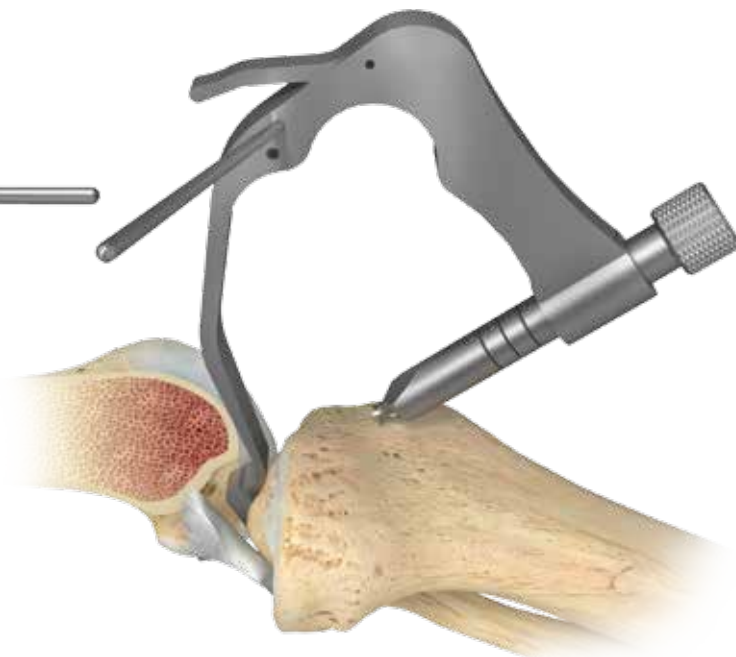
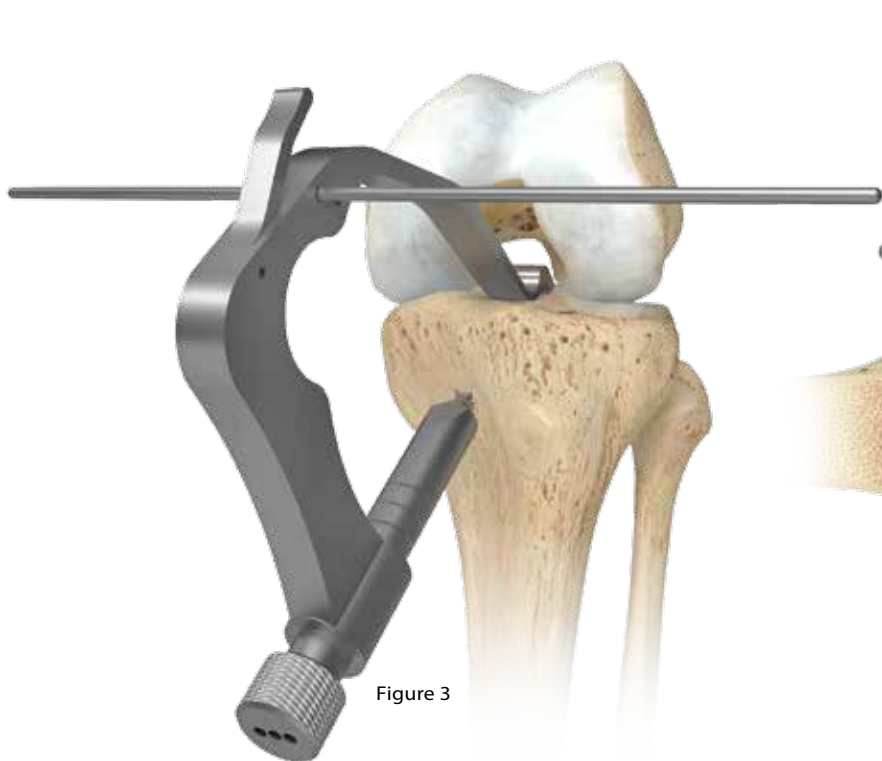
## Widen the Notch

Remove the remnant of the torn ACL to clearly see the lateral edge of the PCL. Insert the Anatomy Specific Tibial Guide through the medial portal or patellar tendon defect with the knee in flexion. Use the 9.5 mm wide tip of the guide to gauge the width of the space between the PCL and lateral femoral condyle. Remove bone from the lateral femoral condyle (i.e. wallplasty) using the angled osteotome through the medial portal until the space exceeds the diameter of the graft by 1 mm (Figure 2).

Avoid performing a roofplasty because this changes the roof angle, which changes the reference for the Anatomy Specific Tibial Guide in the sagittal plane.

# Transtibial ACL Reconstruction with the Anatomy Specific Tibial Guide, EZLoc Femoral Fixation, and WasherLoc Tibial Fixation

## Surgical Technique



### Insert the Anatomy Specific Tibial Guide

Reinsert the Anatomy Specific Tibial Guide through the medial portal. Position the tip of the guide in the space between the PCL and the lateral femoral condyle (Figure 3). Position the bump inside the notch facing the intercondylar roof.

Slowly extend the knee while arthroscopically confirming the bump on the tip of the guide remains inside the notch (Figure 4). Maintain the knee in hyperextension by placing the heel on a raised Mayo stand. Suspending the knee by placing the heel on the Mayo stand allows gravity to reduce the tibia on the femur.<sup>13,15</sup>

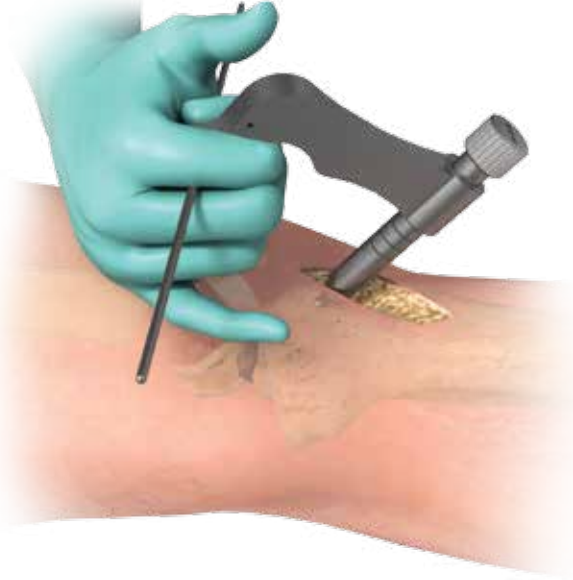

Figure 5

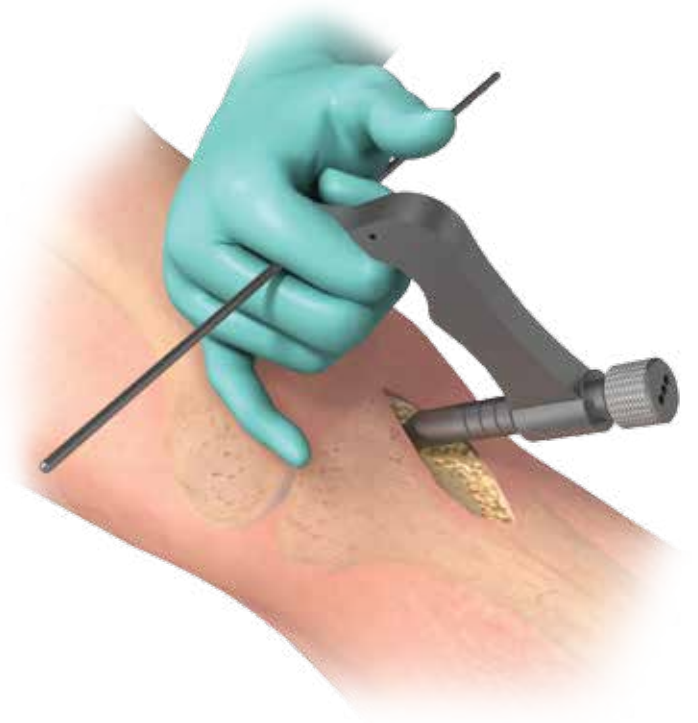


Figure 6

## Position the Tibial Guide in the Sagittal Plane

Grasp the handle of the guide with the long and ring fingers and rest the hypothenar area of the hand on the patella. Seat the guide by gently lifting the handle toward the ceiling until the bump and arm of the guide abuts the trochlear groove. Simultaneously press the patella into the trochlear groove, thereby hyperextending the knee (Figure 5). This maneuver adjusts the angle and position of the guide in the sagittal plane by accommodating the specific roof angle and knee extension of the patient.

## Adjust the Angle of the Tibial Guide in the Coronal Plane

From the lateral side of the guide, insert the alignment rod into the proximal hole in the handle. Position the alignment rod parallel to the joint line and perpendicular to the long axis of the tibia, which angles the tibial tunnel at 65° with respect to the medial joint line of the knee (Figure 6). Insert the drill sleeve until it touches the superficial MCL overlying the posteromedial tibia. Drill a 2.4 mm drill tip guide pin through the lateral hole in the drill sleeve until it stops at the broad tip of the guide. Remove the tibial guide.



# Transtibial ACL Reconstruction with the Anatomy Specific Tibial Guide, EZLoc Femoral Fixation, and WasherLoc Tibial Fixation

## Surgical Technique

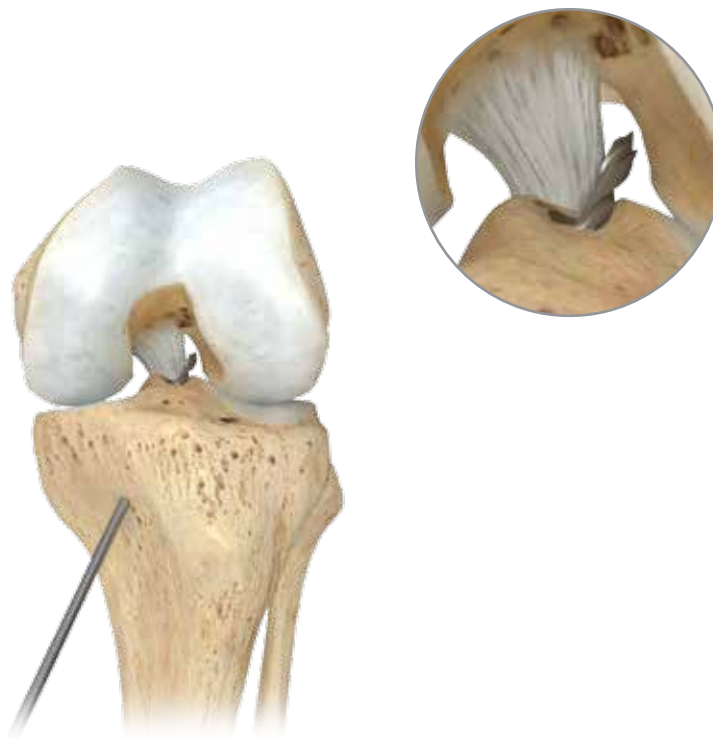

Figure 7

### Assess the Position of the Tibial Guide Pin

Flex the knee, insert the arthroscope, and tap the guide pin into the notch. Assess the placement of the guide pin with the knee in 90° of flexion. The two checkpoints for correct placement of the guide pin are, 1) the pin is located midway between the lateral edge of the PCL and the lateral femoral condyle, and 2) the tip of the pin is equidistant from the apex and base of the notch, centered in the green zone (Figure 7 & 7a).

In the sagittal plane the checkpoint for the correct placement of the guide pin is that a 2 mm wide nerve hook pistons 2 mm between the anterior surface of the guide pin and intercondylar roof with the knee in full extension.



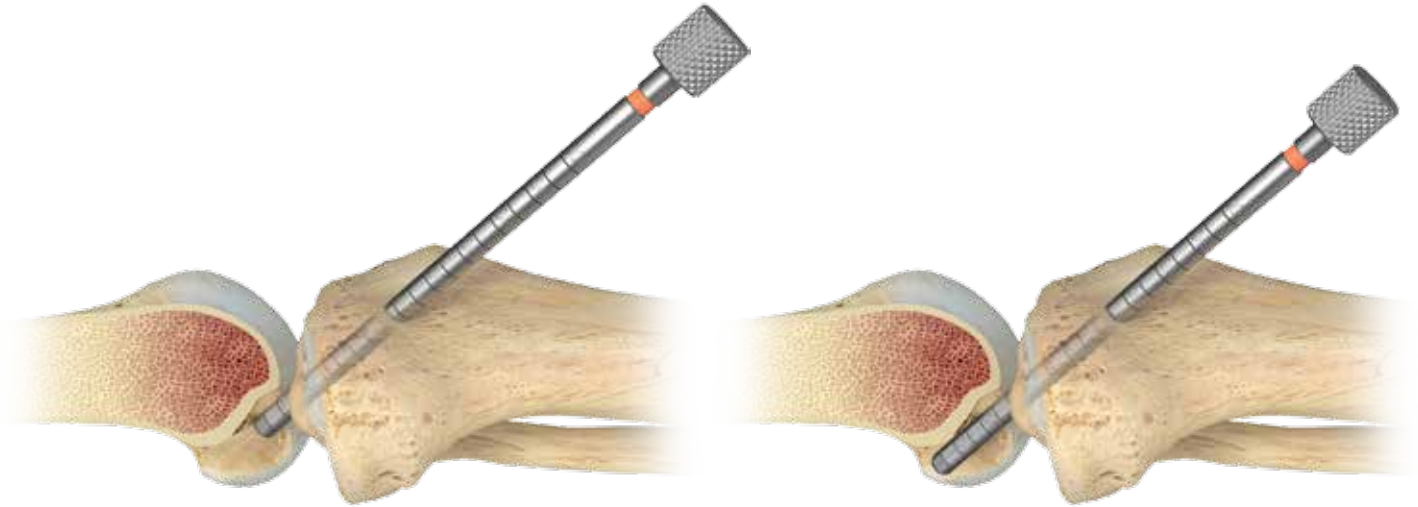

Figure 8

Figure 8a

## Check for Roof Impingement

Drill the tibial tunnel with a cannulated reamer that matches the diameter of the graft. Place the knee in maximum extension and insert an impingement rod the same diameter as the ACL graft through the tibial tunnel and into the notch.

The checkpoint that roof impingement has been avoided is free passage of the impingement rod into the notch (Figure 8, 8a).

# Transtibial ACL Reconstruction with the Anatomy Specific Tibial Guide, EZLoc Femoral Fixation, and WasherLoc Tibial Fixation

## Surgical Technique

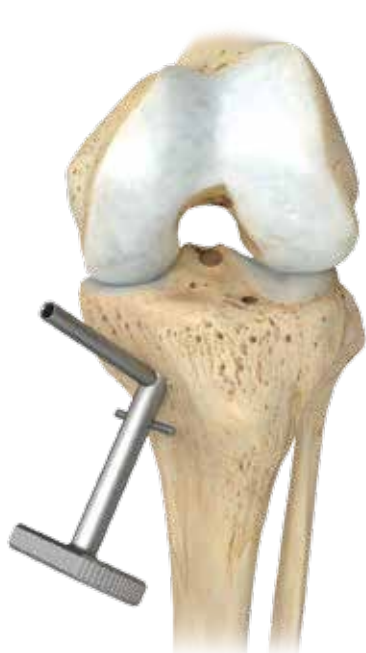

Figure 9

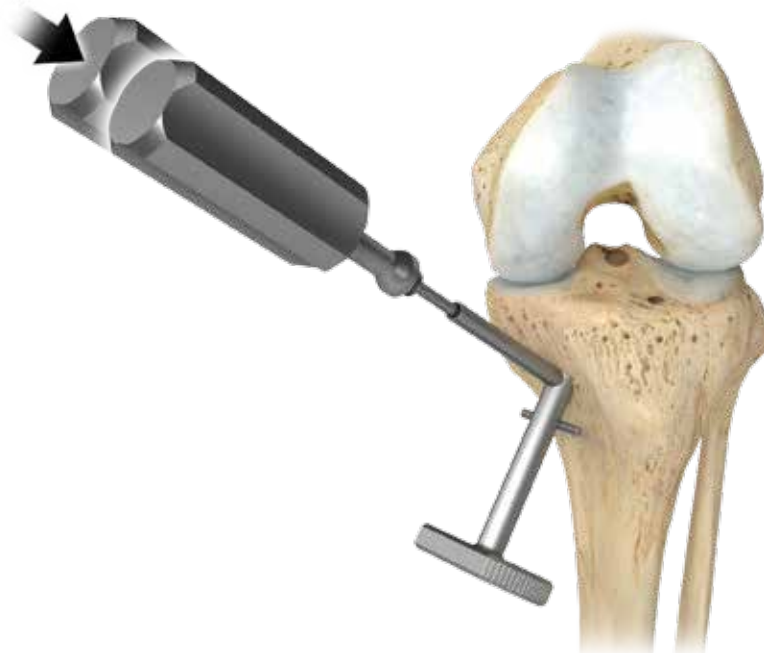


Figure 10

### Prepare the Pilot Hole for the Counter Bore

Remove a 17 x 17 mm section of the superficial layer of the MCL centered on the cortical opening of the tibial tunnel. Insert the counter bore guide into the tibial tunnel until the vertical sleeve abuts the distal end of the anterior edge of the tibial tunnel. Rotate the counter bore guide until the vertical sleeve points towards the fibula (Figure 9).

Impact and fully seat the awl in the sleeve (Figure 10). Preserve the orientation of the awl by removing the counter bore guide and reinserting the awl into the pilot hole at the same angle. The awl should be perpendicular to the posterior wall of the tibial tunnel and point toward the fibula.

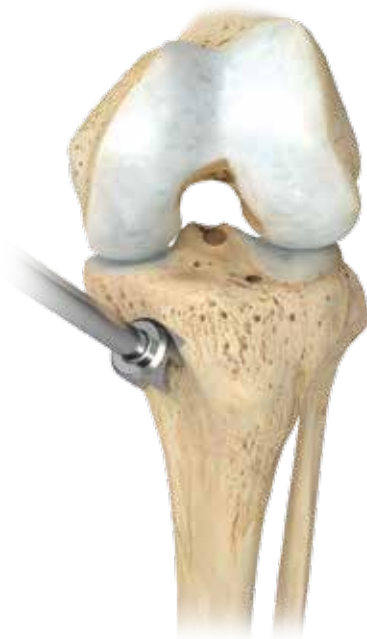

Figure 11

## Ream the Counter Bore

Remove the awl and insert the tip of the counter bore. Maintain the cutting surface of the counter bore parallel to the posterior wall of the tibial tunnel and aim toward the fibula. Ream until the counter bore is flush with the posterior wall of the tibial tunnel (Figure 11).

# Transtibial ACL Reconstruction with the Anatomy Specific Tibial Guide, EZLoc Femoral Fixation, and WasherLoc Tibial Fixation

## Surgical Technique

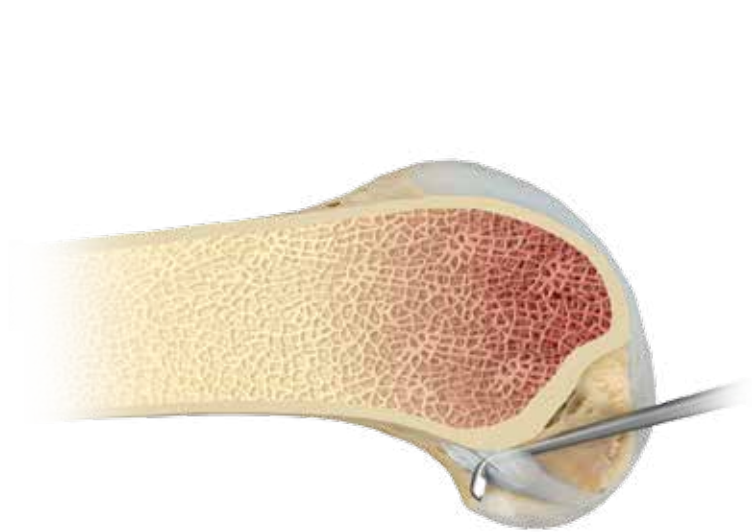


Figure 12

### Remove the ACL Origin from the Femur

Insert the angled curette through the medial portal and into the over-the-top position on the femur. Remove the remnant of the native ACL down to bone, which allows the tip of the femoral aimer to rest on bone instead of soft tissue and minimizes blowout of the posterior wall of the femoral tunnel (Figure 12).

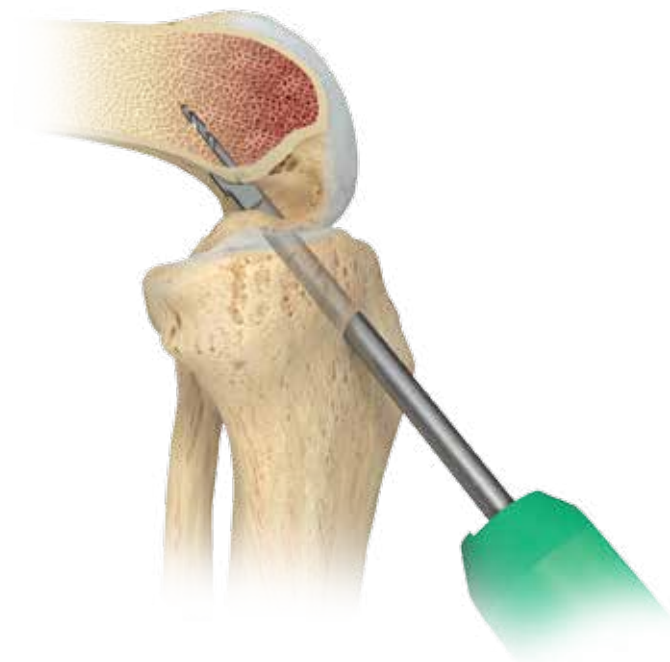


Figure 13

### Position the Size-Specific Femoral Aimer

Select the Size-Specific Femoral Aimer that corresponds to the diameter of the ACL graft. Insert the femoral aimer through the tibial tunnel and into the notch. Adjust knee flexion until the tip of the aimer passes into the over-the-top position. Let gravity flex the knee, which locks the femoral aimer in place (Figure 13). The flexion angle that locks the aimer in place ranges from 60–100°. Internally and externally rotate the femoral aimer until the tip of the aimer is equidistant from the apex and base of the notch. Drill the guide pin 5-10 mm into the femur to create a pilot hole. Remove the femoral aimer and guide pin.

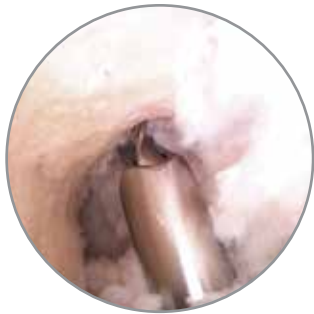

Figure 14

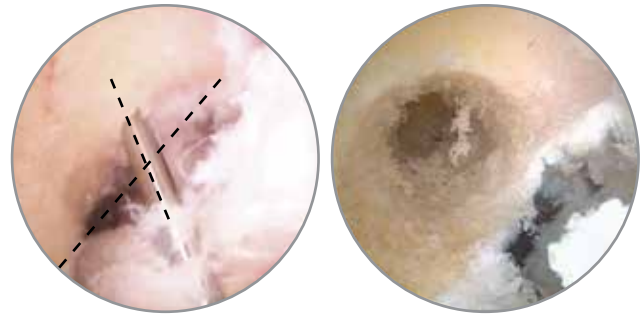


Figure 15

## Redirect the Femoral Guide Pin with the Knee in 90° or More of Flexion

Surgeons who use the EZLoc Femoral Fixation Device can adjust the length of the femoral tunnel to between 35 and 50 mm by redirecting the femoral guide pin with the knee in more flexion. Adjust the length by re-inserting the femoral guide pin through the tibial tunnel and into the pilot hole in the femur. Flex the knee to 90° or more and angulate the guide pin distal/medial to proximal/lateral. Drill the guide pin in this orientation to create a femoral tunnel between 35–50 mm in length.

## Assess Placement of Femoral Guide Pin

Placement of the femoral guide pin vertical, near the roof of the notch is incorrect, and is confirmed by the boundary of the femoral tunnel extending above the green zone (Figure 14). Correct placement centers the guide pin further down the sidewall of the lateral femoral condyle equidistant between the apex and base of the notch (Figure 15). To check for equidistant placement, insert the one-inch femoral reamer into the notch and confirm the tip of the reamer passes by the PCL without touching it. The reamer should form a triangular space with the lateral border of the PCL.

# Transtibial ACL Reconstruction with the Anatomy Specific Tibial Guide, EZLoc Femoral Fixation, and WasherLoc Tibial Fixation

## Surgical Technique

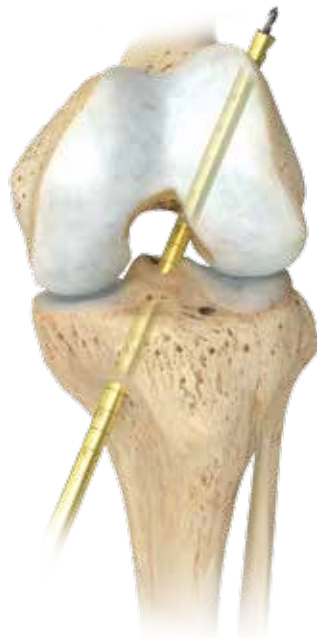

Figure 16

### Ream an Open Ended Femoral Tunnel

Ream an open-ended femoral tunnel by inserting a one-inch femoral reamer through the tibial tunnel over the guide pin (Figure 16). Piston the one-inch femoral reamer in and out of the femoral tunnel while reaming to clean the flutes, which creates a smooth hole through the anterolateral cortex of the femur for unobstructed passage of the EZLoc Femoral Fixation Device.

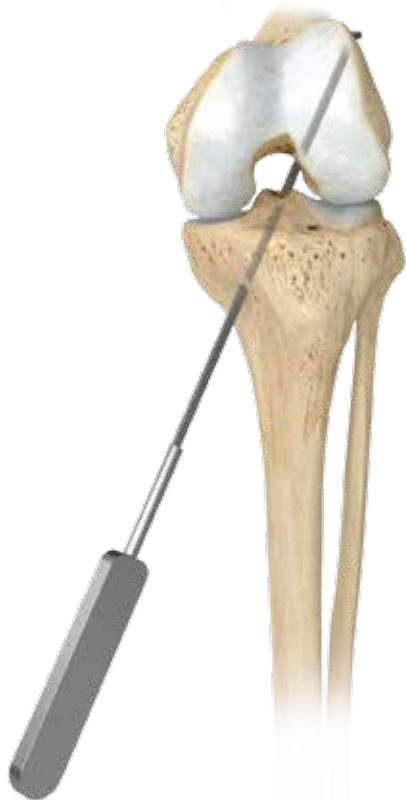

Figure 17

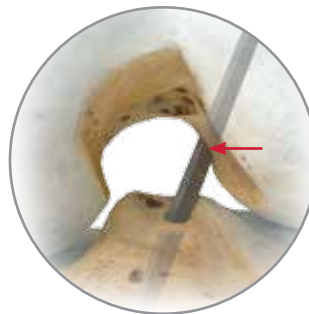

Figure 17a

## Measure the Length of the Open-Ended Femoral Tunnel

Pass the femoral tunnel depth gauge through the tibial tunnel, intercondylar notch, and femoral tunnel. Hook the tip of the depth gauge on the lateral wall of the femoral tunnel (Figure 17). Read the length on the depth gauge at the distal end of the femoral tunnel where it exits the intercondylar notch (Figure 17a).

## Choose the Length of the EZLoc Femoral Fixation Device

If the femoral tunnel length is <35 mm, then use the short EZLoc. If the femoral tunnel length is between 35 and 50 mm, then use the standard EZLoc. If the femoral tunnel length is longer than 50 mm, then use the long EZLoc. The table below computes the length of the ACL graft for combinations of the length of the EZLoc and femoral tunnel.

LENGTH OF EZLOC DEVICE	FEMORAL TUNNEL LENGTH	LENGTH OF GRAFT IN FEMORAL TUNNEL (FT)
SHORT (7 mm)	35 mm OR SHORTER	35 mm FT – 7 mm = 28 mm of Graft in Tunnel
STANDARD (12 mm)	35 – 50 mm	45 mm FT – 12 mm = 33 mm of Graft in Tunnel
LONG (22 mm)	50 mm OR LONGER	55 mm FT – 22 mm = 33 mm of Graft in Tunnel

# Transtibial ACL Reconstruction with the Anatomy Specific Tibial Guide, EZLoc Femoral Fixation, and WasherLoc Tibial Fixation

## Surgical Technique

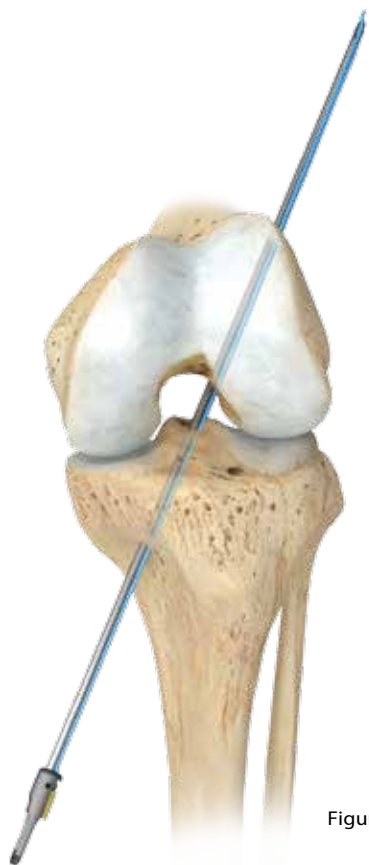

Figure 18




Figure 19

Figure 20

### Pass the Soft-Tissue ACL Graft

The EZLoc device is sterilely prepackaged and connected to a passing pin by a suture tied under tension. Insert the passing pin through the tibial and femoral tunnels and pass the sharp tip through the skin of the anterolateral thigh (Figure 18).

Orient the gold lever arm lateral, and loop the soft tissue ACL graft halfway through the EZLoc device (Figure 19). Mark the length of the femoral tunnel on the ACL graft by measuring from the distal tip of the lever arm (Figure 20).



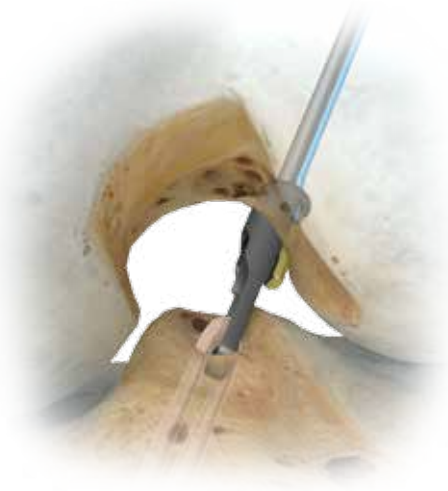

Figure 21

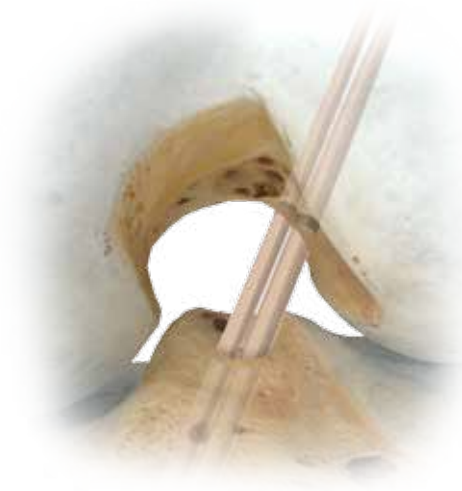


Figure 22

## Pass the Soft-Tissue ACL Graft (cont.)

Pull the passing pin proximally until the lever arm is at the entrance of the femoral tunnel. Rotate the EZLoc device until the lever arm points lateral (Figure 21). Pull the EZLoc device until the mark on the ACL graft enters the femoral tunnel (Figure 22).

# Transtibial ACL Reconstruction with the Anatomy Specific Tibial Guide, EZLoc Femoral Fixation, and WasherLoc Tibial Fixation

## Surgical Technique

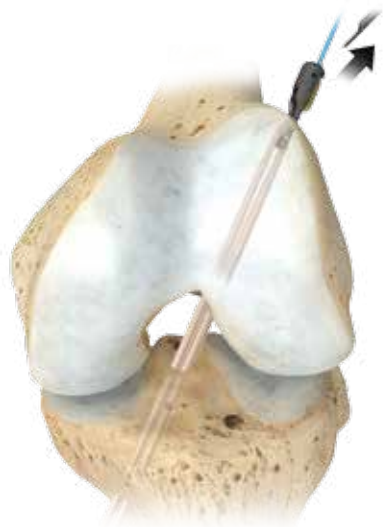

Figure 23



Figure 24

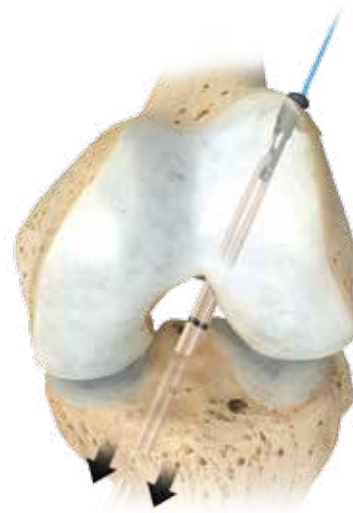

Figure 25




Figure 26

### Confirm Fixation in the Femoral Tunnel

Cut the suture and remove the passing pin from the EZLoc device (Figure 23). Pull on the suture to deploy the lever arm (Figure 24). Apply counter tension on the distal end of the soft tissue ACL graft (Figure 25). Feel the firm, solid grip of the lever arm on the lateral femoral cortex, which confirms the EZLoc device is deployed and the ACL graft is rigidly fixed on the cortical bone.

### Select the Correct Size WasherLoc Device

Select the 16 mm Extended Spike WasherLoc for a 7 or 8 mm diameter graft. Select the 18 mm Extended Spike WasherLoc for a 9 or 10 mm diameter graft. Thread the WasherLoc device on the drill guide and thread the drill guide on the awl (Figure 26).

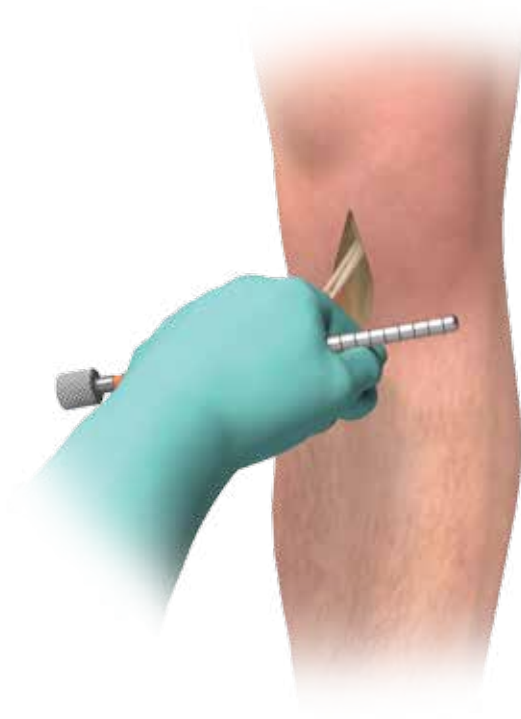

Figure 27

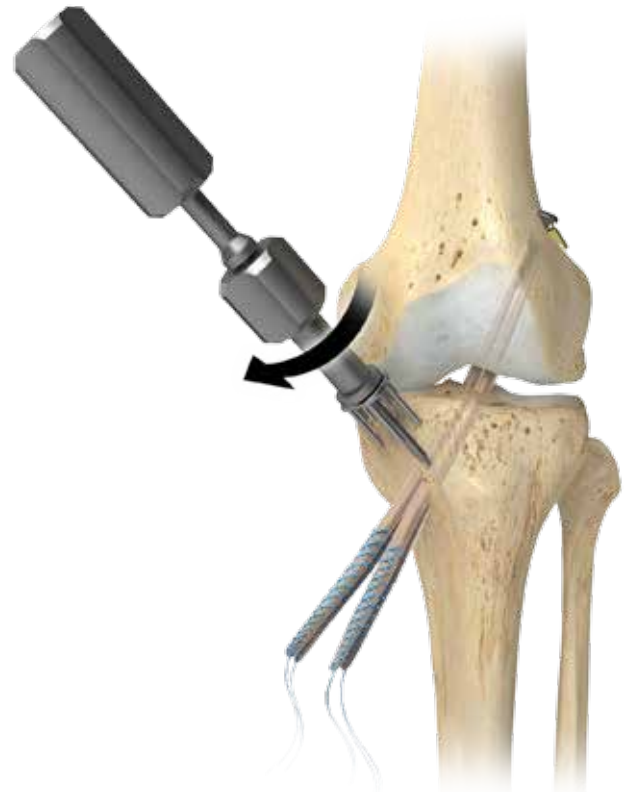

Figure 28

## Tension the Graft and Impact the WasherLoc Device

With the ACL graft fixed to the femur with the EZLoc Femoral Fixation Device, manually tension the graft exiting the tibial tunnel and cycle the knee between full extension to maximum flexion. Tensioning the graft and cycling the knee seats the EZLoc Device and removes slack in the graft. Place and maintain the knee in maximum hyperextension by resting the heel on a Mayo stand. Place an impingement rod between the sutures attached to the tendons and instruct an assistant to tension the graft in line with the tibial tunnel by pulling on the rod (Figure 27).

Rotate the WasherLoc Device so that the flat edge faces the distal end of the tibial tunnel (Figure 28).

# Transtibial ACL Reconstruction with the Anatomy Specific Tibial Guide, EZLoc Femoral Fixation, and WasherLoc Tibial Fixation

## Surgical Technique



Figure 29

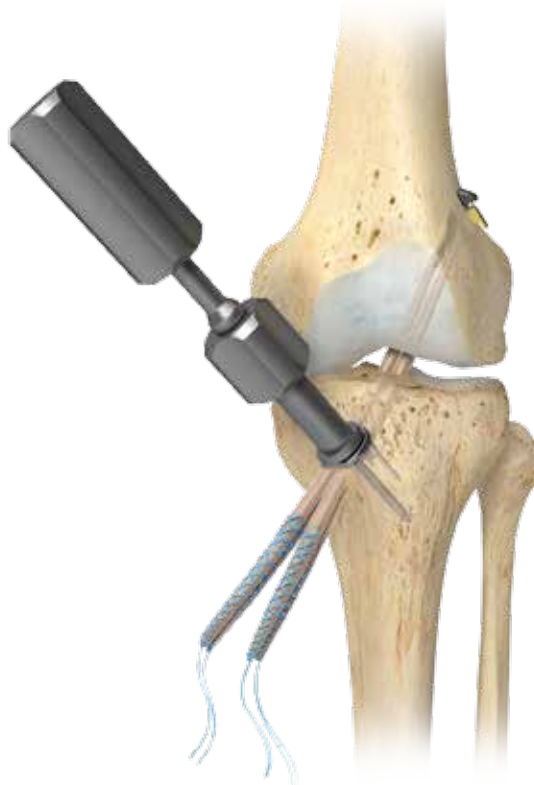

Figure 30

### Tension the Graft and Impact the WasherLoc Device (cont.)

Place the tip of the awl between the limbs of each tendon and use a right-angle clamp to maneuver the graft under the WasherLoc Device so that all four bundles are contained within the four longer extended spikes (Figure 29).

Aim the awl towards the fibula to avoid posterior neurovascular structures and impact the WasherLoc Device (Figure 30).

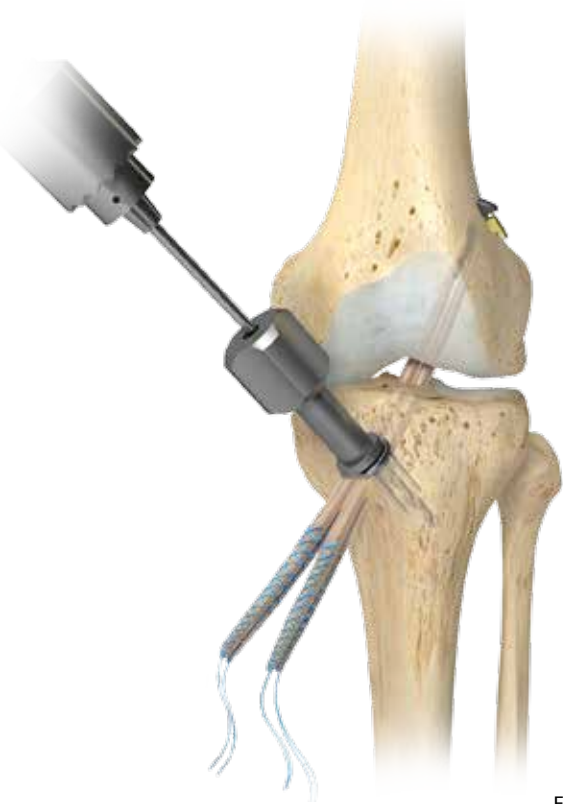

Figure 31

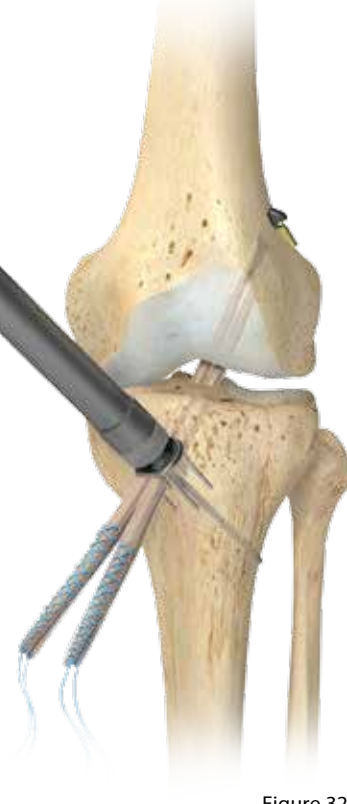

Figure 32

## Drill, Measure and Insert the Cancellous Compression Screw

Maintain tension on the graft and unscrew and remove the awl from the drill guide. Insert a 3.2 mm drill bit through the drill guide and push the cutting tip past the tendons (Figure 31).

Protect the neurovascular structures by carefully drilling toward the fibula and through the **lateral** tibial cortex. **Do not plunge the tip of the drill into the soft tissues.** Unscrew the drill guide, insert the depth gauge, and measure the length of the tunnel (Figure 32).

# Transtibial ACL Reconstruction with the Anatomy Specific Tibial Guide, EZLoc Femoral Fixation, and WasherLoc Tibial Fixation

## Surgical Technique

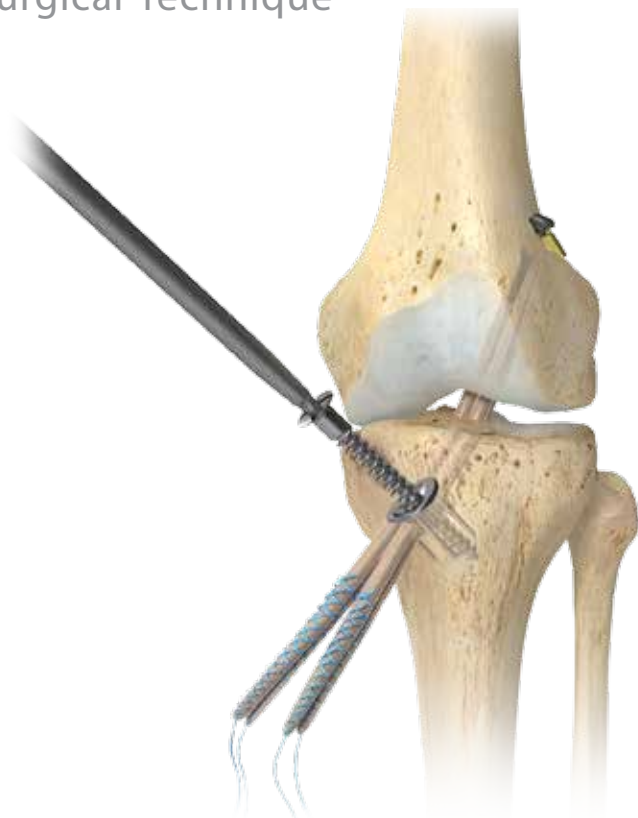

Figure 33

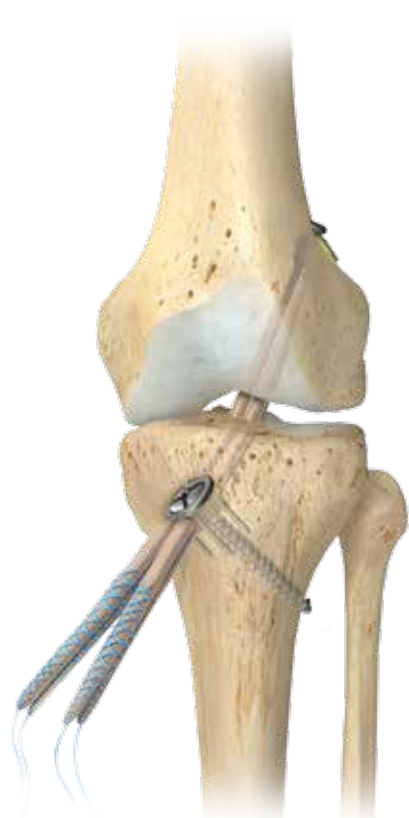

Figure 34

### Drill, Measure and Insert the Cancellous Compression Screw (cont.)

Leave the depth gauge in place and adjust the overhead light until the depth gauge casts a shadow on the thigh. Mark the long axis of the shadow on the skin and screw the appropriate length self-tapping cancellous compression screw into the tibia. Keep the shadow of the shaft of the screwdriver in line with the marking of the long axis of the depth gauge while advancing the compression screw (Figures 33 and 34).

## Ordering Information

PART NUMBER	SIZE	DESCRIPTION
909601	-	Anatomy Specific Tibial Guide
909602	5 pk	Sharp Drill Guide Bullet-Calibrated (for Anatomy Specific Guide)
909507	-	Anatomy Specific Tibial Guide Coronal Alignment Pin
909871	15°	Angled Osteotome
909873	-	Curved Roofplasty Gouge
909827	2.4 mm	Drill Point K-Wire
909911	7 mm	Cannulated Fully Fluted Drill Bit
909913	8 mm	
909915	9 mm	
909917	10 mm	
909919	11 mm	
909921	12 mm	
909931	7 mm	Impingement Rod
909933	8 mm	
909935	9 mm	
909937	10 mm	
909939	11 mm	
909941	12 mm	
909811	7 mm	EZLoc Sizing Sleeve/Skin Protector
909813	8 mm	
909815	9 mm	
909817	10 mm	
909819	11 mm	
909821	12 mm	
909617	7 mm	Acorn Reamer Cannulated
909618	8 mm	
909619	9 mm	
909620	10 mm	
909621	11 mm	
909622	12 mm	
909623	-	Femoral Aimer Handle
909627-03	-	Femoral Aimer Replacement Ring Nut
909640	3/32"	Guide Pin/Graft Passing Pin
906988	60°	Curette

# Transtibial ACL Reconstruction with the Anatomy Specific Tibial Guide, EZLoc Femoral Fixation, and WasherLoc Tibial Fixation

## Ordering Information

PART NUMBER	SIZE	DESCRIPTION
909627	7 mm	Femoral Aimer Tip with Ring Nut
909628	8 mm	
909629	9 mm	
909630	10 mm	
909631	11 mm	
909632	12 mm	
904788	7–8 mm Short (used in tunnels <35 mm)	EZLoc Femoral Fixation Device
904789	9–10 mm Short (used in tunnels <25 mm)	
904780	7–8 mm Standard (used in tunnels 35–50 mm)	
904781	9–10 mm Standard (used in tunnels 35–50 mm)	
904784	7–8 Long (used in tunnels >50 mm)	
904785	9–10 Long (used in tunnels >50 mm)	
904761	-	EZLoc Depth Probe
904762	7–8 mm	EZLoc Sizing Stick
904763	9–10 mm	
904764	-	EZLoc Etched Guide Wire
904767	7 mm x 1"	End Cutting Reamer
904768	8 mm x 1"	
904769	9 mm x 1"	
904770	10 mm x 1"	
909836	-	EZLoc/WasherLoc Disposable Kit
900737	7 mm	Disposable Bone Dowel Harvest Tube
900738	8 mm	
900739	9 mm	
900740	10 mm	
900741	11 mm	
908469	16 mm	WasherLoc Tibial Fixation Device - Extended Spike
908468	18 mm	



---

## Ordering Information

PART NUMBER	SIZE	DESCRIPTION
908630	4.5 x 30 mm	WasherLoc Cortical Screw
908632	4.5 x 32 mm	
908634	4.5 x 34 mm	
908636	4.5 x 36 mm	
908638	4.5 x 38 mm	
908640	4.5 x 40 mm	
908642	4.5 x 42 mm	
908644	4.5 x 44 mm	
908646	4.5 x 46 mm	
908648	4.5 x 48 mm	
908650	4.5 x 50 mm	
908652	4.5 x 52 mm	
908654	4.5 x 54 mm	
908656	4.5 x 56 mm	
908658	4.5 x 58 mm	
908660	4.5 x 60 mm	
908824	6 x 24 mm	WasherLoc Cancellous Screw
908826	6 x 26 mm	
908828	6 x 28 mm	
908830	6 x 30 mm	
908832	6 x 32 mm	
908834	6 x 34 mm	
908836	6 x 36 mm	
908838	6 x 38 mm	
908840	6 x 40 mm	
908842	6 x 42 mm	
908844	6 x 44 mm	
908846	6 x 46 mm	
908848	6 x 48 mm	
908850	6 x 50 mm	
908852	6 x 52 mm	
908854	6 x 54 mm	
908856	6 x 56 mm	
908858	6 x 58 mm	
908860	6 x 60 mm	

## EZLOC FEMORAL FIXATION DEVICE

### INDICATIONS

Toggle anchors (i.e., ToggleLoc, ToggleLoc buttons and EZLoc) are indicated for use for fixation of tendons and ligaments during orthopedic reconstruction procedures such as Anterior Cruciate Ligament (ACL) reconstruction.

### CONTRAINDICATIONS

1. Infection.
2. Patient conditions including blood supply limitations, and insufficient quantity or quality of bone or soft tissue.
3. Patients with mental or neurologic conditions who are unwilling or incapable of following postoperative care instructions.
4. Foreign body sensitivity. Where material sensitivity is suspected or unknown, testing is to be completed prior to implantation of the device.

## WASHERLOC TIBIAL FIXATION DEVICE

### INDICATIONS

Soft tissue fixation to bone, specifically during ligament reconstructive procedures.

### CONTRAINDICATIONS

1. Infection.
2. Patient conditions including blood supply limitations, and insufficient quantity or quality of bone or soft tissue.
3. Patients with mental or neurologic conditions who are unwilling or incapable of following postoperative care instructions.
4. Foreign body sensitivity. Where material sensitivity is suspected or unknown, testing is to be completed prior to implantation of the device.

## References

1. Simmons, R.; Howell, S. M.; and Hull, M. L.: Effect of the angle of the femoral and tibial tunnels in the coronal plane and incremental excision of the posterior cruciate ligament on tension of an anterior cruciate ligament graft: an in vitro study. *J Bone Joint Surg Am*, 85-A(6): 1018-29, 2003.
2. Smith, C. K.; Howell, S. M.; and Hull, M. L.: Anterior laxity, slippage, and recovery of function in the first year after tibialis allograft anterior cruciate ligament reconstruction. *Am J Sports Med*, 39(1): 78-88, 2011.
3. Wallace, M. P.; Hull, M. L.; and Howell, S. M.: Can an isometer predict the tensile behavior of a double-looped hamstring graft during anterior cruciate ligament reconstruction? *J Orthop Res*, 16(3): 386-93, 1998.
4. Zavras, T. D.; Race, A.; and Amis, A. A.: The effect of femoral attachment location on anterior cruciate ligament reconstruction: graft tension patterns and restoration of normal anterior-posterior laxity patterns. *Knee Surg Sports Traumatol Arthrosc*, 13(2): 92-100, 2005.
5. Sasaki, K. et al.: Enhancement of tendon-bone osteointegration of anterior cruciate ligament graft using granulocyte colony-stimulating factor. *Am J Sports Med*, 36(8): 1519-27, 2008.
6. Markolf, K. L.; Park, S.; Jackson, S. R.; and McAllister, D. R.: Anterior-posterior and rotatory stability of single and double-bundle anterior cruciate ligament reconstructions. *J Bone Joint Surg Am*, 91(1): 107-18, 2009.
7. Howell, S. M.; Gittins, M. E.; Gottlieb, J. E.; Traina, S. M.; and Zoellner, T. M.: The relationship between the angle of the tibial tunnel in the coronal plane and loss of flexion and anterior laxity after anterior cruciate ligament reconstruction. *Am J Sports Med*, 29(5): 567-74, 2001.
8. Howell, S. M., and Barad, S. J.: Knee extension and its relationship to the slope of the intercondylar roof. Implications for positioning the tibial tunnel in anterior cruciate ligament reconstructions. *Am J Sports Med*, 23(3): 288-94, 1995.
9. Howell, S. M.; Clark, J. A.; and Farley, T. E.: A rationale for predicting anterior cruciate graft impingement by the intercondylar roof. A magnetic resonance imaging study. *Am J Sports Med*, 19(3): 276-82, 1991.
10. Howell, S. M., and Lawhorn, K. W.: Gravity reduces the tibia when using a tibial guide that targets the intercondylar roof. *Am J Sports Med*, 32(7): 1702-10, 2004.
11. Howell, S. M., and Taylor, M. A.: Failure of reconstruction of the anterior cruciate ligament due to impingement by the intercondylar roof. *J Bone Joint Surg Am*, 75(7): 1044-55, 1993.
12. Scanlan, S. F.; Blazek, K.; Chaudhari, A. M.; Safran, M. R.; and Andriacchi, T. P.: Graft orientation influences the knee flexion moment during walking in patients with anterior cruciate ligament reconstruction. *Am J Sports Med*, 2009.
13. Berns, G. S., and Howell, S. M.: The effect of roofplasty and tibial hole placement on impingement of anterior cruciate ligament reconstructions. *Journal of Biomechanics*, 25(6): 653, 1992.
14. Goss, B. C.; Hull, M. L.; and Howell, S. M.: Contact pressure and tension in anterior cruciate ligament grafts subjected to roof impingement during passive extension. *J Orthop Res*, 15(2): 263-8, 1997.
15. Howell, S. M.: Arthroscopic roofplasty: a method for correcting an extension deficit caused by roof impingement of an anterior cruciate ligament graft. *Arthroscopy*, 8(3): 375-9, 1992.
16. Howell, S. M.; Berns, G. S.; and Farley, T. E.: Unimpinged and impinged anterior cruciate ligament grafts: MR signal intensity measurements. *Radiology*, 179(3): 639-43, 1991.
17. Howell, S. M.; Clark, J. A.; and Blasler, R. D.: Serial magnetic resonance imaging of hamstring anterior cruciate ligament autografts during the first year of implantation. A preliminary study. *Am J Sports Med*, 19(1): 42-7, 1991.
18. Howell, S. M.; Clark, J. A.; and Farley, T. E.: Serial magnetic resonance study assessing the effects of impingement on the MR image of the patellar tendon graft. *Arthroscopy*, 8(3): 350-8, 1992.
19. Howell, S. M., and Hull, M. L.: Checkpoints for judging tunnel and anterior cruciate ligament graft placement. *J Knee Surg*, 22(2): 161-70, 2009.
20. Howell, S. M., and Lawhorn, K. W.: Gravity reduces the tibia when using a tibial guide that targets the intercondylar roof. *American Journal of Sports Medicine*, 32(7): 1702-10, 2004.
21. Karchin, A.; Hull, M. L.; and Howell, S. M.: Initial tension and anterior load-displacement behavior of high-stiffness anterior cruciate ligament graft constructs. *J Bone Joint Surg Am*, 86-A(8): 1675-83, 2004.
22. Smith, C. K.; Hull, M. L.; and Howell, S. M.: Does graft construct lengthening at the fixations cause an increase in anterior laxity following anterior cruciate ligament reconstruction in vivo? *J Biomech Eng*, 132(8): 081001, 2010.
23. Graf, B. K.; Henry, J.; Rothenberg, M.; and Vanderby, R.: Anterior cruciate ligament reconstruction with patellar tendon. An ex vivo study of wear-related damage and failure at the femoral tunnel. *Am J Sports Med*, 22(1): 131-5, 1994.
24. Katsuragi, R.; Yasuda, K.; Tsujino, J.; Keira, M.; and Kaneda, K.: The effect of nonphysiologically high initial tension on the mechanical properties of in situ frozen anterior cruciate ligament in a canine model. *Am J Sports Med*, 28(1): 47-56, 2000.
25. Gertel, T. H.; Lew, W. D.; Lewis, J. L.; Stewart, N. J.; and Hunter, R. E.: Effect of anterior cruciate ligament graft tensioning direction, magnitude, and flexion angle on knee biomechanics. *Am J Sports Med*, 21(4): 572-81, 1993.
26. Wallace, M. P.; Howell, S. M.; and Hull, M. L.: In vivo tensile behavior of a four bundle hamstring graft as a replacement for the anterior cruciate ligament. *Journal of Orthopedic Research*, 15(4): 539-545, 1997.

This material is intended for health care professionals and the Biomet sales force only. Distribution to any other recipient is prohibited. All content herein is protected by copyright, trademarks and other intellectual property rights owned by or licensed to Biomet Inc. or its affiliates unless otherwise indicated. This material must not be redistributed, duplicated or disclosed, in whole or in part, without the express written consent of Biomet.


Check for country product clearances and reference product specific instructions for use. For complete product information, including indications, contraindications, warnings, precautions, and potential adverse effects, see the package insert, [www.Biomet.com](http://www.Biomet.com), or contact your local Biomet Representative.

This technique was prepared in conjunction with a licensed health care professional. Biomet does not practice medicine and does not recommend any particular orthopedic implant or surgical technique for use on a specific patient. The surgeon is responsible for determining the appropriate device(s) and technique(s) for each individual patient.

Not for distribution in France.

CE mark on surgical technique is not valid unless there is a CE mark on the product label.



 **Legal Manufacturer**  
Biomet Sports Medicine  
56 East Bell Drive  
P.O. Box 587  
Warsaw, Indiana 46581  
USA

 **Authorised Representative**  
Biomet UK Ltd.  
Waterton Industrial Estate  
Bridgend, South Wales  
CF31 3XA  
UK

**CE0086**